

PATENT VITELLO-INTESTINAL DUCT WITH A PATENT URACHUS : CASE REPORT

ABSTRACT:

INTRODUCTION:

A variety of anomalies occur when vitello-intestinal duct (VID) obliteration fails. These type of anomalies occur in 2% of population and can remain asymptomatic or can incidentally present as complications intraabdominally. Vitellointestinal duct complete patency is the rarest of VID anomalies.

CASE PRESENTATION:

8 day old male presented with septicemia ,abdominal distension ,not passing stool since 1day and stool leaking from abdominal stump.

CONCLUSION:

A granulomatous umbilical lesion is a differential diagnosis of Patent VID.

KEY WORDS:

Granuloma; intestinal duct; vitello-intestinal duct.

INTRODUCTION:

Newborns,infants present with moist umbilicus,can be associated with a simple granuloma to a persistent urachus. Umbilical discharge is one of the common presentation and umbilical granuloma is a commonest DD for the same. Umbilical granuloma is the granulation tissue which is yet to be epithelised. It appears reddish pink in colour and there is very minimal bleed when irritated by trauma.75% Silver Nitrate cauterisation is used to treat them. If granuloma does not respond to cauterisation, alternative diagnosis should be taken into consideration. Umbilical granulomas are treated by a chemical or an electric cauterisation. Parents notice this abnormality as a reddish pink mass around the umbilicus or persistent discharge which is serous in nature around the umbilicus. When the lesion is not responding to this treatment, then alternate diagnosis must be investigated. Patent vitello-intestinal duct (VID) is one of the alternate diagnosis which should be ruled out to avoid catastrophe. In 2% of cases, persistent VID gives rise to many congenital anomalies like sinuses,cysts, diverticulum,band and fistula. Most commonlyVID anomalies presents as Meckel's diverticulum,Vitellineligament,Vitelline cyst and Umbilical Sinus represents an incomplete obliteration of theVID.Complete failure of theobliteration of the VI duct results in patent VID. Enterocutaneous fistula between our distal small intestine and our umbilicus can be produced when the duct remains patent in it's whole course . When there is a fistulous communication with patent VID,persistent serous, bilious or a feculent discharge are identified at patient's umbilicus. Treatment of the patent VID is surgical excision of VI duct, with or without small bowel segment, to obliterate this connection. Then umbilical reconstruction is performed.

CASE PRESENTATION:

A 8 day old male child presented with septicemia, abdominal distension, not passing stool since 1day and stool leaking from abdominal stump. The child was full term (38 week) with birth weight of 2.15kg, clear liquor/NVD, and no maternal morbidity.

The child had history of lethargy on day 2 of life.

The child had passed stool on 1st and 2nd day of life and not passed stool then after
On day 15 of life pt has protrusion of bowel through the umbilical stump.

CLINICAL FINDINGS:

His vitals were

Heart rate:138/min,RR:68/min,Temperature:36.5c,Spo2:86% on RA and 93% on O2 by nasal prong

Local Examination: PA: soft ,distended pinkish umbilical mass+ with greenish discharge from umbilical stump.

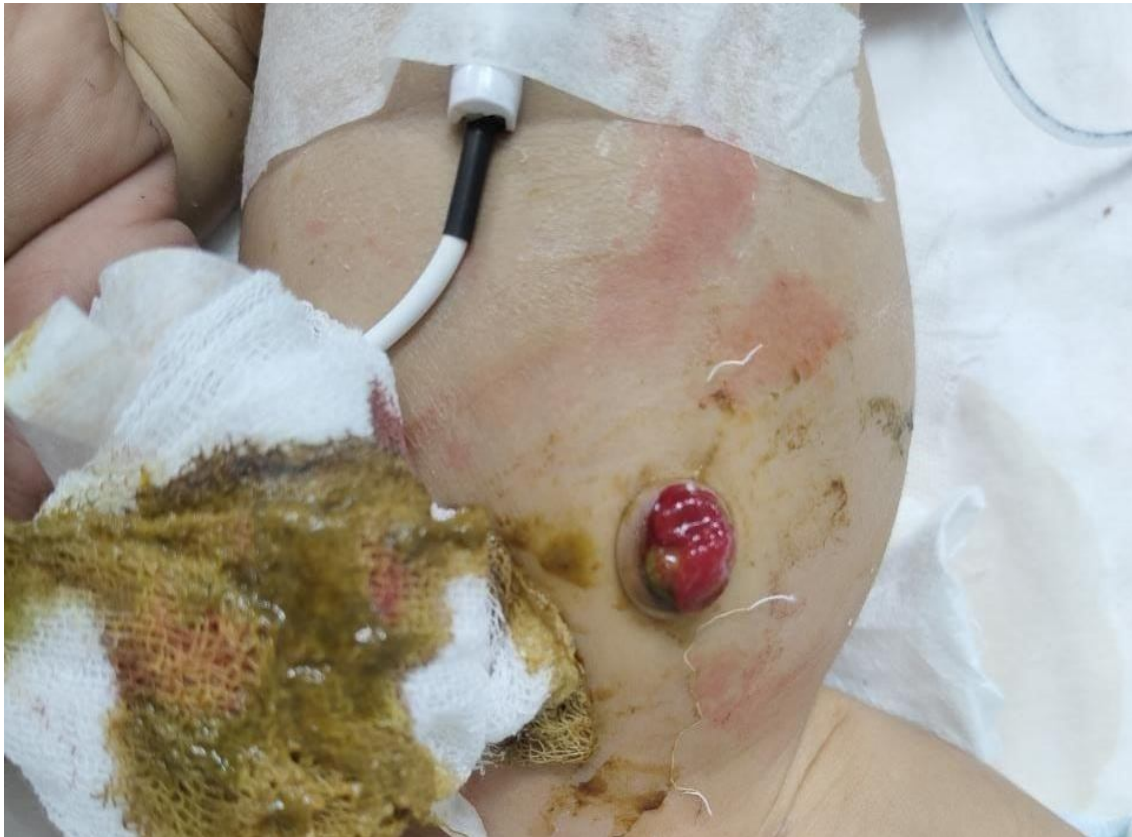

Fig. 1. soft ,distended pinkish umbilical mass with greenish discharge from umbilical stump.

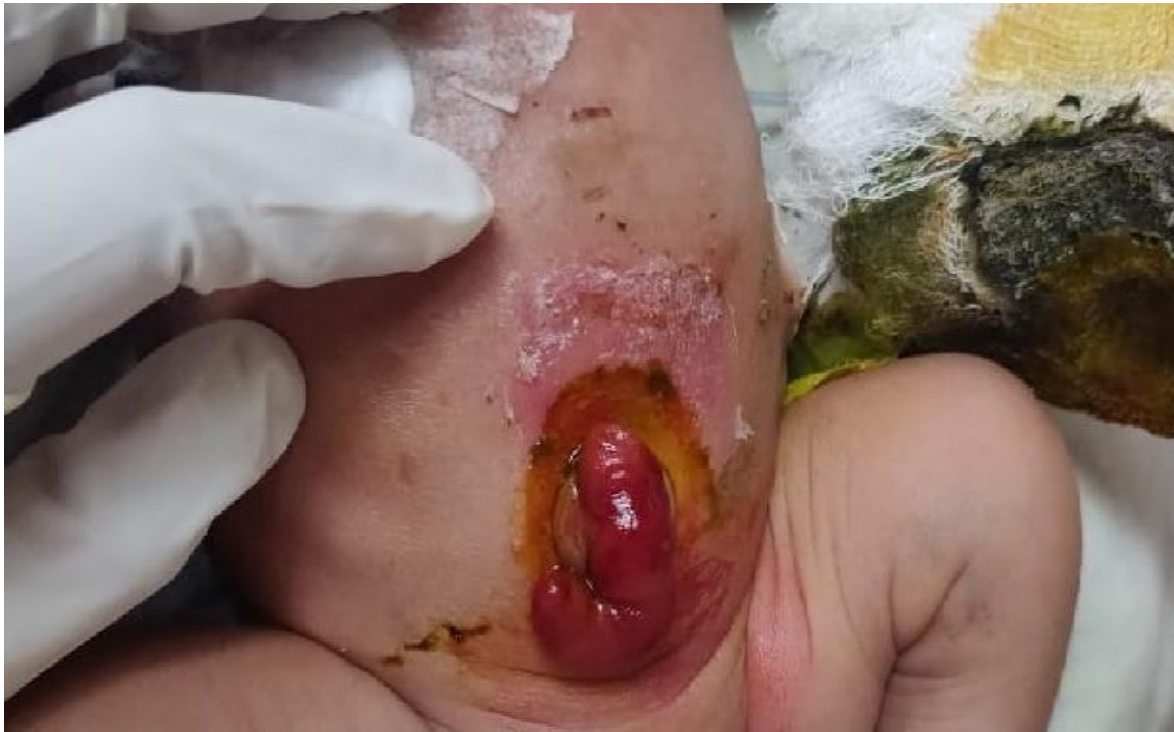

Fig.2 Operative condition

INVESTIGATIONS:

Basic routine blood investigations including the total WBC count, Haemoglobin, serum creatinine and bilirubin were done

Hb:15.2	Na+:133
TC:14800	K+: 4.5
PLC:21000	Urea:79
PT:13	Creat:1.04
INR:1.03	CRP:140

X-Ray Chest AP view:

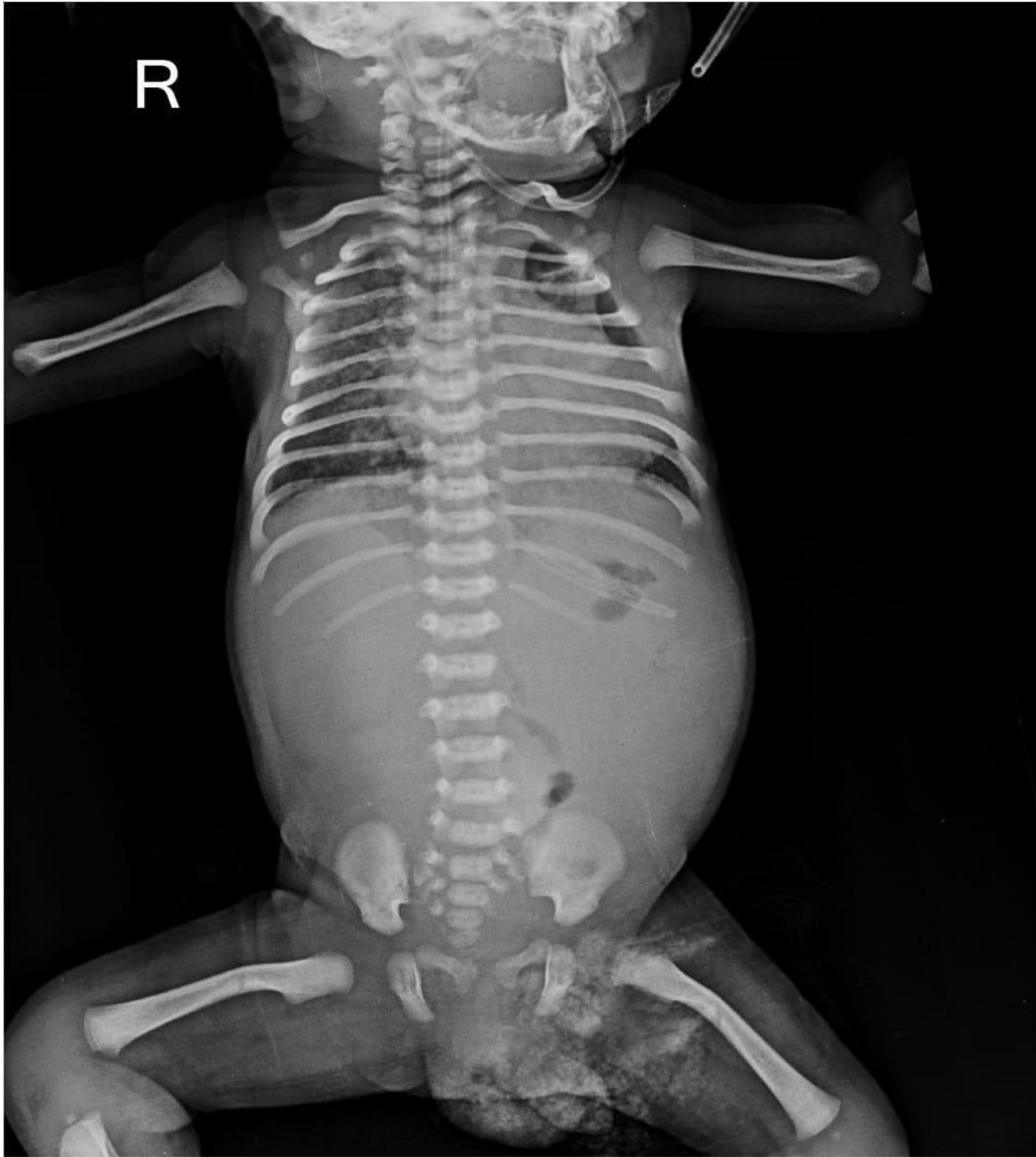

Fig. 3. X-Ray Chest AP view

USG Abdo Pelvis:

Absent Left kidney and mild free fluid in inter-bowel space.

THERAPEUTIC INTERVENTION:

Initially the patient was treated for septicemia with Injectable Antibiotics.

Operative intervention was postponed due to low platelet count and altered coagulation profile.

After multiple Platelets, FFP, PCV transfusions the pt's platelet count and coagulation profile has normalised and the patient was taken for surgery.
An Emergency Exploratory Laparotomy with resection of Vitello-Intestinal Duct with ileoileal anastomosis was done.
A patent urachus was also found and repaired.

Fig. 4. Laparotomy with resection of Vitello-Intestinal Duct with ileo ileal anastomosis

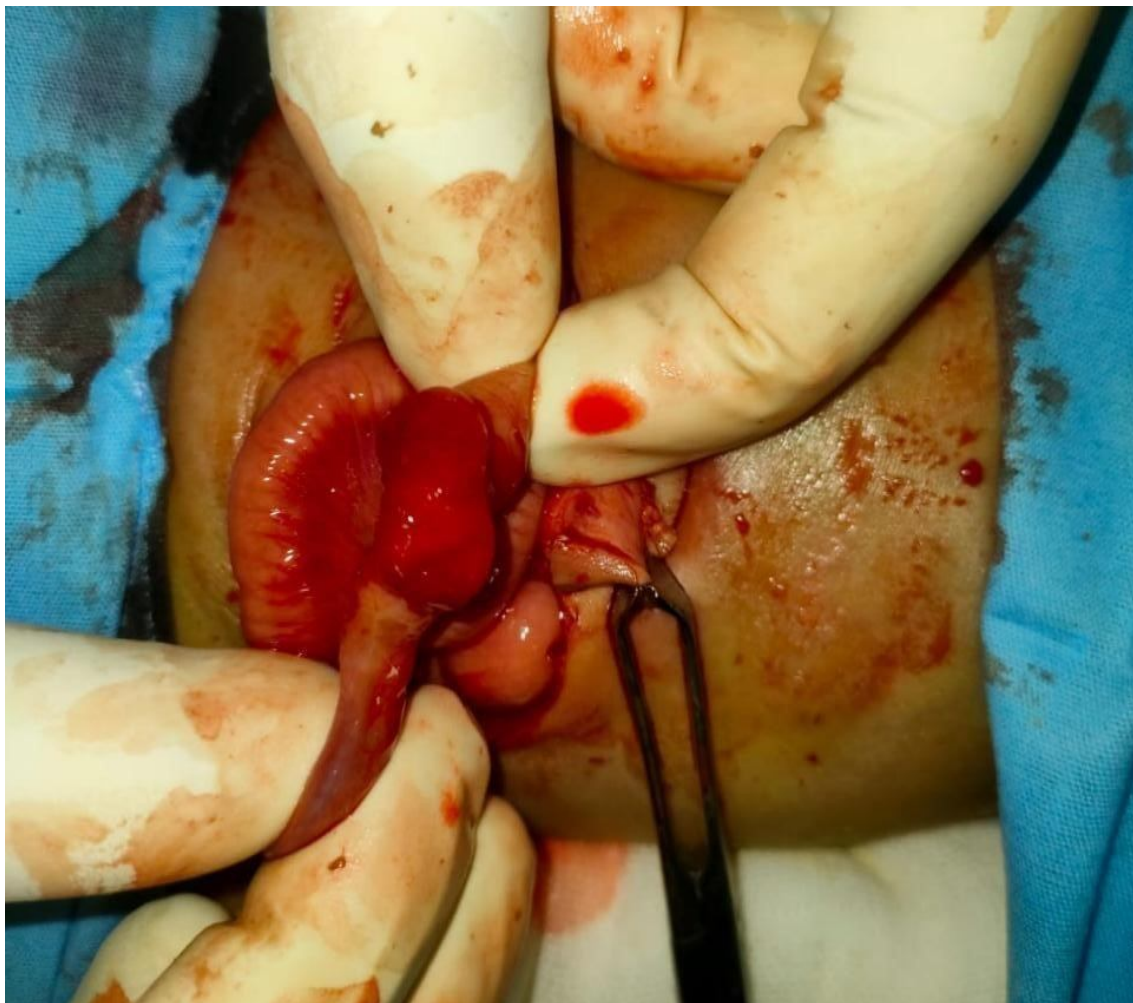

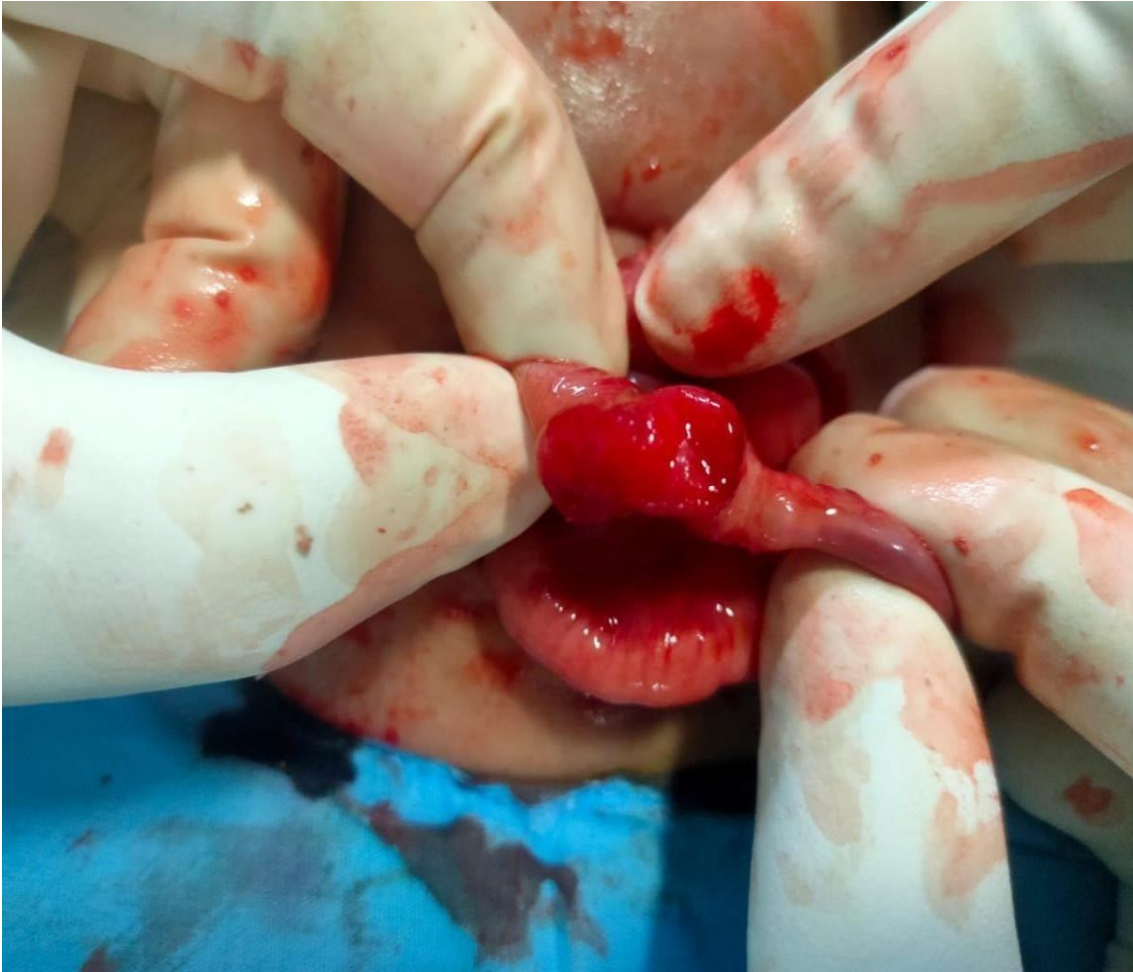


Fig. 5 A patent urachus

FOLLOWUP AND OUTCOME:

No wound discharge/dehiscence/seroma formation or any other immediate post-operative complications were noted and patient was discharged on post operative day 5.

DISCUSSION:

Communication existing between embryonic gut and yolk sac, narrows down to a tube called the VIDuct at around 3rd week of the embryonic life, also known as omphalo-mesenteric duct (OMD). This generally obliterates by the end of 7th week. Complete failure of obliteration of this duct results in Patent Vitello Intestinal Duct. This patent duct in its course throughout produces enterocutaneous fistula between patient's distal small intestine and patient's umbilicus. Of the VID anomalies seen among neonates or infants, it is rarest with the incidence of 0.0064– 0.066%.

Exact etiological factor for this incomplete obliteration isn't known. A patent VIDuct may be presented as continuous discharge producing umbilical sinus/polyp/umbilical nodule. If there is a persistent discharge which is yellowish in colour or bilious, then there can be cellulitis, which might progress to a necrotising fasciitis or even sepsis.

Umbilical granulomas being benign lesions to which patent VID resembles. Granulomas need surgical removal rarely. If patent VIDuct is suspected, Ultrasonography can be used for diagnosis by identifying VI Duct relationship and VI Duct's continuity with patient's umbilicus and bladder, this also helps in the prevention of surgical exploration unnecessarily and may also be a guide for further management. The clinical diagnosis is made simple when we can see a fecal discharge. To confirm the diagnosis a fistulogram through the VID can be done. Early resection surgically is recommended in patent VI Duct management. The complications include a protruded intestinal mucosal bleed, omphalitis, prolapse and intestinal strangulation and malignancy. Surgery involves laparotomy by a transverse infra-umbilical incision/transverse supra-umbilical incision/wide elliptical incision/vertical or laterally extended incision and resection of the connection to the intestine.

CONCLUSION:

Patent VIDuct should be in consideration in differential diagnosis of a patient who presents with a granulomatous lesion over the umbilicus. There's a good response to silver nitrate in case of Umbilical granuloma but when there is no response to silver nitrate therapy consider other anomalies. So a careful examination of the umbilicus must and should be done before initiating treatment. In view of cosmesis in a post op case Trans-umbilically resecting the patent VID and an umbilicoplasty gives an outstanding result.

CONSENT:

Consent has been taken from the patient's parents.

Ethical Approval:

As per international standard or university standard written ethical approval has been collected and preserved by the author(s).

CONFLICT OF INTEREST:

There are no conflict of interests to be declared.

FUNDING:

None.

AUTHOR'S CONTRIBUTION :

All authors contributed equally in treatment, management and follow-up of the patient and in compilation of the case report.

REFERENCES:

1. Agrawal S, Menon A. Patent vitellointestinal duct. *BMJ Case Rep.* 2010. DOI:10.1136/bcr.12.2009.2594
2. Zafer Y, Yigit S, Turken A. Patent omphalomesenteric duct. *Turk J Med Sci.* 2000; 30:83–85.
3. Rao PL, Mitra SK, Pathak IC. Patent vitello intestinal duct. *Indian J Pediatr.* 1979;46:215. DOI:10.1007/ BF02898231.
4. Frolov P, Alali J, Klein MD. Clinical risk factors for gastroschisis and omphalocele in humans: a review of the literature. *PediatrSurg Int.* 2010;26:1135-48. DOI: 10.1007/s00383-010-2701-7
5. Piparsaliya S, Joshi M, Rajput N. Patent vitellointestinal duct: A close differential diagnosis of umbilical granuloma: A case re- port and review of literature. *Surgical Science.* 2011;2:134-6. DOI: 10.4236/ss.2011.23027
6. Khati NJ, Enquist EG, Javitt MC. Imaging of the umbilicus and periumbilical region. *Radiographics.* 1998; 18:413-31. DOI: 10.1148/radiographics.18.2.9536487
7. Maxwell D, Hariri N, Coleman KC. A case report of a patent omphalomesenteric duct presenting with meconium discharge from the umbilicus. *Ann Clin Case Rep.* 2016;1:2016;1022.
8. Zea MI, Chana RS, Anees A. Inverted ileal prolapse through patent vitellointestinal duct: a case report. *Internet J PediatrNeonatal.* 2009;10:2. DOI: <https://doi.org/10.5580/28dc>
9. Hasegawa T, Sakurai T, Monta O, Tazuke Y, Ueda S, Iwasaki Y, et al. Transumbilical resection and umbilical plasty for patent omphalomesenteric duct. *PediatrSurg Int.* 1998;13:180-1. DOI: <https://doi.org/10.1007/s003830050282> 10. Lassen PM, Harris MJ, Kearsse WS, Argueso LR. Laparoscopic management of incidentally noted omphalomesenteric mesenteric duct remnant. *J Endour.* 8:49-51. DOI: 10.1089/end.1994.8.49.