

Case study

Birdshot Chorioretinopathy: A case report

Abstract

Birdshot chorioretinopathy is a well-known yet poorly studied form of posterior uveitis characterized by multiple, distinct, hypopigmented choroidal lesions and strongly associated with human leukocyte antigen (HLA)-A29. We report the case of a 54-year-old woman with no particular pathologic history who was admitted 3 weeks ago for visual acuity decrease with floaters in both eyes. Ophthalmologic examination revealed visual acuity of 6/10 on the right and 4/10 on the left, bilateral hyalitis without signs of anterior uveitis, which was confirmed by further examination and especially by fluorescein angiography showing bilateral papilledema and signs of vasculitis with intertwining of the vascular axes and diffusion in the late phase. Optical coherence tomography (OCT) showed cystoid macular edema in the left eye. Biological tests such as serologies (toxoplasmosis, syphilis, cytomegalovirus), tuberculosis tests, angiotensin converting enzyme, HLA B27, B51, which are all normal. Cerebro-orbital MRI was normal. Depending on the retinal lesions and angiographic aspect, HLA A29 was requested with positive results. Considering this finding, bilateral disease, fluorescein angiography images, and positive result of HLA A29, the diagnosis of Birdshot chorioretinopathy was confirmed. The patient was treated with immunosuppressants and systemic corticosteroids.

Keywords: birdshot chorioretinopathy, fluorescein angiography, corticosteroids, HLA A29, retinal vasculitis, choroidal lesions.

Introduction

Birdshot retinochoroidopathy (BRC) is a chronic bilateral posterior uveitis characterized by the presence of multiple hypopigmented spots on the fundus, reminiscent of the eye resembling lead shot. This rare disease, which was distinguished from the other causes of uveitis in 1980, represents 0.6% to 1.5% of all uveitis cases and 6% to 7.9% of posterior uveitis cases, but it can also occur unilaterally. We report a case of Birdshot retinochoroidopathy in a 54-year-old woman.

Case report

A 54-year-old woman with no particular pathologic history was admitted 3 weeks ago for visual acuity decrease with floaters in both eyes. Ophthalmologic examination revealed visual acuity of 6/10 on the right and 4/10 on the left, bilateral hyalitis without signs of anterior uveitis, and examination of the posterior segment revealed bilateral papilledema with yellowish oval spots (Figure 1), which was confirmed by further examination and, in particular, fluorescein angiography, which revealed bilateral papilledema and signs of vasculitis with intertwining of the vascular axes and diffusion in the late phase. Optical coherence tomography (OCT) showed cystoid macular edema in the left eye (Figure 2). Biological tests such as serologies (toxoplasmosis, syphilis, cytomegalovirus), tuberculosis tests, angiotensin converting enzyme, HLA B27, B51, which are all normal. Cerebro-orbital MRI was normal. Depending on the retinal lesions and angiographic aspect, HLA A29 was requested with positive results. Considering this finding, bilateral disease, fluorescein angiography images, and positive result of HLA A29, the diagnosis of Birdshot

Comment [pr1]: Use snellen or logmar visual acuity notation

chorioretinopathy was confirmed. The patient was treated with immunosuppressants and systemic corticosteroids.

Comment [pr2]: Specify the type of immunosuppressant used in this patient

Comment [pr3]: How did the patient respond to treatment?

Discussion

Birdshot retinochoroidopathy is an autoimmune disease of the posterior uvea that results in inflammation of the retina, choroid, and adjacent tissues: Optic nerve, retinal vessels and vitreous. [1]. The very strong association of HLA-A29 (especially the subtype HLA-A2902) with BCR was first described by Nussenblatt in 1982 [2]. More recent studies have confirmed that this is a true association and that the HLA-A29 gene itself plays a central role in the pathogenesis of the disease [3, 4]. Other HLA phenotypes have also been associated with the development of the disease: HLA-B12, B44, and B45 [5]. Analysis of vitreous samples from patients has shown the presence of autoreactive CD4+ and CD8+ T cells with a Th1 [6] or Th17 profile [7], providing a strong argument for the autoimmune origin of the disease. The average age at onset of the disease is 50 years [5]. A slight predominance of females is observed (54.1%) [5]. BRC is a rarity in pediatrics [8]. Overall, 92.3% of patients had visual complaints, although central visual acuity was preserved [5]. The main complaint was blurred vision in 83.3% of cases, followed by myodesopsia in 40% of cases [5]. Other symptoms could be reported independently of a decrease in visual acuity: Night blindness, photopsia, photophobia, loss of peripheral vision, fluctuant vision, loss of depth of field or relief vision, and metamorphopsia [5]. Interestingly, these symptoms may precede the characteristic ocular fundus lesions by several years, indicating their importance in the diagnostic armamentarium [9]. Ophthalmologic examination in the typical form of this disease is classically devoid of retrocorneal precipitates [5]. However, a Swiss study [10] suggested that the presence of retrocorneal precipitates should be removed from the exclusion criteria because 3 cases of BRC with retrocorneal precipitates with a granulomatous appearance were reported [10]. Posterior synechiae are usually not present [11]. Fundus lesions are the most important signs. They must be present in both eyes and have the features described by the consensus conference [11]. They can occur up to several years after the onset of the first symptoms [9]. Vitreous inflammation is classically always present. However, there is no anti-egg or ice pack appearance [5, 12]. Papilledema or the presence of papillary hyperfluorescence on fluorescein angiography are not uncommon. Retinal hemorrhages, posterior pole periphlebitis, and, less commonly, narrowing of the retinal arterioles may also occur [13]. Vasculitis may also affect the peri-macular capillaries, resulting in vascular leakage and classic cystoid macular edema [13]. The website OCT is critical for initial evaluation, follow-up evaluation and for assessing response to treatment, as in most cases the decrease in visual acuity is due to the presence or exacerbation of macular edema. Macular edema is thought to occur in early forms of the disease, while macular atrophy, which mainly affects the outer layers of the retina [14], is a poor prognostic factor for later forms [15]. The EOG (electrooculography) and ERG (electroretinography) are altered and the curves are attenuated. These examinations can help to distinguish Birdshot from other pathologies that produce a similar picture of the ocular fundus [14]. The natural history may lead to spontaneous recovery after several relapses. This disease consists of a series of inflammatory phases and phases of improvement that alternate. When inflammation is severe and/or vision declines, often due to macular edema, corticosteroid treatment is given, although the significant side effects are sometimes of great concern [16]. In case of failure, ciclosporin A is used, a very effective but renal toxic drug that requires careful monitoring of renal function and blood pressure [16,17]. Currently, there is no consensus on the modalities of monitoring. The lack of codified rules concerns not only the type of examinations to be performed but also their frequency. Several clinical and paraclinical methods have been proposed, but none has been validated by a prospective study. Rather than a single component, surveillance for CRB should be based on a combination of clinical and paraclinical investigations, and the frequency of surveillance should be tailored to

the stage and severity of the disease. Clinical criteria for monitoring include functional signs such as quality of life scale, visual acuity, vitreous inflammation, macular edema, and fundus blotches [5]. However, these criteria may develop independently, so one alone is not sufficient to provide a comprehensive overview. Of the complementary examinations, some provide information about inflammatory activity: OCT evaluates the presence of macular edema, and fluorescein angiography can reveal vasculitis, vascular leakage, or choroidal neovascularization [12]. ICG (indocyanine green angiography) could be used, but no study has been performed in this sense. Fardeau et al. suggested that hypocyanotic stains on ICG might disappear with treatments [18].

Conclusion

Birdshot retinochoroidopathy is a potentially blinding eye disease for which there is no codified treatment or follow-up. Visual acuity is a poor monitor. Comparison of clinical and paraclinical elements over time allows better assessment of the form and evolution of the disease. Prolonged anti-inflammatory treatment should be considered if there is evidence of a poor prognosis.

Declarations

Ethics approval and consent to participate

The authors declare that there is no conflict of interest that could be perceived as prejudicing the impartiality of this review.

Consent for publication

All authors consent to publication

Declaration of patient consent

The authors certify that they have obtained all appropriate patient consent forms. In the form the patient has given her consent for her images and other clinical information to be reported in the journal. The patient understand that her name and initials will not be published and due efforts will be made to conceal her identity, but anonymity cannot be guaranteed.

References

1. Hollenbach JA, Thomson G, Cao K, Fernandez-Vina M, Erlich HA, Bugawan TL, et al. HLA diversity, differentiation, and haplotype evolution in Mesoamerican Natives. *Hum Immunol* 2001;62:378—90
2. Nussenblatt RB, Mittal KK, Ryan S, Green WR, Maumenee AE. Birdshot retinochoroidopathy associated with HLA-A29 antigen and immune responsiveness to retinal S-antigen. *Am J Ophthalmol*. 1982;94(2):147—58.
3. Donvito B, Monnet D, Tabary T, Delair E, Vittier M, Réveil B, Sivaradjam R, Edelson C, Philbert F, Brézin AP, Cohen JH. Different HLA class IA region complotypes for HLA-A29.2 and -A29.1 antigens, identical in birdshot retinochoroidopathy patients or healthy individuals. *Invest Ophthalmol Vis Sci*. 2005;46:3227—32.
4. Donvito B, Monnet D, Tabary T, Delair E, Vittier M, Réveil B, Chiquet C, Brézin AP, Cohen JH. A new HLA extended haplotype containing the A*2910 allele in birdshot reti-nochoroidopathy: Susceptibility narrowed to the HLA molecule itself. *Invest Ophthalmol Vis Sci*. 2010; 51: 2525-2528
5. Shah KH, Levinson RD, Yu F, Goldhardt R, Gordon LK, Gonzales CR, et al. Birdshot chorioretinopathy. *Surv Ophthalmol*2005;50:519—41.
6. Kuiper JJW, Rothova A, Schellekens PAW, Ossewaarde-van Norel A, Bloem AC, Mutis T. Detection of choroid- and retina-antigen reactive CD8(+) and CD4(+) T lymphocytes in the vitreous fluid of patients with birdshot chorioretinopathy. *Hum Immunol* 2014;75:570—7.
7. Kuiper JJW, Emmelot ME, Rothova A, Mutis T. Interleukin17 production and T helper 17 cells in peripheral blood mononuclear cells in response to ocular lysate in patients with birdshot chorioretinopathy. *Mol Vis* 2013;19:2606—14.
8. Pivetti-Pezzi P. Uveitis in children. *Eur J Ophthalmol* 1996; 6:293—8.
9. Soubrane G, Bokobza R, Coscas G. Late developing lesions in birdshot retinochoroidopathy. *Am J Ophthalmol*1990;109:204—10
10. Knecht PB, Papadia M, Herbort CP. Granulomatous keratic precipitates in birdshot retinochoroiditis. *Int Ophthalmol*2013;33:133—7
11. Levinson RD, Brezin A, Rothova A, Accorinti M, Holland GN. Research criteria for the diagnosis of birdshot chorioretinopathy: results of an international consensus conference. *Am J Ophthalmol*2006;141:185—7.
12. Monnet D, Brézin AP, Holland GN, Yu F, Mahr A, Gordon LK, et al. Longitudinal cohort study of patients with birdshot chorioretinopathy. I. Baseline clinical characteristics. *Am J Ophthalmol*2006;141:135—42.
13. Gass JD. Vitiliginous chorioretinitis. *Arch Ophthalmol*1981;99:1778—87.
14. Birch DG, Williams PD, Callanan D, Wang R, Locke KG, Hood DC. Macular atrophy in birdshot retinochoroidopathy: an optical coherence tomography and multifocal electroretinography analysis. *Retina* 2010;30:930—7
15. Papadia M, Jeannin B, Herbort CP. OCT findings in birdshot chorioretinitis: a glimpse into retinal disease evolution. *Ophthalmic Surg Lasers Imaging* 2012;43:S25—31.

16. Priern HA, Oosterhuis JA, Birdshot chorioretinopathy : clinical characteristics and evolution. Br J Ophthalmol 1988 ; 72 (9) : 646-659.
17. Vitale AT, Rodriguez A, Foster CS. Low-dose cyclosporine therapy in the treatment of Birdshot retinochoroidopathy. Ophthalmology 1994 ; 101 (5) : 822-831.
18. Fardeau C, Herbort CP, Kullmann N, Quentel G, LeHoang P. Indocyanine green angiography in birdshot chorioretinopathy. Ophthalmology 1999;106:1928—34

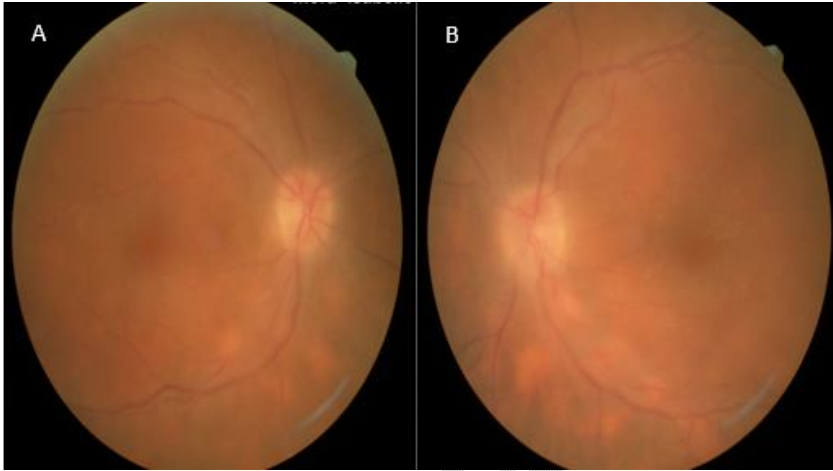

Figure 1: Retinography of both eyes with bilateral papilledema with yellowish oval spots. A: right eye /B: left eye

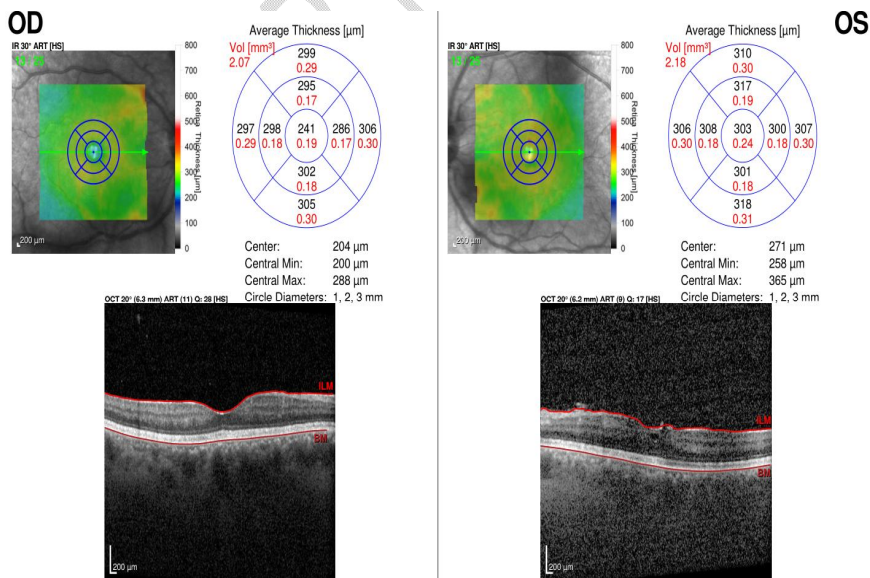


Figure2: Macula OCT showing cystoid macular edema in the left eye.

UNDER PEER REVIEW

