

## Serie Of Vagal-Mediated AV Block About 2 Cases

## Abstract

Vagally mediated atrioventricular (AV) block is defined as a paroxysmal AV block, localized within the AV node, associated with slowing of the sinus rate. All types of second-degree AV block, including pseudo-Mobitz II block, and complete AV block, may be present. In this article, we present a serie of 2 patients with recurrent syncope accompanied by transient second AV block.

Our patient were a 30-year-old man and a 23 years old woman. They were referred for recurrent syncope which was not associated with any other symptoms nor special medical history. At their admission, the clinical examinations were generally normal, their paraclinical exams too, including ECG; echocardiography and biological data. In both of cases the Holter-ECG revealed transient AV block, and their explorations of autonomic nervous system showed major vagal hyperactivity. Effort test was performed too for searching AV block at effort, but they with no particularity.

For treatment, we suggested a therapeutic plan composed of lifestyle modification and other measures. Pacing was not indicated considering the good improvement after two years of treatment and serious follow-up.

Physiological vagally hypertonia is frequent at young and athlets people. Vagally mediated atrioventricular (AV) block is defined as a paroxysmal AV block associated with slowing of the sinus rate secondary to a surge in parasympathetic activity. Syncope is a common symptom and it may be associated with identifiable trigger. It may be asymptomatic as noticed on Holter recordings. Extrinsic vagal AVB also known as vasovagal syncope, which is typically treated with lifestyle modification, isotonic maneuvers, and rarely medication or pacemaker insertion.

## Keywords

Vagally AVB - Syncope - Rythmology - Holter ECG - AVB

## INTRODUCTION:

Vagally mediated atrioventricular (AV) block is defined as a paroxysmal AV block, localized within the AV node, associated with slowing of the sinus rate. All types of second-degree AV block, including pseudo-Mobitz II block, and complete AV block, may be present. Most of the patients have normal AV conduction. Vagally mediated AV block is benign, it can be recorded as an asymptomatic or symptomatic event (syncope/pre-syncope). Syncope due to this form of AV block should be diagnosed and managed as neurally mediated syncope.

There is little published information on vagally mediated AV block, and in clinical practice it often goes unrecognized. In this article, we present a serie of 2 cases with recurrent syncope accompanied by transient second AV block.

## Observation :

### First observation :

A 30-year-old man was referred to our cardiology center for recurrent syncope. The patient had no specific medical history : his syncope was not associated with any other symptoms and no prodromal events were noted. At his admission, he was conscious and hemodynamically stable. Physical examination was generally normal. His ECG; echocardiography (Fig.N1-N3) and biological data were all normal. The precise cause of his syncope was not detected until a Holter-ECG revealed transient AV block ((Fig.N2). We also performed an exercise ECG looking for exercise AV block, which was unremarkable. After all, we performed an exploration of his autonomic nervous system that showed major vagal hyperactivity. In fact, he is under serious follow-up and repeated Holter-ECG recordings that have shown good improvement after our advice on lifestyle modification and other measures.

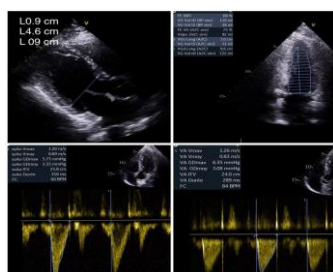


Fig.N1

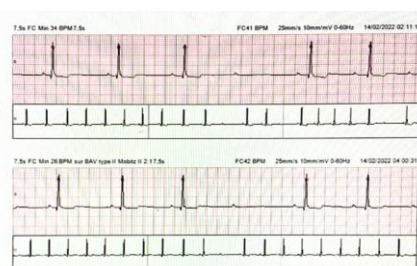

Fig.N2

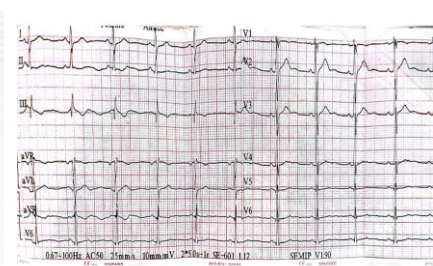


Fig.N3

Fig.N1-N3. Physical examination Echocardiography

Second observation:

A 23 years old woman, was brought to the emergency ward because of syncope. She had presented similar episodes that were frequent but with irregular intervals. There were no trauma's history, transfusion, food or drug allergy nor poisoning. She had a normal birth, growth and development. She reported weakness, diplopia, nausea before the syncope attack, when she recovered to consciousness. At the admission, she was conscious and hemodynamically stable. There was no heart murmur at the auscultation area of each valve, no tremor or pericardial friction. The response to carotid sinus pressure and Valsalva maneuvers were tested. ECG was normal with sinoatrial rhythm (Fig.N4). Laboratory examination, echocardiography and cerebral MRI scan were normal (Fig.N6). 24-h electrocardiogram showed that P-P interval and RR interval were equidistant for each one but P wave and QRS wave had no fixed relationship, for that, paroxysmal second-degree atrio-ventricular block Mobitz-II was diagnosed (Fig.N5). According to the results of autonomic nervous system test, her autonomic profile showed major vagal hyperactivity (Fig.N7). 'We performed Effort-test for searching AV block at effort with no particularity. Responses of blood pressure and heart rate during the Valsalva maneuver showed a normal increase in blood pressure that was evident within a few seconds after the beginning of the maneuver. For treatment, we suggested a therapeutic plan composed of lifestyle modification, isotonic maneuvers, salty diet, vitamin-therapy with magnesium, compression socks, cardio-tonic (Chlorhydrate etilefrine), and veino-tonic. Our rythmopole did not indicated pacing considering the good improvement after two years of treatment and well surveillance.

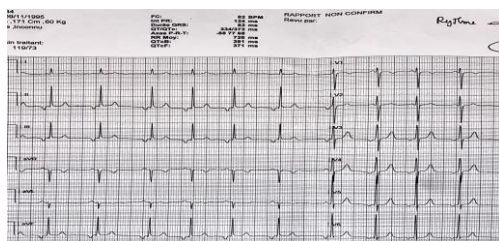


Fig.N4

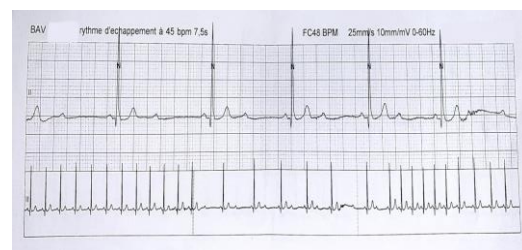


Fig.N5

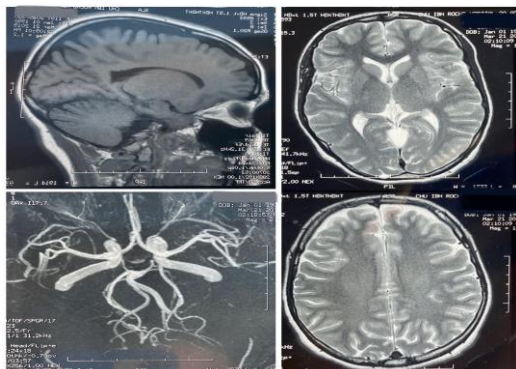


Fig.N6:

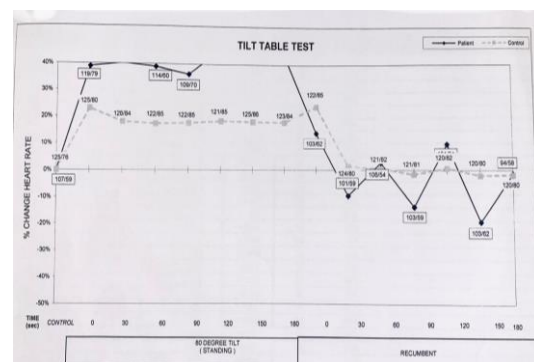


Fig.N7

Fig.N4: shows her basic ECG, it was normal with coronary sinus

Fig.N5: shows her normal echocardiography with EF estimated at 62%.

Fig.N6: shows her normal Cerebral MRI

Fig.N7: Our goal of tilt table testing was Reproduction Symptoms and to correlate them with BP and HR values. Later we discussed the quite different parameters for identifying and quantifying orthostatic hypotension (OH, including immediate and delayed OH), diagnosing postural tachycardia syndrome (POTS), and provoking neurally mediated hypotension (NMH) or neurally mediated syncope (which includes vasovagal syncope). None of these were notable.

## DISCUSSION:

Vagally mediated atrioventricular (AV) block is defined as a paroxysmal first, second- or third-degree AV block associated with slowing of the sinus rate. A vagal input depresses sinus node function and AV nodal conduction, but does not influence the velocity of conduction in the His-Purkinje system. It is likely that the site of vagally mediated AV block is within the AV node; the results of some electrophysiological studies during which this form of AV block has been reproduced confirm this site (1,2,3). There are no data on the prevalence of vagally mediated second- or third-degree AV block. Owing to its poor recognition and unpredictability, it is probably under-reported in the literature.

According to the definitions codified in 1978 by WHO (4) and by the American College of Cardiology (5) Mobitz type II AV block is defined as the occurrence of a single non-conducted P wave associated with constant PR intervals before and after the blocked impulse, provided that there are at least two consecutive conducted P waves and the sinus rate (or the PP interval) is constant. The pause encompassing the blocked P wave must be equal to two PP cycles.

Vagally mediated paroxysmal AV block is purely functional and relatively benign, it always occurs secondary to a surge in parasympathetic activity at the atrioventricular node (6). In some cases, the cause of vagal overactivity is identifiable, since it occurs during situations characterized by enhanced vagal tone, such as vomiting, coughing, difficulty in swallowing and hiccups, but in the vast majority of patients the cause of the vagal surge is not evident (1-3).

Acute vagal hypertonia is one of the physiopathological components of vasovagal syncope ; in cardioinhibitory forms, it can induce a more or less prolonged asystole by auriculoventricular block (7).

This cardiodepressive reaction can be observed, in predisposed patients, during a tilt test or during the recovery phase of an exercise test.

Vagal hypertonia can also be chronic, especially in athletes during intensive training; it can be responsible for a first or second degree type I block present in 9% of cases on a systematic ECG (8). These asymptomatic blocks, which disappear with

exercise, should be considered as physiological as those observed during the night in young subjects (9, 10).

Transient atrioventricular blocks of various degrees recorded during left temporal epileptic seizures are thought to be due to intense stimulation of the parasympathetic system and could explain some sudden deaths of epileptics by prolonged asystole [11].

In sleep apnea syndrome, secondary vagal hypertonia could be the cause of nocturnal atrioventricular blocks, many cases have been reported [12], but with a much lower frequency than sinus pauses.

A differential diagnosis must be made between a vagally mediated AV block and an AV block secondary to anatomical involvement of AV conduction that is, an intrinsic AV block. A simultaneous depression of sinus node function and AV nodal conduction suggests that the mechanism of the block does not lie within, but above, the two nodes, and, the parasympathetic system is probably involved. Therefore, the simultaneous appearance of a second- or third-degree AV block and sinus slowing essentially rules out an intrinsic AV block. The differential diagnosis between vagally mediated and intrinsic AV block may be difficult when there is only a slight increase in PP intervals, which is consistent with sinus arrhythmia. In the opinion of some authors (13,14), an increase in this interval of as little as 40 ms, associated with paroxysmal AV block, suggests that the block is of vagal origin.

Syncope is a common symptom accounting for 1% of all admissions in emergency departments (15,16,17). The universal underlying mechanism leading to syncope is a global transient cerebral hypoperfusion resulting from severe cardiac rhythm disturbances (bradycardia or tachycardia) and/or intense hypotension (18). Our patients presented recurrent episodes of syncope, their electrocardiograms between the episodes were normal. The precise cause of syncope went undetected until an Holter-ECG revealed transient AV block. The patients had bouts of nausea and weakness preceding the attacks. Consequently, it appears that paroxysmal reflex AV block resulted in syncope.

Syncope is the main accompanying symptom in approximately 40% patients affected by recent-onset persistent AVB (19,20,21). However, the prevalence of syncope due to paroxysmal AVB is probably under reported (22). In recent years, newly available long-term ECG monitoring devices have increased the diagnostic yield (23,24). Vagally mediated atrioventricular (AV) block may be associated with identifiable triggers including vomiting, micturition, intense coughing, or phlebotomy, it may be asymptomatic, as noticed on Holter recordings, especially during nighttime (6).

Sporadic cases of complete heart block related to certain vagotonic reflexes, such as coughing (Hart et al., 1982) (25) and swallowing (Sapru et al., 1971(26); Tomlinson and Fox,1975 (27); Wik and Hillestad, 1975 (28) have been reported. Two patients with recurrent vagally mediated complete AV block without any precipitating event were described by Strasberg et al.1981 (29), they suggested that reflex vagally mediated paroxysmal AV block exists as a clinical syndrome.

The carotid sinus massage resulted in normal slowing of sinus node discharge in our second case without precipitation of any AV block. Similarly, during Valsalva

manoeuvre there was normal slowing of the sinus rate, the retching reflex failed to provoke AV block to our patient. It is well known that the effect of vagal stimulation depends upon various factors, such as the intensity of stimulation, the method of stimulation, and the resting sympathetic activity (De la Fuente et al., 1969; Moore and Spear, 1976 (30,31). In the laboratory, it may thus be difficult to control all these factors to induce a spontaneous phenomenon, the association of nausea and vomiting with these episodes is intriguing.

Extrinsic vagal AVB (EV-AVB), also known as vasovagal syncope (or neurocardiogenic syncope), which is typically treated with lifestyle modification, isotonic maneuvers, and rarely medication or pacemaker insertion (6), in contrast intrinsic AVB (I-AVB) and extrinsic idiopathic paroxysmal atrioventricular block (EI-AVB) treated with pacemaker implantation (13,14).

We objectified as a cause of syncope, the entity of paroxysmal vagally mediated AV block (EV-AVB). It has been well documented that some patients with unexplained syncope may benefit from pacemaker insertion (Gulamhusein et al., 1982) (32), thereby substantiating the existence of paroxysmal brady-arrhythmia in such patients. Cardiac pacing has much lower efficacy in preventing syncopal recurrences in patients affected by paroxysmal vagally mediated AV block (EV-AVB) even if a spontaneous asystolic reflex has been documented. No studies have specifically investigated the effect of cardiac pacing in patients with EV-AVB. Indeed, all studies on cardiac pacing have involved patients affected by vasovagal syncope, with EV-AVB patients constituting a minority of the population. Therefore, we can only infer that the result of pacing in the EV-AVB subgroup is not different from that of the overall population. In the ISSUE 2, SUP 2, and ISSUE 3 trials [33,34,35], dual-chamber cardiac pacing in patients with syncope and documentation of asystolic pause (either sinus arrest or AVB) by means of ECG monitoring was associated with a not infrequent recurrence rate of syncopal events (12–25% at 2-year follow-up). Although cardiac pacing is the most effective therapy when bradycardia is responsible for syncope, syncope may recur because of the coexistence of a vasodepressor reflex, which is present to some degree in virtually all patients.

The effect of treatment with theophylline in prevention of syncopal recurrences has been investigated, A few small observational studies on patients with reflex syncope treated with theophylline have recorded a recurrence rate ranging between 12% and 22% [36,37,38].

There is a consensus that syncope due to vagally mediated AV block should be diagnosed and managed as neurally mediated syncope, according to the European guidelines on syncope (39). We believe that, in patients with an asymptomatic vagally mediated AV block, pacemaker implantation is not indicated, since the phenomenon is benign. These patients should only be followed up in order to monitor the possible appearance of symptoms (40). Our patients did not undergo pacemaker implantation, after 2 years of follow up and repeated Holter-ECG recordings they have well improvement.

Even in the absence of robust evidence, there is a general consensus that vagally mediated AV block is benign because it is localised within the AV node and not

in the His-Purkinje system and also, and especially, because it is not an expression of anatomical involvement of AV conduction. Moreover, a vagally mediated death appears to be an exceptional event and has never been demonstrated with certainty in humans (41). Nevertheless, vagally mediated AV block can cause syncope, which could be recurrent.

## **CONCLUSION:**

Physiological vagally hypertonia is frequent at young and athletes people, especially at night. Vagally mediated atrioventricular (AV) block is defined as a paroxysmal AV block associated with slowing of the sinus rate secondary to a surge in parasympathetic activity. Syncope is a common symptom and it may be associated with identifiable triggers (vomiting, intense coughing ...), however it may be asymptomatic as noticed on Holter recordings. Extrinsic vagal AVB also known as vasovagal syncope, which is typically treated with lifestyle modification, isotonic maneuvers, and rarely medication or pacemaker insertion.

## **DECLARATION OF INTEREST:**

The authors report no conflicts of interest. The authors alone are responsible for the content and writing of the paper.

## **REFERENCES :**

- 1) Baron SC, Huang SK. Cough syncope presenting as Mobitz type II atrioventricular block. An electrophysiologic correlation. *Pacing Clin Electrophysiol* 1987;10:65–9.
- 2) Nakagawa S, Koiwaya Y, Tanaka K. Vagally mediated paroxysmal atrioventricular block presenting as ‘Mobitz type II’ block (Letter). *Pacing Clin Electrophysiol* 1988;11:471–2.
- 3) Kakuchi H, Sato N, Kawamura J. Swallow syncope associated with complete atrioventricular block and vasovagal syncope. *Heart* 2000;83:702–4.
- 4) WHO/ISC Task Force. Definition of terms related to cardiac rhythm. *Am Heart J* 1978;95:796–806.
- 5) Suravicz B, Uhley H, Borun R, et al. The quest for optimal standardization of terminology and interpretation. *Am J Cardiol* 1978;41:130–45.
- 6) Bansal R, Mahajan A, Rathi C, Mehta A, Lokhandwala Y. What is the mechanism of paroxysmal atrioventricular block in a patient with recurrent syncope? *J Arrhythmia*. 2019;35:870–872.

- 7) Talwar KK, Edvarsson N, Varnaukas E. Paroxysmal vagally mediated AV block with recurrence syncope. *Clin Cardiol* 1985;8:337-40.
- 8) Meyles I, Kapfinsky E, Yahini JH, Hanne-Paparo N, Neufeld HN. Wenckebach A-V block: a frequent feature following heavy physical training. *Am Heart J* 1974;90:426-30.
- 9) Brodsky M, Wu D, Denes P, Kanakis C, Rosen KM. Arrhythmias documented by 24 hour continuous electrocardiographic monitoring in 50 male medical students without apparent heart disease. *Am J Cardiol* 1977;39:390-5.
- 10) Young D, Eisenberg R, Fish B, Fisher JD. Wenckebach A-V block (Mobitz I) in children and young adults. *Am J Cardiol* 1977;40:393-9.
- 11) Altenmüller DM, Zehender M, Schulze-Bonhage A. High-grade atrioventricular block triggered by spontaneous and stimulation-induced epileptic activity in the left temporal lobe. *Epilepsia* 2004;45: 1640-4.
- 12) Lazarus A, Py A, Guerin F, Valty J, Le Heuzey JY. Arythmies et syndrome d'apnées obstructives du sommeil de l'adulte. *Arch Mal Cœur* 1993;86:1753-9.
- 13) Lange HW, Ameisen O, Mack R, et al. Prevalence and clinical correlates of non-Wenckebach, narrow-complex second-degree atrioventricular block detected by ambulatory ECG. *Am Heart J* 1988;115:114–20.
- 14) Barold SS, Hayes DL. Second degree atrioventricular block: a reappraisal. *Mayo Clin Proc* 2001;76:44–57.
- 15) Blanc JJ, L'Her C, Touiza A, Garo B, L'Her E, Mansourati J. Prospective evaluation and outcome of patients admitted for syncope over a 1 year period. *Eur Heart J* 2002;23: 767–8.
- 16) Farwell D, Sulke N. How do we diagnose syncope? *J Cardiovasc Electrophysiol* 2002;13: 9–13.
- 17) Disertori M, Brignole M, Menozzi C, Raviele A, Rizzon P, Santini M et al. Management of patients with syncope referred urgently to general hospitals. *Europace* 2003;5: 283– 91.
- 18) Moya A, Sutton R, Ammirati F, Blanc JJ, Brignole M, Dahm JB et al. The Task Force for the Diagnosis and Management of Syncope of the European Society of Cardiology(ESC) Guidelines for the diagnosis and management of syncope (version 2009). *Eur Heart J* 2009;30:2631–71.
- 19) Aste M., Oddone D., Donateo P. Syncope in patients paced for atrioventricular block. *Europace*. 2016;18:1735–1739.

- 20)Langenfeld H., Grimm W., Maisch B. Course of symptoms and spontaneous ECG in pacemaker patients: a 5-year follow-up study. *Pacing Clin Electrophysiol.* 1988;11:2198–2206.
- 21)Proclemer A., Ghidina M., Gregori D. Trend of the main clinical characteristics and pacing modality in patients treated by pacemaker: data from the Italian Pacemaker Registry for the quinquennium 2003–07. *Europace.* 2010;12:202–209.
- 22)Lee S., Wellens J.J., Josephson M. Paroxysmal atrioventricular block. *Heart Rhythm.* 2009;6:1229–1234.
- 23)Brignole M., Vardas P., Hoffmann E. Indications for the use of diagnostic implantable and external ECG loop recorders. *Europace.* 2009;11:671–687.
- 24)Locati E.T., Moya A., Oliveira M. External prolonged electrocardiogram monitoring in unexplained syncope and palpitations: results of the SYNARR-Flash study. *Europace.* 2016;18:1265–1272.
- 25)Hatt G, Oldershaw PJ, Cull RE, Humphrey P, Ward D: Syncope caused by coughinduced complete atrioventricular block. *PACE* 5, 564 (1982).
- 26)Sapm RP, Griffiths PH, Guz A, Eisele J: Syncope on swallowing. *Br Heart J* 33, 617 (1971) .
- 27)Tomlinson TW, Fox KM: Cminoma of the oesophagus with “swallow syncope.” *Br Med J* 2, 315 (1975)
- 28)Wik B, Hillestad L: Deglutition syncope. *Br Med J* 3, 747 ( 1975)
- 29)Strasberg B, Palileo E, Bauernfeind R, Swiryn S, Lam W, Rosen K: Clinically significant reflexly mediated paroxysmal A-V nodal block (abstr.) *Clin Res* 29, 244A (1981)
- 30)De la Fuente D, Jedlicka T, Moe CK: Time course of vagal effects on S-A and A-V nodes (abstr.). *Fed Proc* 28, 269(61) (1969) .
- 31)Moore EN, Spear JF: Effect of autonomic activity on pacemaker function and conduction. In *me Conduction System of the Heart. Structure, Function and Clinical Implications.* (Eds. Wellens HJJ, Lie KI, Janse MJ). Leiden, He Stenfert Kroese BV (1976) 100
- 32)Gulamhusein S, Naccarelli GV, KO PT, Prystowsky EN, Zipes DP, Barnett HJM, Heger JJ, Klein GJ: Value and limitations of clinical electrophysiologic study in assessment of patients with unexplained syncope. *Am J Med* 73, 700 (1982) .
- 33)Brignole M., Sutton R., Menozzi C. Early application of an implantable loop recorder allows effective specific therapy in patients with recurrent suspected neurally mediated syncope. *Eur Heart J.* 2006;27:1085–1092.

- 34) Brignole M., Ammirati F., Arabia F. Assessment of a standardized algorithm for cardiac pacing in older patients affected by severe unpredictable reflex syncope. *Eur Heart J.* 2015;36:1529–1535 .
- 35) Brignole M., Donateo P., Tomaino M. Benefit of pacemaker therapy in patients with presumed neurally mediated syncope and documented asystole is greater when tilt test is negative: an analysis from the third International Study on Syncope of Uncertain Etiology (ISSUE-3) *Circ Arrhythm Electrophysiol.* 2014;7:10–16.
- 36) Šinkovec M., Grad A., Rakovec P. Role of endogenous adenosine in vaso-vagal syncope. *Clin Auton Res.* 2001;11:155–161
- 37) Benditt D.G., Benson W., Kreitt J. Electrophysiologic effects of theophylline in young patients with recurrent symptomatic bradyarrhythmias. *Am J Cardiol.* 1983;52:1223– 1229.
- 38) Brignole M., Gaggioli G., Menozzi C. Adenosine-induced atrioventricular block in patients with unexplained syncope: the diagnostic value of ATP testing. *Circulation.* 1997;96:3921–3927.
- 39) Moya A, Sutton R, Ammirati F, et al. Guidelines for the diagnosis and management of syncope (version 2009). The Task Force for the Diagnosis and Management of Syncope of the European Society of Cardiology (ESC). *Eur Heart J* 2009;30:2631–71.
- 40) Vardas PE, Auricchio A, Blanc JJ, et al. Guidelines for cardiac pacing and cardiac resynchronization therapy. The Task Force for Cardiac Pacing and Cardiac Resynchronization Therapy of the European Society of Cardiology. Developed in collaboration with the Heart Rhythm Association. *Eur Heart J* 2007;28: 2256–95.
- 41) Alboni P, Alboni M, Gianfranchi L. Simultaneous occurrence of two independent vagal reflexes: a possible cause of vagal sudden death. *Heart* 2011;97:623–5.