

Urrets-Zavalía Syndrome after Penetrating Keratoplasty: a case report

Abstract:

Urrets-Zavalía syndrome is a dreaded complication of anterior segment surgery and the most common in patients undergoing corneal transplantation. Avoiding the prescription of mydriatic eye drops during the postoperative period is the mainstay of its therapy, which focuses on prevention. One month after having keratoplasty in the left eye, a 42-year-old man presented with Urrets-Zavalía syndrome and ocular hypertonia at 35 mmHg. Medical and surgical management were required in this situation.

The purpose of our presentation is to describe a real-world instance of Urrets-Zavalía syndrome.

Keywords: Urrets-Zavalía; Penetrating keratoplasty; Hypertonia; Mydriatics; Corneal abscess.

Introduction:

The Urrets-Zavalía syndrome, which involves a lack of reflexes in the pupils followed by a gradual shrinking of the iris, has been observed as a potential consequence of penetrating keratoplasty, a procedure for a full thickness cornea transplant. It is frequently linked to ocular hypertonia. (1) (2)

Case report:

We describe the case of a 42-year-old man with a history of a treated bacterial central corneal abscess who underwent penetrating keratoplasty in his left eye.

The initial postoperative control was normal with a visual acuity of 2/10 and slight corneal edema.

He presented at the ophthalmological department one month after the operation with decreased visual acuity and a painful eye.

Ophthalmological examination revealed a limited visual acuity to counting fingers, an abolished direct and consensual photomotor reflex, and ocular hypertonia at 35 mmHg.

Examined under a slit lamp, the patient had a minor amount of corneal edema with superficial neovessels, a shallow anterior chamber, pupillary fibrin membrane development, iridocorneal synechiae spanning 360 degrees, areflexic mydriasis, and an opalescent lens (figure 1).

The left eye's fundus was inaccessible, and the B-scan ultrasonography was normal.

The Corneal OCT was performed to objectify a disorder of corneal architecture, including the existence of iridocorneal synechiae and a significant decrease in central corneal thickness to 452µm (figure 2).

The left eye's findings suggested a diagnosis of Urrets-Zavalía syndrome.

The case was managed by reducing IOP with hypotonic medical therapy, repairing the anterior segment surgically by releasing synechiae, removing the cyclitic membrane, and reforming the anterior chamber with a peripheral iridectomy.

Corticosteroids were used postoperatively to prevent graft rejection.

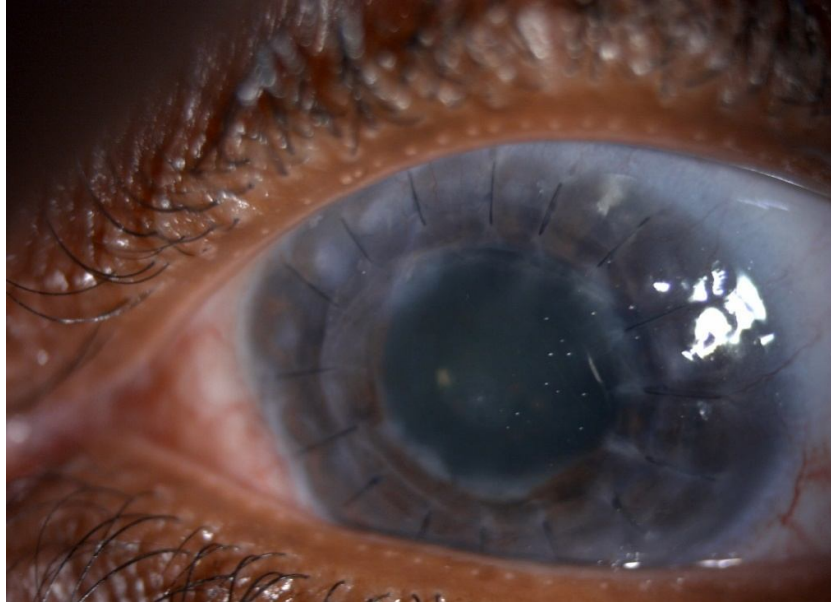


Figure 1: Slit lamp images of the anterior section of the left eye show penetrating keratoplasty; the graft's diameter was 8 millimeters, and the pupil was in reflection mydriasis due to ectropion of the posterior uvea.

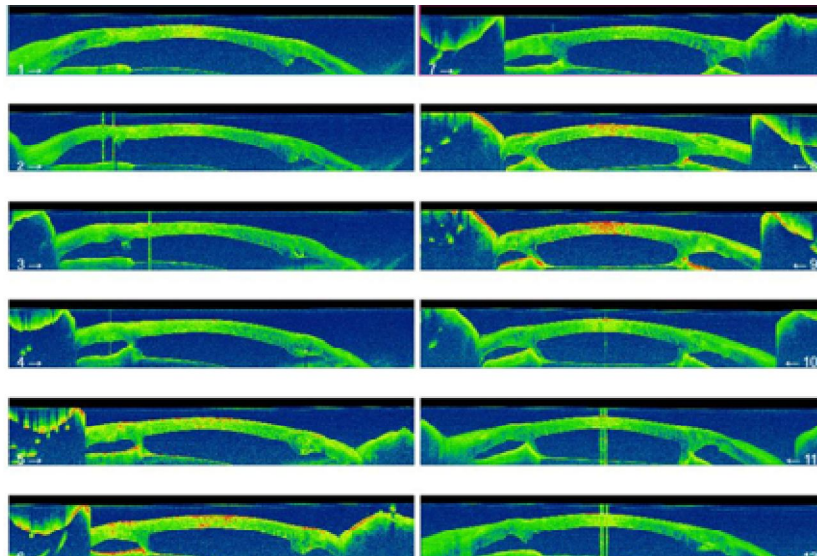


Figure 2: OCT of the anterior segment of the left eye revealing the existence of the iridocorneal synechiae .

Discussion:

The Urrets-Zavalía syndrome is a permanent dilated pupil following ophthalmic surgery; It occurs after anterior segment surgery and is usually caused by a postoperative elevation in intraocular pressure (3). Glowing, haloing, and photophobia are symptoms of Urrets-Zavalía syndrome. The pupillary dilation, however, may occasionally be reversible (4). Urrets-Zavalía syndrome is still a clinical reality in corneal transplants even though it is not graft rejection and does not affect final visual acuity. (2)

Conclusion:

Urrets-Zavalía Syndrome was originally identified after a penetrating keratoplasty and has been linked to other eye surgical operations. Mydriatic drops given after surgery, a brief period of elevated intraocular pressure, or surgical trauma are common causes of this syndrome.

Consent

As per international standard or university standard, patient(s) written consent has been collected and preserved by the author(s).

Ethical Approval:

As per international standard or university standard written ethical approval has been collected and preserved by the author(s).

References:

- [1] T. Bourcier, O. Laplace, O. Touzeau, S.M. Moldovan, V. Borderie, L. Laroche. Syndrome d'Urrets-Zavalía - 08/03/08, journal français d'ophtalmologie, Doi : JFO-03-2001-24-3-0181-5512-101019-ART11
- [2] I. Bechakh et al. Urrets-Zavalía syndrome: report of 2 cases. PAMJ - Clinical Medicine. 2022;8:43. [doi: 10.11604/pamj-cm.2022.8.43.33409]
- [3] Camila R. KochPaulo, Vinicius de Carvalho SenaPaula, Caroline Matos Almeida Matheus Borges Fernandes, Urrets-Zavalía Syndrome following cataract surgery in a case of anterior megalophthalmos, Letters • Arq. Bras. Oftalmol. 82 (04) • Jul-Aug 2019 • <https://doi.org/10.5935/0004-2749.20190064>
- [4] Niruthisard, D., Kasetsuwan, N. Unilateral Urrets-Zavalía syndrome after Implantable Collamer Lens implantation: a case report and review of the literature. J Med Case Reports 15, 467 (2021). <https://doi.org/10.1186/s13256-021-03063-2>