

# Penetrating vertebral-medullary wound by ballistic weapon. A clinical cases and literature reviews

Comment [اشرف 1]: Is the research reviews or case report?

## ABSTRACT :

Introduction: Penetrating trauma by vertebromedullary ballistic weapon is a rare pathology in Cameroon, it may be related to the existence of armed conflict zones, it may be responsible for CSF leakage, spinal instability and/or partial or complete neurological deficits. The controversial question is when to operate on penetrating ballistic spinal injury with complete neurological deficit.

Clinical case: We report the clinical case of a patient victim of a close range shooting of a real ball gun, in the paraspinal region opposite D8, by confusion of his status to the enemy in armed conflict zone in Cameroon. Followed Fränkel A paraplegia of D8 level of cerebrospinal fluid with CT scan of spine, stability of spine and insertion of Ball under upper plateau of D8. He was operated on to close the gap and remove the ball. The situation of the ball destroying the posterior 2/3 of the vertebral body of D8 and located in the anterior 1/3 of the body of D8 motivated the stabilization of the spine by the osteosynthesis material, the operative follow-up was marked by the absence of infection, but without any recovery of the neurological deficit.

Conclusion: Penetrating gunshot wounds of the spine are rare in Cameroon, CSF leakage and spinal instability are emergency surgical indications, extraction of the bullet in a patient with a complete neurological deficit remains controversial, but the bullet should be extracted when there is an operative indication, in case of high risk of spinal instability, the patient should benefit from a spondylodesis.

**Key word: Wound- vertebromedullary- BALL- CSF leak- surgery.**

## Introduction

A trauma is said to be penetrating when the penetrating agent crosses the skin to reach the underlying anatomical structures. It is thus opposed to closed trauma.(1) at the level of the spine. the penetration crosses the spine reaching the dura mater or the meninges, the spinal cord and/or the nerve roots. Penetrating injuries are mainly caused by knives and firearms,

Comment [اشرف 2]: The introduction needs statistics for the number of cases that have been injured by Penetrating vertebral-medullary wound by ballistic weapon.

rarely by work accidents, road accidents, falls, etc. The degree of injury depends on the type of weapon. Bullet wounds represent the second most frequent cause of spinal cord injury after vehicular trauma in developed countries(1), it is rare in Cameroon and its occurrence is linked to the existence of conflict zones and the burrs of weapons.

Firearm injuries are a very heterogeneous group, given the variety of weapon types. Bullets and pellets fired by individual handguns (pistols, revolvers) or shoulder weapons (assault rifles: Kalashnikov AK 47, Colt M16, FAMAS, etc.) are the projectiles most frequently involved in civilian practice. The injuries caused by a projectile (injury profile) depend on many factors (2,3,4): Energy of the projectile, Distance from the target, Cavitation phenomenon, Stability of the projectile, Nature of the projectile, Characteristics of the exposed tissue(2).

#### **Case presentation**

We report here the case of a patient with a vertebrae-medullary wound from a Frankel A paraplegia weapon.

1 MU case, 34 years old, received at the Bafoussam CHR for paraplegia,

The history of the disease goes back to 4 days when the patient was shot in the back at the end of a very rebellious zone by a rebel for suspicion of complicity with the governmental weapon, followed by a brutal deficit of the lower limbs, motivating his transport in a first health structure where he received the first care before being referred to our health structure.

On admission he was an algic and anxious patient with a Fränkel A paraplegia of dorsal level D6 D7. He presented a right paravertebral entrance door with serosity that discoloured the yellow Betadine, suggesting a CSF leak on spinal trauma (fig. 1). (fig1) The exit door is not seen.

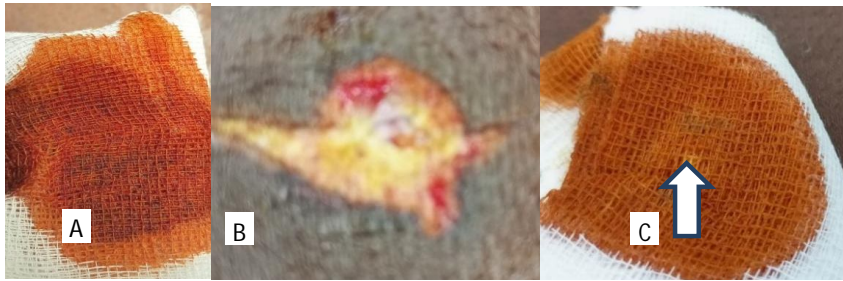

Fig1: Discolouration test of the pad (A) through the bullet entry point (B) shown by an arrow (c)

A lumbar CT scan was performed showing a fracture of the D8 lamina with a large fragment under the upper shelf of the vertebral body of intra canal bone and a bullet in the vertebral body of D8 (fig2) with integrity of the anterior wall of the spine.

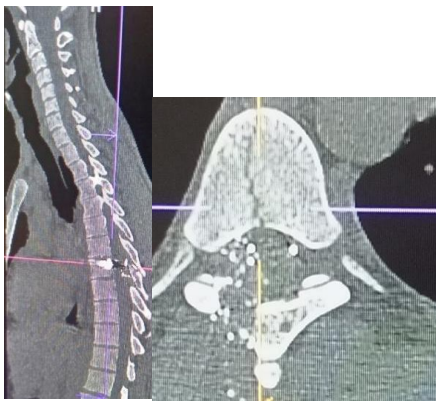


FIG 2: Blade injury and bullet insertion under the upper vertebral body plateau of D8

The leakage of CSF through the portal of exposure made the patient a surgical indication that allowed the closure of the dural breach after the extraction of the bullet.

The postoperative period is good with no particular complications.

Follow-up 4 months later shows complete healing with persistent paraplegia Fränkel A

**Discussion:**

The treatment of gunshot wounds to the spine is a subject of ongoing discussion and controversy (5). It takes into account the stability of the spine, neurological deficits, the risk

of infection in case of CSF leakage or the relationship of the bullet path with the hollow organ of the abdomen (6)

The clear liquid flowing from the entrance door of our patient's bullet and discolouring the swab soaked in polyvidone-iodine, is similar to CSF, which attests to the leakage of CSF indicating the existence of a dural wound with significant infectious risk;

Traumatic pneumorrhachis (air in the spinal canal) described in other patients with CSF leakage has not been described (7,8).

The following classification of injuries may be used from the point of view of treatment:

1. Injuries which have perforated the spinal theca.
2. Injuries which have not perforated the spinal theca.
3. Compression of the spinal cord, which may be produced by the passage of a

bullet through the vertebrae without actual pressurisation of the missile or bone fragment.

Our patient presents with a complete lower limb deficit Frankel A, with a posterior vertebral paramedian portal of entry with leakage of clear fluid which is probably CSF. This is the surgical indication. The spine appears stable after the trauma on CT. During the intraoperative extraction of the bullet, we noted that the bullet was in the anterior 1/3 of the vertebral body and therefore exposed it to a great risk of instability. This is what justified the D6D7-D9D10 spondylodesis performed on this patient. Stabilization surgery for patients with PSCI is not typically required since most penetrating injuries are not associated with instability of the spine.(10,11) However, debate continues over whether or not surgical decompression, including bone and projectile removal, in patients with penetrating spinal cord injury (PSCI) provides any benefit for neurological function compared with nonsurgical treatment. Some studies suggest little benefit with increased risk of postoperative complications in patients with PSCI who undergo surgery(12,13) Other studies suggest that surgery can be beneficial particularly for patients with incomplete PSCI or in patients experiencing progressive neurological decline.(10,14,15)

The most serious complications occur in gunshot wounds with an abdominal or thoracic portal with injury to the hollow and noble organs, which can lead to septic complications after gunshot wounds of the spine, such as osteomyelitis, meningitis, and intrathoracic or intra-abdominal abscess, often lead to catastrophic consequences and to poor response to

therapeutic management (16 ,17). The risk that our patient may present is migration of the bullet into the medullary canal.

#### Conclusion:

The wound of the rachis by ball with leakage of the cephalo rachidien liquid are rare in and are of neurosurgical urgency, it exposes to the redoubtable infections such as the meningitis and the traumatic pneumorrhaxie what represents an indication surgical of urgency. In the event of sand traumatism by ball by posterior see, associated with a completed deficit, the ablation of the ball is very discussed just like the stabilization of the rachis by the material of osteosynthesis. In the case of a very high risk of instability or post-traumatic instability due to the bullet, stabilisation with osteosynthesis material is essential.

#### References

- 1-Andrew Brash,1 Dia R Halalmeh, 2 Gary Rajah,3 Joshua Loya,3 and Marc Moisi4 ,Surgical intervention for lumbar foraminal gunshot wounds: a case report and review of the literature ,Cureus. 2019 Jul; 11(7): e5269.
- 2- J.L. DABAN, M. BENSALAH, C. HOFMANN, Y. GOUDARD, F. PONS, +B. DEBIEN, Spécificités de la prise en charge des traumatismes pénétrants, joint session sfmu/sfar urgences digestives , urgence 2012,chap 68 p 1-13
- 3- McSwain N.E., Jr. blunt and penetrating chest injuries. World journal of surgery 1992; 16(5): 924-9.
- 4- Fackler M.L., Wound ballistics. A review of common misconceptions. JAMA: the journal of the American Medical Association 1988; 259(18): 2730-6
- 5-By ALFRED J. HULL, F.R.C.S.,TREATMENT OF GUNSHOT WOUNDS OF THE SPINE. THE BRITISH MEDICAL JOURNAL APRIL 22, 1916 p 577- 580 9+2
- 6 -Nimrod Rahamimov , Hani Mulla , Shay Freiman, Cerebrospinal fluid leakage and pneumocephalus secondary to spine stab wounds J Orthopaed Traumatol (2010) 11:57-59 DOI 10.1007/s10195-009-0070-6
7. Goh BK, Yeo AW. Traumatic pneumorrhoea. J Trauma. 2005; 58:875-879. doi: 10.1097/01.TA.0000158249.77176.9A. [PubMed] [CrossRef] [Google Scholar]

**Comment [اشرف 13]:** Sources need new sources and writing them in the magazine format and uniformly in terms of font type

8- Marc D. Moisi,1 Jeni Page,1 Seymour Gahramanov,1 and Rod J. OskouianGlobalSpine J. Bullet fragment of the lumbar spine: the decision is more important than the incision,2015 Dec; 5(6): 523-526.  
doi : 10.1055/s-0035-1566231 PMCID: PMC4671882PMID: 26682104

9- Michael Liam Kelly, Mary Joan Roach, Gregory Nemunaitis, and Yuying Chen, Surgical and Nonsurgical Treatment of Penetrating Spinal Cord Injury: Analysis of Long-term Neurological and Functional Outcomes , Topics in Spinal Cord Injury Rehabilitation/Spring 2019 p 186- 193

10. Bono CM, Heary RF. Gunshot wounds to the spine. Spine J. 2004;4(2):230-240.

11- Jallo GI. Neurosurgical management of penetrating spinal injury. Surg Neurol. 1997;47(4):328-330.

12-Comparative study of functional recovery for surgically explored and conservatively managed spinal cord missile injuries. Neurosurgery. 1996;39(6):1133-1140.

13- Sidhu GS, Ghag A, Prokuski V, Vaccaro AR, Radcliff KE. Civilian gunshot injuries of the spinal cord: A systematic review of the current literature. Clin Orthop Relat Res. 2013;471(12):3945-3955.

14- Klimo P, Jr, Ragel BT, Rosner M, Gluf W, McCafferty R. Can surgery improve neurological function in penetrating spinal injury? A review of the military and civilian literature and treatment recommendations for military neurosurgeons. Neurosurg Focus. 2010;28(5):E4.

15- Splavski B, Vrankovic D, Saric G, Blagus G, Mursic B, Rukovanjski M. Early management of war missile spine and spinal cord injuries: Experience with 21 cases. Injury. 1996;27(10):699-702.

16- G Velmahos Ann R, D Demetriades Coll Gunshot wounds of the spine: should retained bullets be removed to prevent infection? Surg Engl 1994; 76: 85-87

17- Benzel EC, Hadden TA, Coleman JE. Civilian gunshot wounds to the spinal cord and cauda equina. Neurosurgery 1987; 20: 281-5.