

# Cardiac thrombosis in Behçet's disease: a diagnostic challenge.

- ABSTRACT:

Intracardiac masses have several etiologies: tumor, infectious, thrombotic. They constitute a diagnostic challenge for the clinician.

Behçet's disease is a chronic multisystemic vasculitis evolving by relapses. Intracardiac thrombosis in this disease deserves special attention because of its life-threatening nature. They often appear in the early stages of the disease, and the most frequent location is the right heart chambers. We present the case of a 23-year-old patient with an isolated mass in the right ventricle revealing an initial manifestation of Behçet's disease.

The presented clinical case highlights the importance of early recognition of Behçet's disease, as well as the awareness of including this disease in the differential diagnosis of intracardiac masses in young adults.

Keyword: Cardiac thrombosis, tumor, Behçet's disease, thoracic computerized tomography

## I. INTRODUCTION:

The incidence of intracardiac masses is very rare and their diagnosis can be very challenging for clinicians, particularly for those located in right cavities. They have several etiologies including benign, primary malignant or secondary metastatic cardiac tumors, vegetation and thrombus.

Multimodal imaging like thoracic computerized tomography (CT) scan and magnetic resonance imaging (MRI) can provide extra information about morphologic properties of intracardiac masses such as location, shape, size, mobility ..., when echocardiography is inconclusive.

Behçet's disease (BD) is a chronic multisystemic vasculitis of unknown etiology, affecting many young adults around the globe. Intracardiac thrombosis is a rarely associated complication of the disease.

We report the case of a 23-year-old young patient presenting with BD, revealed by an intra right ventricular thrombi. The presented clinical case highlights the diagnosis difficulty facing this situation.

## II. PRESENTATION OF CASE:

A 23-year-old young northern African adult was admitted to the emergency for sudden onset dyspnea associated with acute right chest pain and weight loss. He mentioned an episode of oral ulcers one month prior to the admission.

Physical examination revealed a normotensive patient at 120/70 mmHg, tachycardia at 130 beats, polypnea at 28 cycles, and saturation level (SpO<sub>2</sub>) at 86% in ambient air. Cardiac examination showed a B2 burst, with no signs of right or left heart decompensation. Pulmonary auscultation was unremarkable. The general examination showed a pseudofolliculitis and genital ulcers.

Admission electrocardiogram (ECG) showed sinus tachycardia at 120 beats per minute; right heart axis, normal auriculogram and PR space, fine QRS and negative T waves in V1-2-3.

The clinical probability of pulmonary embolism according to the Geneva score was intermediate, requiring dosage of D-dimer which came back positive at 3842 Nano gram per milliliter.

The CT thoracic angiogram showed a pulmonary embolism of the right inferior lobar branch with healthy walls with cardiomegaly (Right ventricle to left ventricle ratio  $> 1$ ) and signs of pulmonary arterial hypertension (PAH) as well as foci of infarction with right latero-tracheal and mediastinal adenopathies. In addition, there was a mass in the right ventricle that was not enhanced after contrast injection.

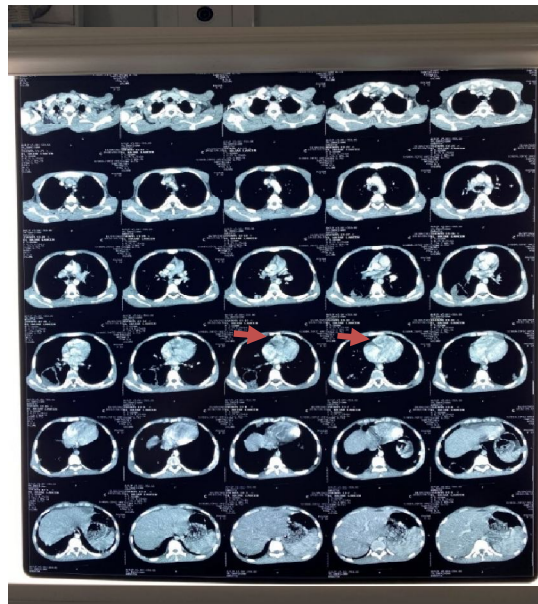


Figure 1: CT Thoracic angiogram showing intra-RV mass (red arrows)

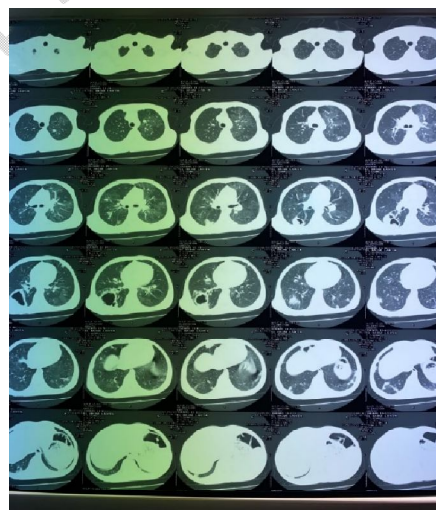


Figure 2: CT Thoracic angiogram showing right lobar pulmonary embolism with foci of infarction

A complementary echocardiographic study showed of preserved size and left ventricle ejection fraction, LVEF = 60%, non-dilated atria, free of echoes without significant mitro-aortic valvulopathy. However, the right ventricle (RV) was dilated and was the site of hyperechoic multilobular mass of variable size, mobile, filling the entire cavity up to the infundibulum with a high pulmonary hypertension of 69 mmHg, RV function was normal.

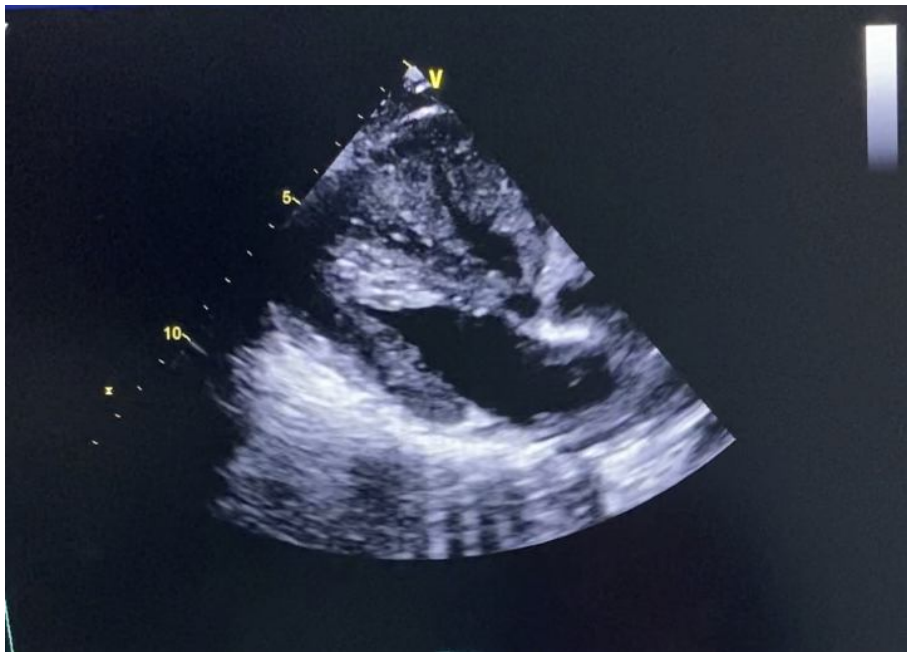

Figure 3 : Parasternal long axis view echocardiography showing the mass of the RV

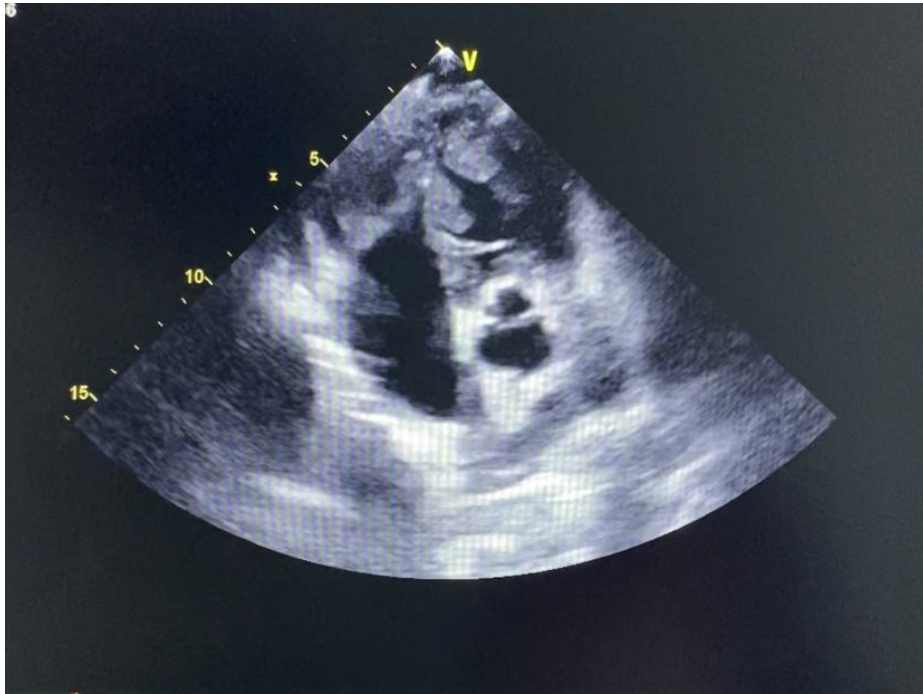


Figure 4: Short axis parasternal view echocardiography showing the large mass of the RV filling the pulmonary infundibulum

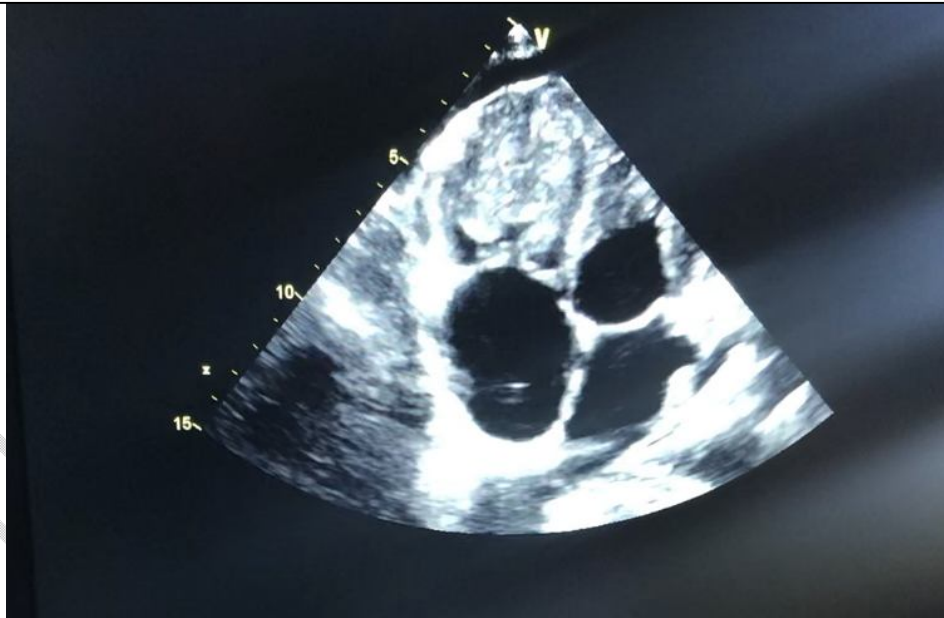


Figure 5: Apical 4 chamber view echocardiography showing the mass occupying the entire RV

A cardiac MRI to characterize the mass confirmed the diagnosis of intracavitary thrombus (hyposignal in T1 and T2; not enhanced after Gadolinium injection).

Standard biology showed a white blood cells count of 26500/mm<sup>3</sup> with biological signs of inflammation, hemoglobin at 10.8 g/dL, C-reactive protein (CRP) at 125 mg/l, sedimentation rate at 39 and fibrinogen at 3.8g/l, normal troponins and BNP levels.

The etiological investigation including: immunological tests, tumor markers, viral serology including cytomegalovirus (CMV), Epstein-Barr virus (EBV), hepatitis, HIV. Hemostasis and thrombophilia blood tests, as well as tuberculosis tests were negative.

According to the international criteria for Behçet's disease 2013, the young patient presented 3 major items of the disease (genital and oral aphthosis, vascular complication) which represent a score of 5 points. The diagnostic of BD was confirmed.

The initial treatment consisted of a curative anticoagulant with low molecular weight heparin 0,6 ml, 2 injections per day followed by **Acenocoumarol** 2 milligrams per day with a target INR between 2 and 3 and an antibiotic coverage (amoxicillin/clavulanic acid 1 gram, 3 times a day).

In addition, a trial treatment based on bolus **Corticosteroids** (Methylprednisolone 1 gram per day) for consecutive 3 days then prednisone 1 milligram per kilogram per day was initiated with a good clinico-biological evolution, followed by the administration of immunosuppressive drugs based on cyclophosphamide at a dose of 500 milligram/meter<sup>2</sup>/day once a month.

The echocardiogram performed at 3 months showed a decrease in the size of the intraventricular thrombi.

### III. DISCUSSION:

Behçet's disease (BD) is a chronic inflammatory systemic disease of undetermined etiology evolving by relapses. It affects preferably young men and is characterized by oral or bucco-genital aphthosis associated with various manifestations, the most frequent are cutaneous, ocular and articular. However, the neurological, cardiovascular and intestinal manifestations can be very severe (1).

In the absence of a biological marker of the disease like for other inflammatory disorders, the diagnosis is mainly clinical and can be evoked by a series of criteria, the most widely used are those of the International Behçet's Disease Study Group 2013 (table 1).

Sign/symptom	Points
Ocular lesions	2
Genital aphthosis	2
Oral aphthosis	2
Skin lesions	1
Neurological manifestations	1
Vascular manifestations	1
Positive pathergy test*	1*

Table 1: Criteria for Behçet's Disease: scoring > 4 indicates Behçet's diagnosis

In our case, the score was positive at 5, therefore the diagnosis of BD was confirmed.

Angio-Behçet is the vascular form of the disease, which affects vessels of all calibers and can manifest by venous and more rarely arterial thromboembolic disorders.

Classic cardiac manifestations, such as pericarditis and endocarditis, are exceptional in Behçet's disease and occur in 1 to 8% of cases (2, 3).

The subgroup of cardiac thrombosis deserves special attention because of its life-threatening nature. A genetic predisposition of intracardiac thrombus is incriminated, since it occurs predominantly in patients from the Mediterranean basin and the Middle East (4). Intracardiac thrombosis often occurs in the early stages of the disease, and the most frequent location is the right heart (right ventricle most frequently and then right atrium), as in our patient. Thrombi in multiple cavities have been found in 16% of patients with cardiac masses associated with Behçet's disease (5). The association of intracardiac thrombosis with venous thrombosis is also very common (6). Some authors state that pulmonary emboli are formed in situ, and not by embolization from the intra-cardiac mass (7). In our patient, the highly mobile nature of the mass and the healthy appearance of the pulmonary arteries on CT scan is rather in favor of embolization from the intra-RV mass.

Echocardiography remains an important tool in the initial approach to cardiac masses, given its accessibility (8). It allows to specify the localization and the extension of the mass and to look for signs of hemodynamic repercussions. Nevertheless, it is less efficient to evaluate soft tissues and extracardiac structures because of the poor acoustic windows, especially in the RV (9). Currently, different non-invasive modalities allow a better analysis of intra-cardiac tissues and masses such as magnetic resonance imaging (MRI) and cardiac CT. The performance of MRI can be decisive in the differential diagnosis because of its higher sensitivity and specificity. In our patient, cardiac MRI was essential for the final diagnosis, since it revealed the presence of an inflammatory mass with a strong thrombotic component in a patient suspected of having Behçet disease.

In fact, among young patients, it is one of the most recognized cardiac presentations of this disease (10-11). In some cases, it may precede the diagnosis of the disease (12). The exact pathophysiological mechanism of thrombus formation in these patients is still unknown. In most cases, the histologic description of the thrombus and the underlying myocardium suggests an inflammatory process with a dominant mononuclear cell infiltrate. On the other hand, in some cases, the biopsy findings included endomyocardial fibrosis or normal myocardium. An elevated erythrocyte sedimentation rate, C-reactive protein, antiphospholipid antibody, endothelin I antibody, and von Willebrand factor rather support an autoimmune and inflammatory theory (13).

To this day, there are no guidelines or randomized controlled trials that codify the treatment of cardiac involvement in Behçet's disease. We therefore have access only to data from published clinical cases based on the experience of other centers. Several treatments have been used, including colchicin, corticosteroids, immunosuppressants (azathioprine and cyclophosphamide), and immunomodulators. Anticoagulants can be added provided that the general bleeding risk is low and the presence of possible arterial aneurysms is eliminated.

In our case, the initial therapeutic management including anticoagulant alone failed, as indicated by the stationary aspect of the thrombus. Regression of the thrombus size was achieved only after the addition of specific therapy including corticosteroid therapy and immunosuppressants. This consolidates cases reported in the literature, in which anticoagulation alone failed to promote regression or resolution of these masses, being possible only after the introduction of

immunosuppressive therapy (12-13-14). In addition, as other cases have shown, cardiac surgery is not recommended because of the high rates of recurrence and embolization (15).

This case illustrates the diagnostic difficulty in the intracardiac mass in young patients, because the presentation of vasculitis is frustrating. The multidisciplinary approach including clinical discussion between cardiologists, radiologists, cardiac surgeons, and internists was crucial to recognize the final diagnosis to ensure better management. Glucocorticoids and immunosuppressants remain a cornerstone in the treatment of vascular involvement in Behçet's disease, as they reduce the relapse rate and prolong survival.

#### IV. CONCLUSION:

Intracardiac thrombi are a very rare manifestation of Behçet's disease that should be evoked in front of any intracardiac mass occurring in a young subject. Their treatment is classically based on immunosuppressive agents, corticoids and anticoagulants. Surgical treatment of intracardiac thrombus is generally not recommended. Further studies are needed to guide the management of vascular involvement and other life-threatening complications of Behçet's disease.

#### **Ethical Approval:**

As per international standard or university standard written ethical approval has been collected and preserved by the author(s).

#### **Consent**

As per international standard or university standard, patient(s) written consent has been collected and preserved by the author(s).

#### V. Reference :

- (1). F. Davatchi, M. Schirmer, C. Zouboulis, S. Assad Khalil, T. Calamia. Validation of the international criteria for Behçet's disease (ICBD) in Iran. *Int J Rheum Dis* 2010;13:55-60.
- (2). Baykan M, Celik S, Erdöl C, Baykan EC, Durmus I, Bahadir S *et al.* Behçet's disease with a large intracardiac thrombus: a case report. *Heart*. 2001 Apr;85(4):E7.
- (3). Wechsler B, Du LT, Kieffer E. Cardiovascular manifestations of Behçet's disease. *Ann Med Interne*. 1999;150(2):542-5
- (4). Ehrlich GE. Vasculitis in Behçet's disease. *Int Rev Immunol*. 1997;14(6):81-8
- (5). Ghorri MA, Sousi AA, Mahmeed WA, Ellahham S, Ayman M, Augustin N. A case report of a right ventricular mass in a patient with Behçet's disease: myxoma or thrombus? *J Saudi Heart Assoc* 2013;25:85-89.
- (6). M. Guerhazi, O. Ketata, A. Derbel, J. Awa, M. Snoussi, C. Damak, R. Ben Salah, F. Frikha, S. Marzouk, Z. Bahloul,. Thrombose intracardiaque au cours de la maladie de Behçet: expérience d'un service de médecine interne à travers 5 cas. *La Revue de Médecine Interne*, 2021
- (7).Mogulkoc N, Burgess MI, Bishop PW.

Intracardiac thrombus in Behçet's disease: a systematic review. *Chest*. 2000;118(2):479-87.

(8). Mouhebati M, Rohani A. Right ventricular mass: a tumor or thrombus. *Heart India* 2016;4:70–71.

(9). Pradella S, Grazzini G, Letteriello M, De Amicis C, Grassi R, et al. Masses in right side of the heart: spectrum of imaging findings. *Acta Biomed*. 2020 Jul 13;91(8-S):60-70. doi: 10.23750/abm.v91i8-S.9940. PMID: 32945280; PMCID: PMC7944673.

(10). El Louali F, Tamdy A, Soufiani A, Oukerraj L, Omari D, Bounjoum F et al. Cardiac thrombosis as a manifestation of Behçet syndrome. *Texas Hear Inst J* 2010;37:568–571.

(11). Yetkin E, Ozturk S. Cardiac complications in Behçet's disease. *Ultrasound Med Biol* 2018;44:2165–2166.

(12). Farouk H, Zayed HS, El-Chilali K. Cardiac findings in patients with Behçet's disease: facts and controversies. *Anatol J Cardiol* 2016;16:529–533.

(13). Ghori MA, Al Sousi A, Al Mahmeed W, Ellahham S, Ayman M, Augustin N. A case report of a right ventricular mass in a patient with Behçet's disease: Myxoma or thrombus? *J Saudi Heart Assoc*. 2013 Apr;25(2):85-9. doi: 10.1016/j.jsha.2013.02.001. Epub 2013 Feb 18. PMID: 24174852; PMCID: PMC3809470.

(14). Briosa A, Gomes AC, CastelBranco A, Cunha M, Sousa S, Almeida AR, Calhau P, Pereira H. Behçet's disease: a case report about a rare cause of intra-cardiac mass. *Eur Heart J Case Rep*. 2021 Oct 8;5(10):ytab299. doi: 10.1093/ehjcr/ytab299. PMID: 34632262; PMCID: PMC8497885

(15). Abidov A, Alpert JS. Importance of echocardiographic findings in the acute presentation of Behçet's disease - diagnostic and prognostic considerations. *Echocardiography* 2014;31:913–915.