

Case study

Kjer's disease :case report

Abstract

Dominant optic atrophy (DOA) or Kjer's disease, caused by mutations in the OPA1 gene, is an autosomal dominant inherited pathology due to degeneration of retinal ganglion cells leading to loss of optic nerve axons. It manifests itself in atrophy of the optic nerve head, which, together with the decrease in visual acuity, alteration of the visual field and dyschromatopsia, is one of the essential elements of the diagnosis. Its molecular diagnosis (OPA1 genes in 60% of cases) allows nowadays an informed genetic counselling in the majority of cases. This disease is associated with the susceptibility of retinal ganglion cells to mitochondrial deficits, particularly affecting the respiratory chain, mitochondrial network dynamics, mitochondrial control of apoptosis, and inner membrane patterning. These molecular abnormalities underlie pathophysiological mechanisms, knowledge of which opens potential therapeutic opportunities (neuroprotectors, antioxidants, gene therapy).

Case presentation:

The 22-year-old patient has experienced progressive bilateral visual acuity loss since childhood. Ophthalmologic examination showed bilateral temporal papilledema atrophy. The diagnosis of Dominant optic atrophy was confirmed through genetic testing, which detected the OPA1 gene mutation in the patient, as well as her father and grandmother.

Conclusion:

Despite ongoing research efforts to improve the characterization of the disease, Dominant optic atrophy remains a rare condition that is often not diagnosed promptly. The development of therapies for the disease is dependent on gaining a better understanding of it.

Keywords: dominant optic atrophy, autosomal, retinal ganglion cells, dyschromatopsia, visual field defect, OPA1 gene

Introduction

Dominant optic atrophy is a neuro-ophthalmologic disease characterized by bilateral degeneration of the optic nerves leading to gradual visual loss that usually begins in the first decade of life. The disease mainly affects the retinal ganglion cells and their axons, which form the optic nerve. The purpose of this case report of a young patient with dominant optic atrophy is to describe the characteristic genetic and clinical aspects of the disease.

Clinical case

The patient is 22 years old and has had progressive bilateral visual acuity loss since early childhood. In her medical history, her father and paternal grandmother had visual loss that had not been previously investigated. Ophthalmologic examination revealed visual acuity of 3/10, P4 for both eyes. The examination of the anterior segment was without abnormalities in both eyes Goldmann applanation tonometry revealed intraocular pressure of 12 mmHg in both eyes Fundus showed bilateral temporal papilledema atrophy with normal macular appearance

(Figure 1) Optical coherence tomography (OCT) of both eyes confirmed bilateral temporal sectoral atrophy. (Figure 2) Visual field showed bilateral cacocentral scotoma. (Figure 3)

Color vision test showed dyschromatopsia on the blue-yellow axis. Audiometry revealed severe bilateral sensorineural hearing loss. The diagnosis was confirmed by genetic testing,

which detected the mutation of the OPA1 gene in the patient as well as in her father and grandmother. It was decided not to treat the patient. The family was referred for genetic

counseling and outpatient follow-up.

Discussion

The first observations of dominantly transmitted optic neuropathy were reported in the late 19th century [1, 2]. In the late nineteenth century [1, 2]. Large families were then described in

Comment [ND1]: Include macular ganglion cell analysis as well

Comment [ND2]: Correct spelling mistake

Comment [ND3]: Include pedigree chart if possible

the United Kingdom [3], the United States [4], and France [5], but it was the Danish ophthalmologist Kjer who, in 1959, demonstrated the existence of a special entity bearing his name by describing 19 families with dominantly transmitted optic atrophy [6]. Autosomal dominant optic atrophy (AODA) is the most common inherited optic neuropathy with an estimated prevalence of 1/12,000 to 1/50,000. Dominant optic atrophy is usually associated with mutations in the OPA1 nuclear gene, located on chromosome 3, region q28-q29. The OPA1 gene encodes a dynamin-related protein GTPase that targets the mitochondrial inner membrane [7-9]. Although the mechanism of action of the OPA1 gene product is unknown, it is likely involved in stabilising mitochondrial membrane complexes. Mitochondria are subcellular structures that generate and convert metabolic energy into discrete usable units (ATP) for cellular functions. Retinal ganglion cells, whose axons form the optic nerve, have high energy requirements and are particularly susceptible to mitochondrial dysfunction. This is especially true for smaller, less myelinated neurons such as those in the papillomacular bundle of the retina, which transmit information for the central visual field. The typical onset of reduced visual acuity is in the first or second decade of life, although most patients cannot identify a specific onset of reduced visual acuity because of its progressive course. This visual loss is usually bilateral and relatively symmetrical and progresses slowly and insidiously. Optic disc atrophy is usually focal temporal wedge-shaped, but diffuse atrophy may be present. Because the primary pathology is the papillomacular bundle, central, **centrocerebral**, and paracentral scotomas are the most common visual field abnormalities. Dyschromatopsia commonly occurs in the blue-yellow axis, but also in the red-green axis. **Visual evoked responses in affected individuals show decreased amplitudes and prolonged latencies.** **Electroretinogram show a reduced N95 component [8].** Some carriers of the optic atrophy 1 mutation experience hearing loss, peripheral neuropathy, myopathy, ataxia, and chronic progressive external ophthalmoplegia [10-12]. There is no established medical treatment for

Comment [ND4]: Check for spelling mistake

Comment [ND5]: Was any electrophysiological test done for the patient ?

AODA. It is considered one of the two classical paradigms of mitochondrial dysfunction in optic neuropathies (the other being Leber's hereditary optic neuropathy). Coenzyme Q-10 (CoQ), idebenone, and dietary supplements such as vitamins B12 and C and lutein have been reported to reduce oxidative stress in the optic nerve [13]. Topical agents known to be neuroprotective or anti-apoptotic, such as brimonidine, have also been recommended, although evidence for their efficacy is anecdotal [13]. Annual examinations of visual acuity, visual fields, color vision, extraocular muscles, and hearing are recommended after the diagnosis of AODA [14]. The differential diagnosis of the disease also includes other diseases that cause optic atrophy, including hereditary Leber optic neuropathy, toxic optic neuropathy, and normal tension glaucoma [16, 17].

Conclusion

Dominant optic atrophy is a rare disease that remains underdiagnosed today. Research continues to better characterize the disease so that therapies can be developed.

References

1. Kjer P: Infantile optic atrophy with dominant mode of inheritance: a clinical and genetic study of 19 Danish families. *Acta Ophthalmol Suppl* 1959, 164(Supp 54):1–147.
2. Taban M, Cohen BH, David Rothner A, Traboulsi EI: Association of optic nerve hypoplasia with mitochondrial cytopathies. *J Child Neurol* 2006, 21 (11):956–960.
3. Delettre C, Lenaers G, Pelloquin L, Belenguer P, Hamel CP: OPA1 (Kjer type) dominant optic atrophy: a novel mitochondrial disease. *Mol Genet Metab* 2002, 75(2):97–107.
4. Amati-Bonneau P, Milea D, Bonneau D, Chevrollier A, Ferre M, Guillet V, Gueguen N, Loiseau D, de Crescenzo MA, Verny C, et al: OPA1-associated disorders: phenotypes and pathophysiology. *Int J Biochem Cell Biol* 2009, 41(10):1855–1865.

5. Thiselton DL, Alexander C, Taanman JW, Brooks S, Rosenberg T, Eiberg H, Andreasson S, Van Regemorter N, Munier FL, Moore AT, et al: A comprehensive survey of mutations in the OPA1 gene in patients with autosomal dominant optic atrophy. *Invest Ophthalmol Vis Sci* 2002, 43 (6):1715–1724.
6. Yu-Wai-Man P, Griffiths PG, Burke A, Sellar PW, Clarke MP, Gnanaraj L, AhKine D, Hudson G, Czermin B, Taylor RW, et al: The prevalence and natural history of dominant optic atrophy due to OPA1 mutations. *Ophthalmology* 2010, 117(8):1531–1546.
7. Newman NJ. Hereditary Optic Neuropathies: from the mitochondria to the optic nerve. *Am J Ophthalmol*. 2005;140(3):517-523.
8. Kline LB, Glaser JS. Dominant optic atrophy: The clinical profile. *Arch Ophthalmol*. 1979 ;97(9):245-251.
9. Delettre C, Lenaers G, Pelloquin L, Belenguer P, Hamel CP. OPA1 (Kjer type) dominant optic atrophy: a novel mitochondrial disease. *Mol Genet Metab*. 2002;75(2):97-107.
10. Chun BY, Rizzo JF 3rd. Dominant Optic Atrophy and Leber's Hereditary Optic Neuropathy: Update on Clinical Features and Current Therapeutic Approaches. *Semin Pediatr Neurol*. 2017 May;24(2):129-134.
11. Yu-Wai-Man P, Votruba M, Moore AT, Chinnery PF. Treatment strategies for inherited optic neuropathies: past, present and future. *Eye (Lond)*. 2014 May;28(5):521-37.
12. Skidd PM, Lessell S, Cestari DM. Autosomal dominant hereditary optic neuropathy (ADOA): a review of the genetics and clinical manifestations of ADOA and ADOA+. *Semin Ophthalmol*. 2013 Sep-Nov;28(5-6):422-6.
13. Carelli V, La Morgia C, Sadun AA. Mitochondrial dysfunction in optic neuropathies: animal models and therapeutic options. *Curr Opin Neurol*. 2013;26(1):52-58.

14. Ham M, Han J, Osann K, Smith M, Kimonis V. Meta-analysis of genotype-phenotype analysis of OPA1 mutations in autosomal dominant optic atrophy. Mitochondrion. 2019 May;46:262-269.

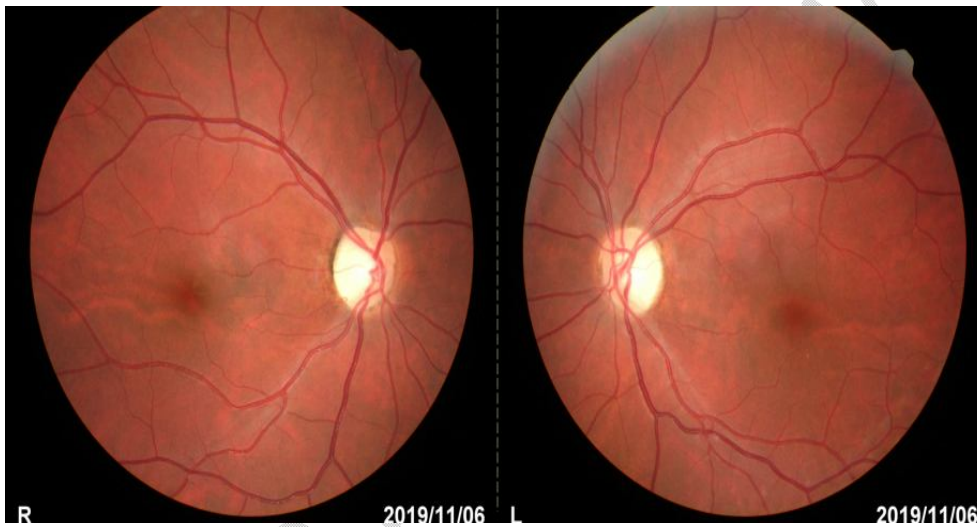


Figure 1. Retinography of both eyes with bilateral temporal sectoral atrophy with normal macular appearance.

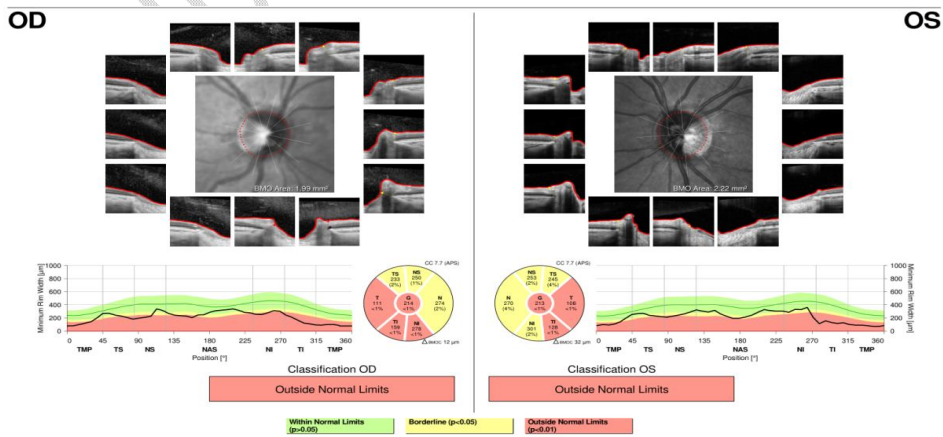


Figure 2: Papillary OCT (Optical coherence tomography) showing bilateral temporal sectoral atrophy.

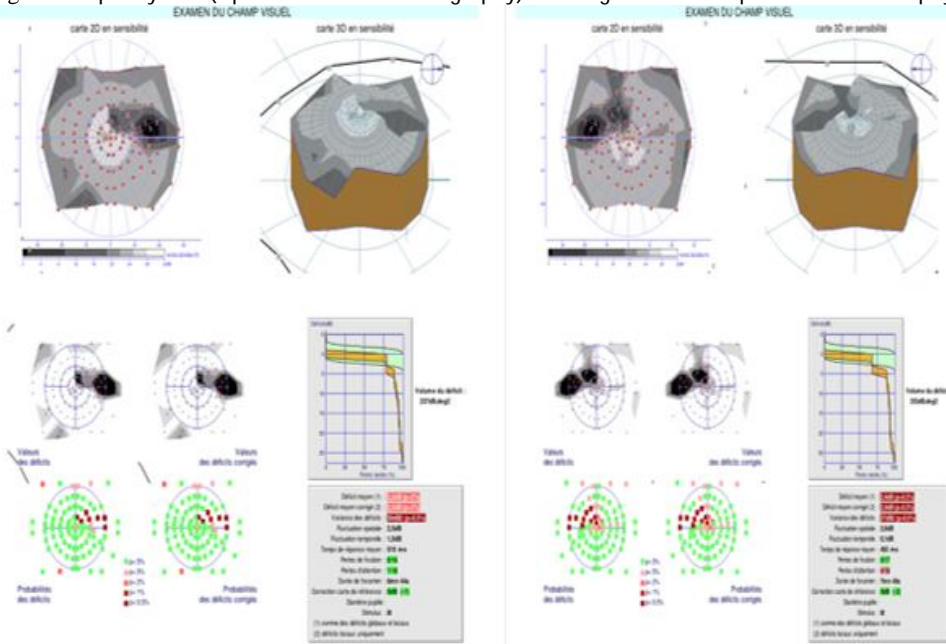


Figure3: Visual field showing bilateral caeco-central scotoma.