

## **A Case series on COVID-19 associated mucormycosis (CAM) : Experience from a tertiary care centre in India**

### **Abstract**

**Aim:** During the second wave of the COVID 19 pandemic, a life threatening fungal infection, mucormycosis have been detected in patients post COVID 19 disease. Commonly known as the 'black fungus' can causes tissue necrosis, inflammation and necrosis of the head and neck regions, paranasal sinuses, facial bones, orbits and it can also cause intracranial spread. In the current study we describe a series of cases of COVID 19 associated mucormycosis (CAM), the clinical presentations, risk factors, diagnosis, management and follow up experience from a tertiary care centre in India.

**Methods:** This is a retrospective observational study conducted over a period of one year (April 2021 to April 2022) at our tertiary care centre. The diagnosis of COVID 19 was done by RT PCR (reverse transcription-polymerase chain reaction). The diagnosis of Mucormycosis was done by Histopathology and fungal cultures. The demographic details of the patients were retrieved from the medical records.

**Results:** In the present study we report four cases of Rhino-orbital-cerebral Mucormycosis, three cases of Rhino-orbital Mucormycosis, two cases of Pulmonary Mucormycosis and one case of Disseminated Mucormycosis. All the patients had undergone extensive surgical debridement and received Liposomal Amphotericin B as initial antifungal medication and Posaconazole or Isavuconazole as step down therapy. Six patients responded to treatment while four patients did not have a favorable outcome and succumbed to the illness.

**Conclusion:** Mucormycosis is a deadly disease with high mortality and morbidity if not diagnosed and treated at an early stage. Factors like poor control of blood sugars, inadvertent use of corticosteroids, immune dysfunction due to COVID 19 can result in poor outcome of the disease despite aggressive treatment interventions.

**Key words:** COVID-19, SARS COV2, Mucormycosis, Aspergillosis, Co infections

### **Introduction**

The pandemic caused by Corona virus disease 2019 (COVID19) continues to be a global concern worldwide. The clinical features of COVID 19 is varied, ranging from being asymptomatic to severe illness requiring prolonged hospitalization and ventilator support in the intensive care unit (ICU) (1,2). Studies have shown that in patients hospitalized due to COVID 19 around 8% may develop associated secondary bacterial or fungal infections (3,4). There was a surge of fungal infections like Mucormycosis and Aspergillosis in people with COVID 19 during the second wave of the COVID 19 pandemic. Mucormycosis is an opportunistic fungal infection caused by a group of moulds called as Mucormycetes (5,6). Although Mucormycosis has been reported in apparently immunocompetent hosts, it can cause devastating effects in immunocompromised individuals in the setting of uncontrolled diabetes, septic shock, multiple organ dysfunction, hematological malignancies, HIV, organ transplantation, iron overload, corticosteroid therapy, chronic kidney disease, chronic alcoholism, previous parenchymal lung disease, skin damage due to burns or trauma and prolonged hospital stay (7). The disease occurs due to the inhalation of spores in the environment, thereby causing infection in the paranasal sinuses and lungs. The other routes for the acquisition of disease include traumatic inoculation, ingestion or by direct contact. The fungus invades the vascular lamina causing inflammation along with necrosis and infarction. Based on the organ involved it is classified as rhino-orbital cerebral, pulmonary, cutaneous, gastrointestinal and disseminated type (8). The diagnosis is made by early clinical suspicion, imaging studies like computational tomography (CT), magnetic resonance imaging (MRI) of the affected organs. Definitive diagnosis is done by microbiology fungal cultures and histopathological features from biopsies (9). The objective of the study is to discuss our experience in diagnosing, studying treatment outcomes and follow up of the patients with CAM.

## Materials and Methods

This is a retrospective observational study design conducted over a period of one year (April 2021 to April 2022) at our tertiary care centre. The diagnosis of COVID 19 was done by RT PCR (reverse transcription-polymerase chain reaction) from oropharyngeal or nasopharyngeal swabs or bronchoalveolar lavage specimens. The diagnosis of Mucormycosis was made by characteristic histological features in tissue biopsy specimens and fungal culture using Sabouraud dextrose agar (SDA) and Potato Dextrose Agar (PDA), slide culture technique and lacto phenol cotton blue preparation (LPCB) for identification up-to species level. Specimens like tissue biopsy, pus which showed fungal hyphae in 10% potassium hydroxide (KOH) preparation were included in the study. Patient demographic details such as age, sex, co morbid illnesses, diagnosis at presentation, previous or current COVID 19 infection, laboratory investigations (including microbiology, histopathology and radiological investigations), management of Mucormycosis and outcome were collected from patient's medical records.

## Results:

During the study period ten patients were diagnosed to have Mucormycosis. Four Rhino-orbital cerebral Mucormycosis, three Rhino orbital Mucormycosis, two pulmonary Mucormycosis and one patient had disseminated Mucormycosis. Eight of them were males and two were females with median age of 43.6 years. Majority of the patients (9 out of 10) had diabetes mellitus as a risk factor. Among the ten patients, four had severe COVID 19 disease, three required mechanical ventilation. Three patients had moderate COVID 19 disease and rest of them had a mild disease. Eight of them had received significant doses of steroids via intravenous (IV) or oral route for the management COVID 19. Five of them had received antiviral medications (Remdisivir 200mg IV stat followed by 100mg IV OD) for COVID 19. None of the patients had any records for COVID 19 vaccination and hence were presumed as not vaccinated. All patients had received both empiric and definitive broad spectrum antibiotics during the course of hospital stay.

The mean time interval between Covid 19 diagnosis to appearance of first symptom of Mucormycosis was  $20.5 \pm 5.6$  days. The common clinical features of patients with Rhino-orbital cerebral Mucormycosis were proptosis, orbital pain, swelling, visual disturbances and epiphora. Other signs included maxillary sinuses tenderness, facial weakness with hemi paresis, and trigeminal neuralgia with involvement of 2<sup>nd</sup> to 6<sup>th</sup> cranial nerves. All patients had proven Mucormycosis either with positive fungal stain, fungal culture or histopathological evidence such as presence of aseptate fungal hyphae, angio-invasion or infarction with necrosis. Among the ten patients, eight had aseptate hyphae on KOH mount preparation and six had growth on fungus cultures. Out of the six, four were found to be *Rhizopus arrhizus*, one was *Aspergillus flavus* and one could not be speciated. Five patients had bacterial co infection (*Citrobacter koseri*, *Pseudomonas aeruginosa*, *Enterococcus* species, *Klebsiella pneumoniae*, *Escherichia coli*) and one patient had co infection with *Rhizopus arrhizus* and *Aspergillus flavus*. All patients underwent surgical intervention. All patients were started on Liposomal Amphotericin B during the initial phase and stepped down to Posaconazole or Isavuconazole. Three patients had nephrotoxicity to Liposomal Amphotericin B and hence needed early switch to other agents. Four patients succumbed to the disease despite the treatment due to involvement of the central nervous system, extensive disease in the lungs, disseminated disease leading to Multiple Organ Dysfunction Syndrome (MODS). The clinical features, histopathology, microbiology and radiological findings of CAM are summarized in table 1. The treatment aspects and outcomes of CAM are described in table 2. The spectrum of CAM is depicted in figure 1. Nine months follow up details of all the six patients who survived was obtained. It was noted that patient 1 had a bone sequestrum picked up on an orthopantamogram 2 months later during the follow up visit. He required further debridement as the KOH stain was positive for aseptate hyphae. Hence antifungal therapy was prolonged. Patient 8 developed bone flap osteomyelitis with ESBL

*Escherichia coli* (*E.coli*) infection 9 months later, requiring removal of bone flap and IV antibiotics for 2 weeks.

**Table 1: Clinical features, Histopathology, Microbiology and Radiological findings of CAM**

Patient Number	Age/sex	Clinical features of Mucormycosis	Co morbid illness	Extent of Mucormycosis	Severity of Covid 19	Mechanical ventilation	Use of steroids	Histopathological evidence of mucorales	Microbiological diagnosis	Radiological findings
1	62/M	Diplopia, epiphora, conjunctival edema, right orbital and maxillary cellulitis, visual disturbances	Diabetes Mellitus	Rhino orbital mucormycosis	Severe	No	Yes	Yes	KOH: Moderate aseptate hyphae Culture: <i>Rhizopus arrhizus</i> , <i>Aspergillus flavus</i> and <i>Enterococcus</i> species.	Pansinusitis with right orbital invasion
2	27/M	Pain over the abdomen and right gluteal region, seizures	Thrombocytopenia, coagulopathy, oliguria, lactic acidosis, acute kidney injury, septic shock and elevated transaminitis	Disseminated mucormycosis	Moderate	No	Yes	Yes	KOH: Few aseptate hyphae Culture: <i>Rhizopus arrhizus</i> .	Right renal infarction with diffuse circumferential wall thickening seen at the caecum, ascending colon, hepatic flexure
3	40/M	Proptosis of left eye, breathing difficulty, epiphora	Diabetes mellitus	Rhino orbital mucormycosis	Severe	Yes	Yes	Yes	KOH: Few aseptate hyphae Culture: <i>Rhizopus arrhizus</i> .	Maxillary, frontal, sphenoid sinusitis with left orbital invasion
4	33/M	Giddiness and altered sensorium, difficulty in breathing	Diabetes Mellitus	Rhino orbital cerebral mucormycosis	Severe	Yes	Yes	Yes	KOH: Few aseptate hyphae Culture: <i>Aspergillus flavus</i>	Maxillary and sphenoid sinusitis with CNS involvement (ACA infarct with bilateral frontal lobe changes)
5	47/M	Right side weakness (Right side hemiparesis, Right facial palsy) and seizures	Diabetes Mellitus	Rhino orbital cerebral mucormycosis	Moderate	No	Yes	Yes	KOH: Few aseptate hyphae Culture: ESBL <i>Klebsiella pneumoniae</i>	Ethmoidal sinusitis, maxillary sinusitis with CNS involvement (stable lesion left cerebral hemisphere, mass effect with midline shift 9mm to right side)

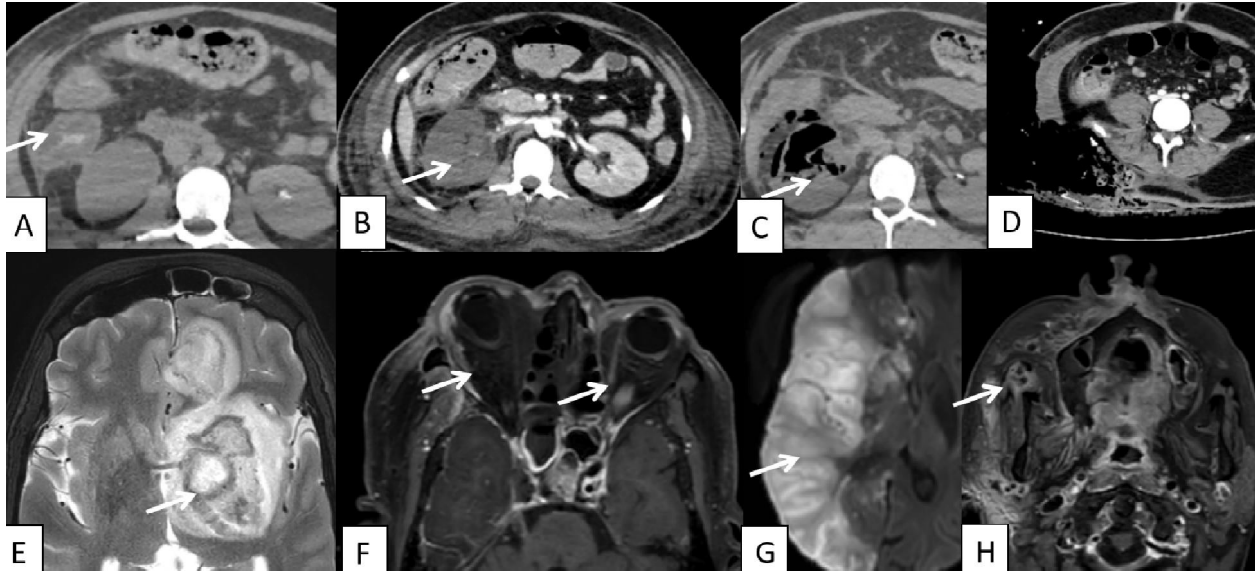
6	59/M	Pain over the left maxillary region and cheek swelling	Diabetes mellitus	Rhino orbital mucormycosis	Mild	No	No	Yes	KOH: Few septate hyphae and occasional aseptate hyphae Culture: <i>Citrobacter koseri</i>	Left maxillary sinusitis with involvement of left buccal space
7	58/M	Wet cough, breathlessness and chest pain	Diabetes mellitus	Pulmonary mucormycosis	Severe	Yes	Yes	Yes	KOH: Negative Culture: No growth	Multiple areas of consolidation in bilateral lung fields, pneumothorax and mild pleural effusion left lung, left lung collapse, pneumomediastinum with gross diffuse emphysematous changes in chest wall.
8	41/M	Right temporal and trigeminal pain	Diabetes mellitus	Rhino orbital cerebral mucormycosis	Mild	No	Yes	Yes	KOH: Few aseptate hyphae Culture: ESBL <i>Escherichia coli</i>	Pansinusitis with involvement of temporal lobe, cavernous sinus, skull base osteomyelitis, 2-6 Cranial nerve and internal carotid artery involvement and right orbital invasion
9	69/F	Right orbital pain and swelling	Diabetes mellitus, acute Kidney Injury, acute Coronary syndrome with severe LV dysfunction	Rhino orbital cerebral mucormycosis	Mild	No	No	Yes	KOH: Many aseptate hyphae Culture: <i>Rhizopus arrhizus</i> and <i>Pseudomonas aeruginosa</i>	Extensive acute infarct at right MCA –ACA territory involving right frontotemporoparietal occipital lobe, right insula, basal ganglia, right cavernous sinus involvement, right ICA thrombosis
10	49/F	Cough with blood tinged expectorant	Diabetes mellitus, Hypertension, hypertensive retinal neuropathy, acute kidney injury	Pulmonary mucormycosis	Moderate	No	Yes	Yes	KOH: Negative Culture: Mucorales(unspecific)	Pseudoaneurysm right descending pulmonary artery and posterior basal segment artery

**Table 2: Management and treatment outcomes of CAM**

Patient number	Surgery	Antifungal Medications	Outcome	Follow up at nine months
1	Transnasal endoscopic debridement and rhino orbital decompression, denkers approach	Liposomal Amphotericin B 5mg/kg, 13 days, Posaconazole for 9 months	Discharged	Patient had a bone sequestrum picked up on a orthopantomogram 2 months later during the follow up visit. He required further debridement

				as the KOH stain was positive for aseptate hyphae. Antifungal therapy was prolonged.
2	Right hemicolectomy, right nephrectomy with adrenalectomy and multiple peritoneal biopsies.	Liposomal Amphotericin 10mg/kg, 15 days	Died	-
3	Left medial maxillectomy + Functional endoscopic sinus surgery (FESS) and debridement	Liposomal Amphotericin B 5mg/kg, 7 days, Posaconazole 5 months	Discharged	Recovered, No complications so far
4	Bifrontal craniotomy and removal of infected tissue involving Left frontal lobe and Repair of skull base with fat and fascia	Liposomal Amphotericin B 7.5mg/kg, 6 days	Died	-
5	Left fronto temporoparietal decompressive craniectomy and evacuation of thalamic abscess followed by anterior skull base repair with fat, fascia and tisseal	Liposomal Amphotericin B 5mg/kg for 44 days, Posaconazole 6 months	Discharged	Recovered, No complications so far
6	Middle meatal antrostomy on left side, FESS debridement	Liposomal Amphotericin B 10mg/kg for 15 days, Isavuconazole for 4 months	Discharged	Recovered, No complications so far
7	Left thoracotomy, wedge resection of segment 6 and inferior lingular Segment	Liposomal Amphotericin B 10mg/kg for 4 days	Died	-
8	Functional endoscopic sinus surgery multiple times, endoscopic endonasal approach and radical debridement	Liposomal Amphotericin B 5mg/kg for 15 days, Isavuconazole for 3 months	Discharged	Developed bone flap osteomyelitis with ESBL <i>E.coli</i> 9 months later, requiring removal of bone flap and IV antibiotics for 2 weeks.
9	Trans nasal endoscopic debridement and tracheostomy, Right fronto temporoparietal decompressive craniotomy	Liposomal Amphotericin B 7.5mg/kg for 5 days, Isavuconazole 1 month	Died	-
10	Right posterolateral non muscle sparing thoracotomy, right middle & lower lung lobectomy	Liposomal Amphotericin B 5mg/kg for 9 days and Isavuconazole for 5 months	Discharged	Recovered, No complications so far

Figure 1: Spectrum of Covid Associated Mucormycosis (CAM)



**(A) Colitis**- Ascending colon thickening in CT abdomen. **(B) Renal infarct**- CT abdomen in arterial phase showed right renal artery occlusion with no contrast uptake of right renal parenchyma. **(C) Emphysematous pyelonephritis** -CT abdomen showing air pockets in right kidney. **(D) Abdominal wall necrosis.** **(E) Cerebral abscess**-MRI Brain (T2 sequence) showing multiple abscess with perilesional edema. **(F) Orbit and Paranasal sinus involvement**- MRI Brain (post contrast T1 sequence) showing non enhancing areas involving both orbits and ethmoidal sinuses classical of mucormycosis. **(G) Cerebral infarct**- Right middle cerebral artery infarct seen as diffusion restriction in DWI MRI sequence. **(H) Face involvement**- MRI (Post contrast T1 sequence) showing involvement of right side face including the masticator space.

## Discussion:

The World Health Organization had declared COVID 19 caused by SARS COV2 as a global pandemic in March 2020. Globally it continues to be a major public health concern with more than 535 million cases being reported and more than 6 million deaths. Following United States, India had ranked second with more than 43 million cases reported from India at the time of writing (10). During the second wave, cases of Mucormycosis were increasingly reported worldwide especially in India (11). The global incidence of Mucormycosis varies between 0.005 to 1.7 per million population, whereas in India the estimated prevalence is 140 per million population which is considered 80 times higher in comparison to the developed countries (12). In the current study we report clinical, histopathological and radiological features of Mucormycosis in patients with COVID 19 admitted to our hospital.

Mucormycosis is one of the most dreadful fungal infections associated with high mortality due to angio-invasion leading to thrombosis, infarction and necrosis of the infected tissues. If not detected and treated early it can disseminate to the adjacent structures resulting in various complications. The most common predisposing factors observed in our study was diabetes mellitus (9/10) followed by exposure to steroids (8/10). Diabetes mellitus and steroid exposure as a major predisposing factor for Mucormycosis have been documented in various other studies as well (1,13,14). The most common etiological agent in our study was *Rhizopus arrhizus* which is similar to other studies published from India (7,13,15,16).

Among the four patients with Rhino-orbital cerebral Mucormycosis, half of them had a favorable outcome at the end of hospitalization, whereas all the three patients with rhino orbital Mucormycosis had a favorable outcome even after 9 months of follow up. This may be attributed to the localized disease at the time of presentation. However factors such as better glycemic control, early and aggressive surgical debridement along with prompt initiation of antifungal agents may have played a significant role in determining overall outcomes of these patients. Multiple case series from India have also showed better survival rates in patients with ROCM treated with a multimodal approach that included surgical intervention along with antifungal therapy (17–19). All the patients had received liposomal Amphotericin B for a mean duration of 13.3 days, one patient had a premature switchover to Amphotericin B deoxycholate due to cost constraints. Three patients had received Posaconazole (oral suspension) and four had received Isavuconazole (Oral) as a step down therapy. Side effects such as nausea, vomiting, altered liver function tests, diarrhea and hypokalemia were not noted for the above drugs.

Among the two patients with pulmonary mucormycosis one had a favorable outcome. The mortality rate of pulmonary mucormycosis is high (50% to 70%) as per literature due to the lack of specific signs and symptoms (20). Specimens like broncho alveolar lavage (BAL) or sputum

rarely gives a confirmatory diagnosis. Invasive samples like lung biopsy or excised tissue is required for a definitive diagnosis (21). One patient was diagnosed to have disseminated mucormycosis. The patient was admitted elsewhere with a skin lesion in the right gluteal region. He has undergone debridement of the lesion which showed necrotizing myositis due to angio-invasive Zygomycosis. He was started on Liposomal Amphotericin B and referred to our hospital for further care. Upon presentation he had septic shock with severe metabolic acidosis with multi-organ dysfunction. As he complained of abdominal pain and hence a CT abdomen was done which showed diffuse circumferential wall thickening at the caecum, ascending colon, hepatic flexure, right renal infarction with new emphysematous changes in the right kidney and perinephric space. He underwent extensive source control involving wound debridement, open nephrectomy, hemicolectomy and ileostomy. His condition remained critical and he continued to deteriorate despite prompt extensive source control, antifungal therapy and supportive measures. He succumbed to his illness. This patient did not have any other traditional risk factors for Mucormycosis apart from the use of systemic corticosteroids for COVID 19 pneumonia. Thus, drugs such as steroids and other immunomodulators that can cause profound immunosuppression warrant judicious use (19).

#### **Limitations of the study:**

Our study has a few limitations. Firstly, it is a retrospective observational study design describing a case series of ten patients only. Secondly, this study was from a single centre and hence may not holistically represent the data from the entire country. However our study is unique as it included only patients with proven CAM and is one of the few case series which describes CAM in detail including long term follow up.

#### **Conclusion:**

To summarize clinicians treating COVID 19 patients with concomitant diabetes mellitus should have a high index of suspicion to diagnose Mucormycosis. The use of corticosteroids as a treatment for COVID 19 is a major predisposing factor for CAM. Multidisciplinary approach involving microbiologist, infectious disease specialist, intensivist, otolaryngologist, surgeons, neurologist and ophthalmologists is necessary to manage these patients. Prompt initiation of antifungal and surgical debridement can improve the survival rate. The use of broad spectrum antibiotics and corticosteroids as treatment for COVID 19 must be cautioned to prevent super added infections in future.

#### **Ethical Approval**

The study was approved by the Institutional Ethics committee – Biomedical research, Apollo Hospitals, Chennai (IEC App No: APH-C-S-005/072022).

## Consent

As this is a retrospective study, waiver of patient's consent was obtained.

## References:

1. Al-Tawfiq JA, Alhumaid S, Alshukairi AN, Temsah MH, Barry M, Al Mutair A, et al. COVID-19 and mucormycosis superinfection: the perfect storm. *Infection*. 2021;49(5):833–53.
2. Farghly Youssif S, Abdelrady MM, Thabet AA, Abdelhamed MA, Gad MOA, Abu-Elfatth AM, et al. COVID-19 associated mucormycosis in Assiut University Hospitals: a multidisciplinary dilemma. *Sci Rep*. 2022 Jun 21;12(1):10494.
3. Arastehfar A, Carvalho A, van de Veerdonk FL, Jenks JD, Koehler P, Krause R, et al. COVID-19 Associated Pulmonary Aspergillosis (CAPA)—From Immunology to Treatment. *J Fungi*. 2020 Jun 24;6(2):91.
4. Rawson TM, Moore LSP, Zhu N, Ranganathan N, Skolimowska K, Gilchrist M, et al. Bacterial and fungal co-infection in individuals with coronavirus: A rapid review to support COVID-19 antimicrobial prescribing. *Clin Infect Dis Off Publ Infect Dis Soc Am*. 2020 May 2;ciaa530.
5. About Mucormycosis | Mucormycosis | CDC [Internet]. 2021 [cited 2022 Jun 14]. Available from: <https://www.cdc.gov/fungal/diseases/mucormycosis/definition.html>
6. Chakrabarti A, Singh R. Mucormycosis in India: unique features. *Mycoses*. 2014;57(s3):85–90.
7. Aranjani JM, Manuel A, Razack HIA, Mathew ST. COVID-19–associated mucormycosis: Evidence-based critical review of an emerging infection burden during the pandemic's second wave in India. *PLoS Negl Trop Dis*. 2021 Nov 18;15(11):e0009921.
8. Rao VUS, Arakeri G, Madikeri G, Shah A, Oeppen RS, Brennan PA. COVID-19 associated mucormycosis (CAM) in India: a formidable challenge. *Br J Oral Maxillofac Surg*. 2021 Nov;59(9):1095–8.
9. Bhattacharyya A, Sarma P, Sharma DJ, Das KK, Kaur H, Prajapat M, et al. Rhino-orbital-cerebral-mucormycosis in COVID-19: A systematic review. *Indian J Pharmacol*. 2021;53(4):317–27.
10. WHO Coronavirus (COVID-19) Dashboard [Internet]. [cited 2022 Jun 20]. Available from: <https://covid19.who.int>
11. Singh AK, Singh R, Joshi SR, Misra A. Mucormycosis in COVID-19: A systematic review of cases reported worldwide and in India. *Diabetes Metab Syndr*. 2021;15(4):102146.
12. Mucormycosis [Internet]. [cited 2022 Jun 21]. Available from: [https://www.who.int/india/emergencies/coronavirus-disease-\(covid-19\)/mucormycosis](https://www.who.int/india/emergencies/coronavirus-disease-(covid-19)/mucormycosis)

13. Pal R, Singh B, Bhadada SK, Banerjee M, Bhogal RS, Hage N, et al. COVID-19-associated mucormycosis: An updated systematic review of literature. *Mycoses*. 2021;64(12):1452–9.
14. Bhatia M. The rise of mucormycosis in Covid-19 patients in India. *Expert Rev Anti Infect Ther*. 2022 Feb 1;20(2):137–8.
15. Sarkar S, Gokhale T, Choudhury SS, Deb AK. COVID-19 and orbital mucormycosis. *Indian J Ophthalmol*. 2021 Apr;69(4):1002–4.
16. Prakash H, Chakrabarti A. Global Epidemiology of Mucormycosis. *J Fungi*. 2019;
17. Chakrabarti A, Das A, Sharma A, Panda N, Das S, Gupta KL, et al. Ten Years' Experience in Zygomycosis at a Tertiary Care Centre in India. *J Infect*. 2001 Jul 1;42(4):261–6.
18. Chakrabarti A, Das A, Mandal J, Shivaprakash MR, George VK, Tarai B, et al. The rising trend of invasive zygomycosis in patients with uncontrolled diabetes mellitus. *Med Mycol*. 2006 Jan;44(4):335–42.
19. Hoenigl M, Seidel D, Carvalho A, Rudramurthy SM, Arastehfar A, Gangneux JP, et al. The emergence of COVID-19 associated mucormycosis: a review of cases from 18 countries. *Lancet Microbe* [Internet]. 2022 Jan 25 [cited 2022 Jun 22];0(0). Available from: [https://www.thelancet.com/journals/lanmic/article/PIIS2666-5247\(21\)00237-8/fulltext](https://www.thelancet.com/journals/lanmic/article/PIIS2666-5247(21)00237-8/fulltext)
20. Krishna V, Bansal N, Morjaria J, Kaul S. COVID-19-Associated Pulmonary Mucormycosis. *J Fungi*. 2022 Jul;8(7):711.
21. Chakrabarti A, Chatterjee SS, Das A, Panda N, Shivaprakash MR, Kaur A, et al. Invasive zygomycosis in India: experience in a tertiary care hospital. *Postgrad Med J*. 2009 Nov 1;85(1009):573–81.

UNDER PEER REVIEW