

## ORAL DESQUAMATIONS OF CLINICAL INTEREST : a report of 2 cases

### ABSTRACT:

In oral medicine, dermatologic diseases have special attention as oral mucosal lesions may be a clinical feature or the only sign of various mucocutaneous diseases. Dentists are often the first to be consulted by patients who develop acutely painful oral ulcerations associated with these mucocutaneous lesions, and this could be neglected by dentists due to a lack of information and/or an improper diagnosis, leading to a significant deterioration in the quality of life of patients. This present article describes two variants of vesiculobullous lesions with a brief review, as they are a distinct group of oral disorders characterised by formations of vesicles or bullae. The dental practitioner attempting to diagnose the oral ulcers and lesions is often confronted with several diseases having similar and identical clinical appearances. Also, the clinical identification of intact vesicles and bullae in the oral cavity is really a challenge due to regular irritation and the friable nature of the oral mucosa, which makes the diagnosis of vesiculobullous lesions even more difficult as the differential diagnosis of the disease also includes ulcerative, immunological, neoplastic, and systemic diseases. So, here we present two diagnosed cases of vesiculobullous lesions affecting middle aged women who presented with an overlapping clinical presentation and a varying etiological factor. They were discussed with the aim of making a closer attempt to understand their clinical presentation, pathogenesis, diagnostic criteria, and early, effective management protocols for a better prognosis.

**Keywords:** vesiculobullous diseases, oral mucosa, Pemphigus vulgaris, mucous membrane pemphigoid, case report.

## INTRODUCTION

“Oral mucosa is often affected by many mucocutaneous autoimmune diseases, which have varied clinical presentations, most of which overlap one another. Among those, vesiculobullous diseases represent a heterogeneous group of dermatoses with widely varying clinical manifestations, which have been the subject of an increase in prevalence rates in recent years. Although in the majority of cases these diseases are characterised primarily by the presence of vesiculobullous lesions, their aetiology, pathogenesis, severity, and trajectory may differ”<sup>[1]</sup>. “These include common Pemphigus or Pemphigus vulgaris, paraneoplastic Pemphigus and benign mucous membrane pemphigoid which, clinically, are very similar when present in the oral mucosa”<sup>[2]</sup>. “Due to the varied nature of these diseases, it becomes quite difficult to arrive at an early diagnosis, which ultimately can have a big impact on individuals’ quality of life, influencing their social lives, as well as their physical and psychological well-being”.<sup>[3]</sup> To manage these patients’ early diagnoses is of prime importance and which are purely based on past history, clinical presentation and a proper selection of investigations.

“Among the vesiculobullous diseases, Pemphigus vulgaris (PV) and Benign mucous membrane pemphigoid (BMMP) are prominent, and are characterised by the production of autoantibodies that are directed towards the constituents responsible for the adhesion of the epithelial cells to each other. Thus, this antigen-antibody reaction results in a pathological process clinically characterised by the appearance of blisters or vesicles on the skin and/or mucosal surfaces”<sup>[4, 5]</sup>.

**Case 1:** A 42-year-old female patient reported to the department of oral medicine and radiology with the chief complaint of presence of burning sensation and bleeding from the gums for the past 3 weeks, for which she gives a history of aggravation of symptoms during brushing and mastication. Patient gives history of same symptoms before 1 year for which she was treated by a private practitioner and on which the given concern regressed, but patient was not aware of medication given. A review of medical and family history was non-contributory. Her extraoral examination revealed the presence of ruptured vesicles in the forearm and hands, for which the patient gave a history of vesicle formation before 3 days, which ruptured on their own, leaving a scarred surface [Figures 1 (a and b)]. Her intraoral examination revealed the presence of generalised erythematous, inflamed marginal and attached gingiva with generalised loss of contour and stippling and blunt interdental papillae

with interspersed areas of desquamation. On palpation, it is tender and soft in consistency, with evidence of bleeding and a positive nikolsky sign. On right and left buccal mucosa, the presence of diffuse erythematous and erosive areas interspersed with greyish-white linear striae seen extending from the commissural area till the retromolar region was evident. On palpation, it is tender with no evidence of bleeding [Figure 2]. Based on history and clinical examination, a provisional diagnosis of desquamative gingivitis suggestive of Pemphigus in the right and left buccal mucosa was considered and a differential diagnosis of plasma cell gingivitis, lichen planus and pemphigoid were included. The patient was subjected to blood investigations prior to biopsy, which revealed all the blood parameters were within normal range. The two tissue specimens from the perilesional biopsy of gingiva were obtained for histopathological examination and direct immunofluorescence. Her histopathological investigation revealed the presence of flattened rete-pegs and subepithelial splits at the basement membrane with a band of lymphoplasmacytic infiltration [Figure 3]. Her direct immunofluorescence study revealed the absence of all conjugates which might be due to loss of immunoreactants in longstanding lesions, which gives a false-negative interpretation. Based on history, clinical presentation and investigations, a final diagnosis of autoimmune disorder of the skin and oral cavity suggestive of mucous membrane pemphigoid was given. The patient was treated with prednisolone 10 mg twice daily for 14 days, then the dosage was tapered to once daily for 10 days, and gradually the dosage was reduced. The lesions in the skin as well as the oral cavity showed a reduction in severity in the fourth week follow-up, with no remission of lesions to date [Figure 4].

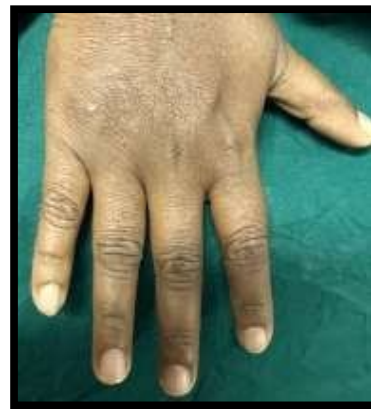
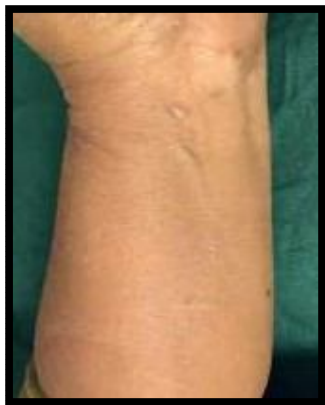
Figure 1 [ a and b]: skin lesions on hands

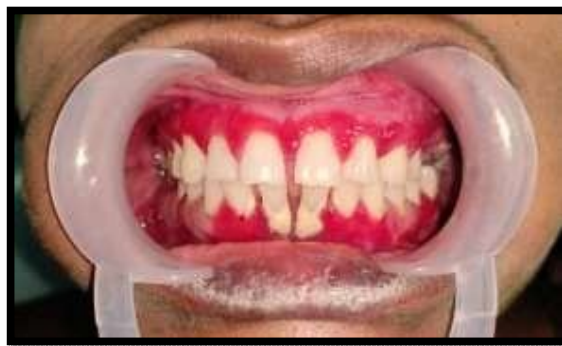
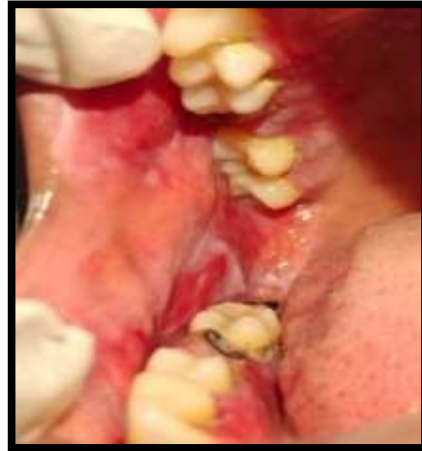
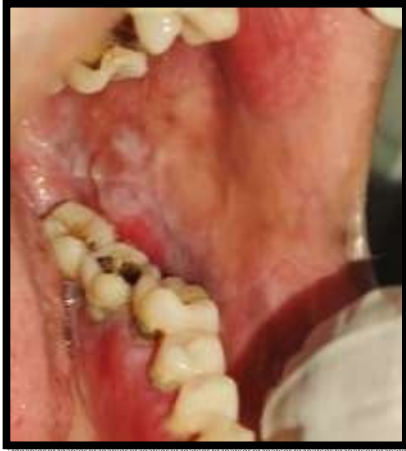Figure 2 [a, b and c]: a (ulcerative surfaces seen on right buccal mucosa), b (ulcerative surfaces seen on left buccal mucosa) and c (desquamative gingivitis)

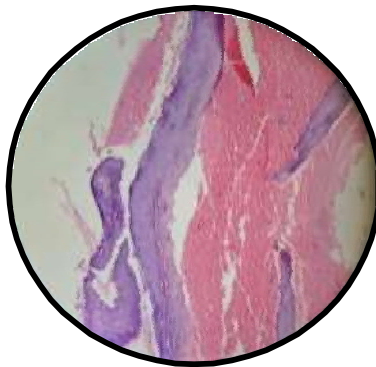


Figure 3: Haematoxylin and eosin (H&E) stained section showed subepithelial split at BMZ with lymphocyte infiltration

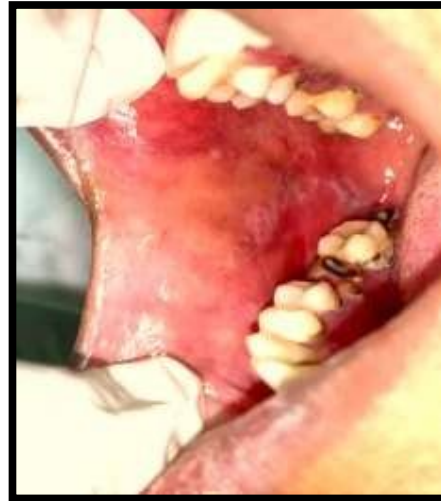
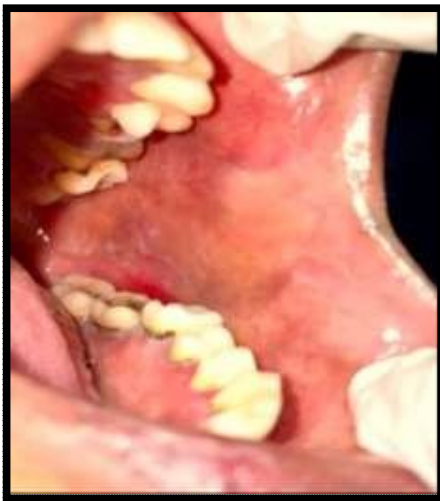
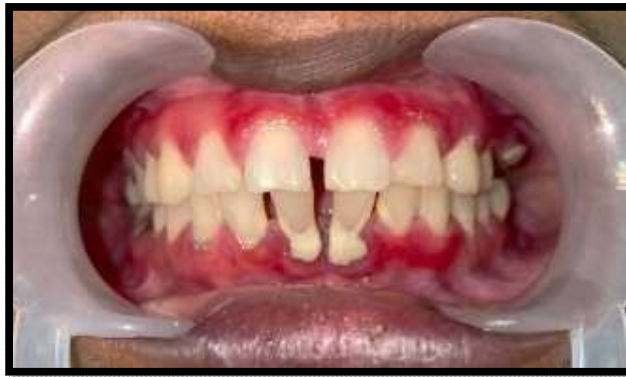Figure 4: 1-month post treatment images of gingiva, right and left buccal mucosa shows remission of lesion

**Case 2:** A female patient of age 37 years reported to the department of Oral medicine and Radiology with the chief complaint of the presence of multiple ulcers in the oral cavity for a period of 1 month. Patient gives the history of a single ulcer that started initially on the lips; around 10 days later, ulcers started to occur on multiple regions of the oral cavity. Patient gives history of skin allergy before 1 month for which she had taken over the counter medication and later gives history of developing ulcers. Her intraoral examination revealed the presence of diffuse ulcerations with mild encrustations noted on the lower lip, which is tender on palpation with evidence of bleeding [Figure 5] as well as there was a presence of diffuse areas of ulceration on the right and left buccal mucosa, upper labial mucosa and marginal and attached gingiva region of the upper anteriors. The surface of the ulcer appears yellowish

white, interspersed with erythematous components, the edges of the ulcer are continuous with the surrounding mucosa. On palpation, it is tender with evidence of bleeding [Figure 6]. Based on history and clinical presentation a provisional diagnosis of drug eruptions of the oral cavity was given with a differential diagnosis of erosive lichen planus, erythema multiforme and Pemphigus. The patient was subjected to blood investigations prior to the biopsy, which revealed all the blood parameters were within normal range. A perilesional biopsy of the right buccal mucosa was obtained for histopathological examination, which revealed suprabasilar intraepithelial split with few acantholytic cells and the connective tissue exhibits chronic inflammatory infiltrates [Figure 7]. Based on history, clinical presentation and investigations, a confirmed final diagnosis of Pemphigus was given. The patient was treated with prednisolone 10 mg twice daily for 14 days then tapered to once daily for 10 days and gradually the dosage was reduced. The lesions showed a reduction in severity in the 1 month follow-up, with no remission of lesions till date. [Figure 8] .

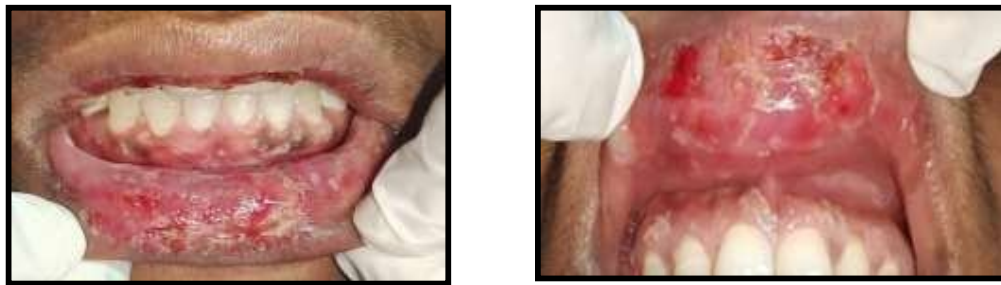

Figure 5 [a and b]: ulcerative surfaces with mild encrustations seen on upper and lower labial mucosa

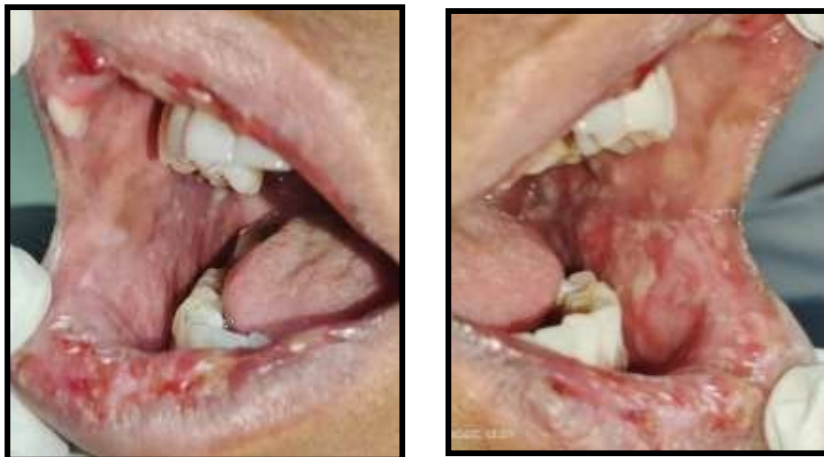

Figure 6 [a and b]: diffuse ulcerations in right and left buccal mucosa

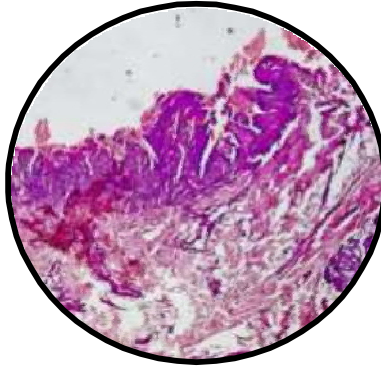


Figure 7: Haematoxylin and eosin (H&E) stained section showed suprabasilar intraepithelial split with few acantholytic cells, the connective tissue exhibits chronic inflammatory infiltrate

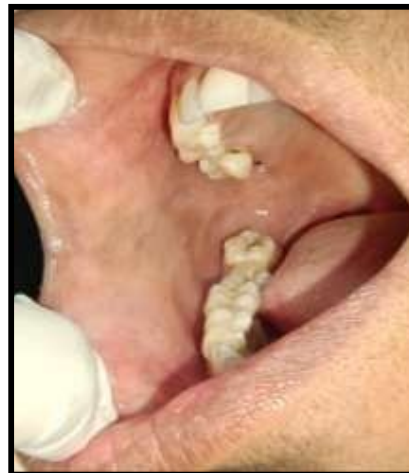
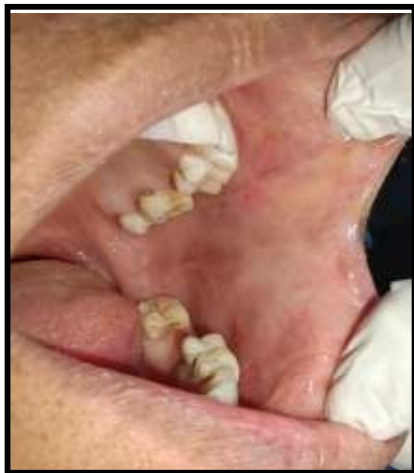
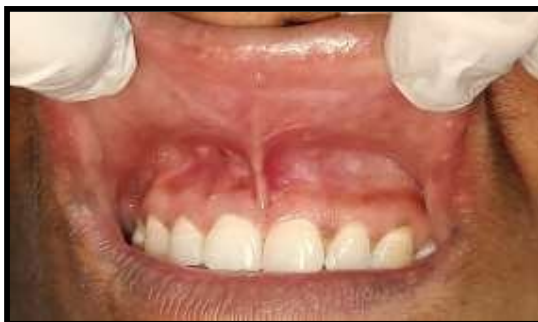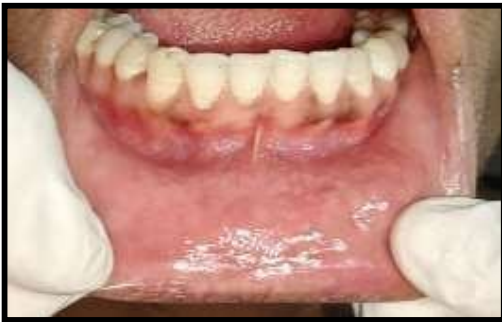Figure 8: 1-month post treatment images of right and left buccal mucosa shows remission of lesion

## Discussion:

“Vesiculobullous mucosal disorders, including some life-threatening diseases, manifest in the skin and mucous membranes and are clinically characterised by the appearance of blisters and secondary erosions”<sup>[6]</sup>. “Bullous autoimmune dermatoses have a common pathogenic mechanism involving the binding of autoantibodies to specific adhesion molecules in epidermal desmosomes and, in some cases, in the area of the dermo-epidermal basement membrane zone. The binding of circulating autoantibodies and the induction of an inflammatory reaction in the area of target structures lead to a loss of adhesion with subsequent intra- or subepidermal blister formation”<sup>[7]</sup>. In cases of Pemphigus, the IgG autoantibodies are targeted against desmoglein 3, a transmembrane glycoprotein adhesion molecule present on the desmosome, whereas in Pemphigoid, the IgG autoantibodies are targeted against the lamina lucida region of the basement membrane. The common aetiology behind any vesiculobullous disease could be genetic, viral, autoimmune, drug induced, bacterial, or even food additives<sup>[8]</sup>. “Prospective studies suggest the incidence rates of vesiculobullous diseases are in the range of 14.5-20.4 per million”<sup>[9]</sup>. “Most of the available epidemiological data shows that Pemphigus vulgaris is the most frequently reported disorder among the vesiculobullous lesions”.<sup>[10]</sup> “The clinical presentations of these diseases often overlap, and a diagnosis may not be easily made on the basis of clinical features alone. Hence, the diagnosis consists of a trio of criteria: (1) the overall clinical picture, including patient history and physical examination; (2) histopathology; and (3) a positive direct immunofluorescence (DIF) microscopy, usually performed on perilesional skin, or serological detection of autoantibodies against the involved epithelial antigens”<sup>[11]</sup>. Among these, immunofluorescence studies remain the gold standard, yet in long-standing cases they may give false negative results. Biopsy for suspected vesiculobullous disease shows subepithelial separation in Pemphigoid and intraepithelial separation in Pemphigus and cases of Paraneoplastic pemphigus may show both intraepithelial and subepithelial separation<sup>[12]</sup>

“when the clinical or microscopic findings are inconclusive, direct immunofluorescence is used to demonstrate the presence of immunoglobulins, predominantly IgG but sometimes in combination with C3, IgA, and IgM, in the intercellular spaces. Indirect immunofluorescence has also been used to substantiate the diagnosis of Pemphigus. A positive reaction in the tissue indicates the presence of circulating immunoglobulin antibodies”<sup>[13]</sup>. Wherein cases of pemphigoid show linear IgG and C3 at BMZ in direct immunofluorescence and linear IgG at BMZ in indirect immunofluorescence assays<sup>[14]</sup>. The differential diagnosis for vesiculobullous disorders has a wide range of diseases due to their

overlapping clinical features, and based on the clinical features and history given by the patient in the above mentioned 2 cases, the differential diagnosis could be for case 1 [Plasma cell gingivitis, Lichen planus and Pemphigoid] and for case 2 [Erosive lichen planus, Erythema multiforme and Pemphigus].

“The management of these vesiculobullous diseases starts with suppressing the production of pathogenic antibodies, to stop new lesions, and heal old ones. These goals are usually accomplished with the use of systemic glucocorticoids, with or without steroid-sparing agents. In addition, dapsone, hydroxychloroquine has been used with variable effect” [15]. “Commonly used treatments for Pemphigus include corticosteroids and immunosuppressive drugs. There is no standard treatment for Pemphigus vulgaris, and data from randomised trials using various drugs and methods are still inconclusive. Recently, newer agents such as intravenous immunoglobulin therapy, rituximab, immunoadsorption using the Glo-Baffin adsorber system, and immunoadsorption for rapid removal of desmoglein-reactive autoantibodies are being used” [16]. “For Pemphigoid the treatment options most frequently used are systemic corticosteroids alone or in combination with other immunosuppressive agents. In recent times, systemic dapsone, cyclosporine, sulfapyridine, as well as a combination of tetracycline and niacinamide, have demonstrated therapeutic effect” [17-19].

## CONCLUSION

The myriad of cutaneous and mucosal hypersensitivity reactions with characteristic clinical presentations of lesions are triggered by certain antigenic stimuli, thus representing a variety of acute conditions that involve both the skin and mucous membrane. Due to the varied nature of these diseases with overlapping clinical signs and symptoms, it still remains a diagnostic dilemma in many clinical scenarios. As an oral physician, we play a vital role in the diagnosis and management of those diseases through careful evaluation of combined history, clinical, histological, and immunofluorescent data. A multidisciplinary approach to treating these conditions, along with proper follow-up, would aid in managing the acute nature of these diseases and improve the well-being of patients.

### Consent

As per international standard or university standard, patients' written consent has been collected and preserved by the author(s).

### Ethical Approval:

As per international standard or university standard written ethical approval has been collected and preserved by the author(s).

---

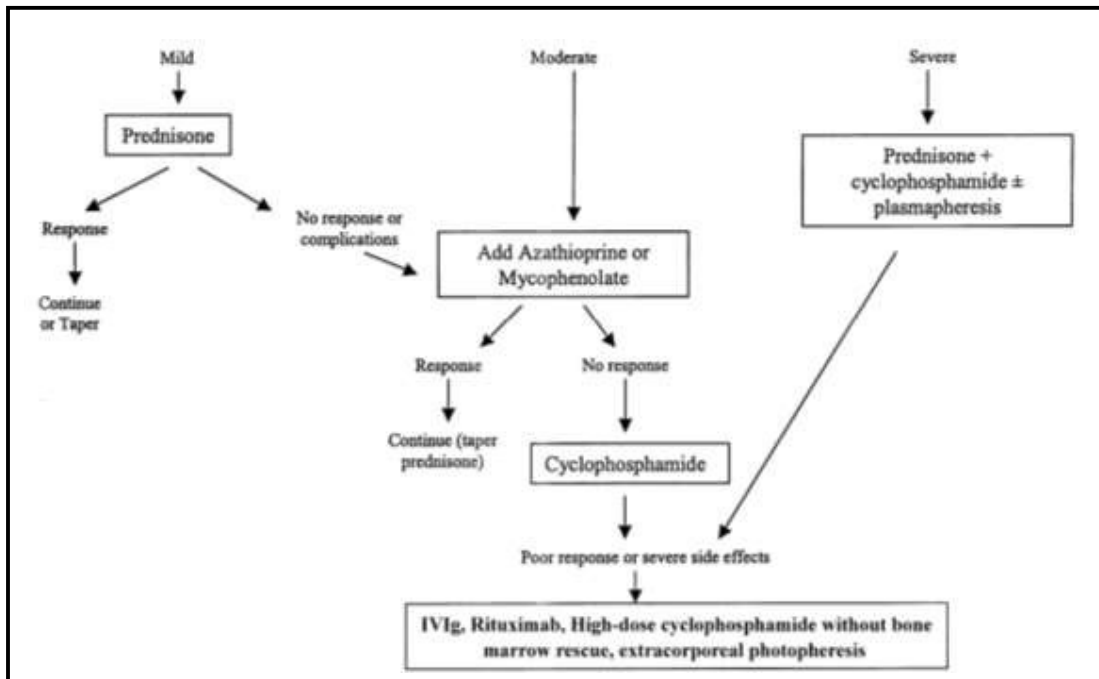


Figure 9: Management logarithm for Pemphigus vulgaris <sup>[15]</sup>

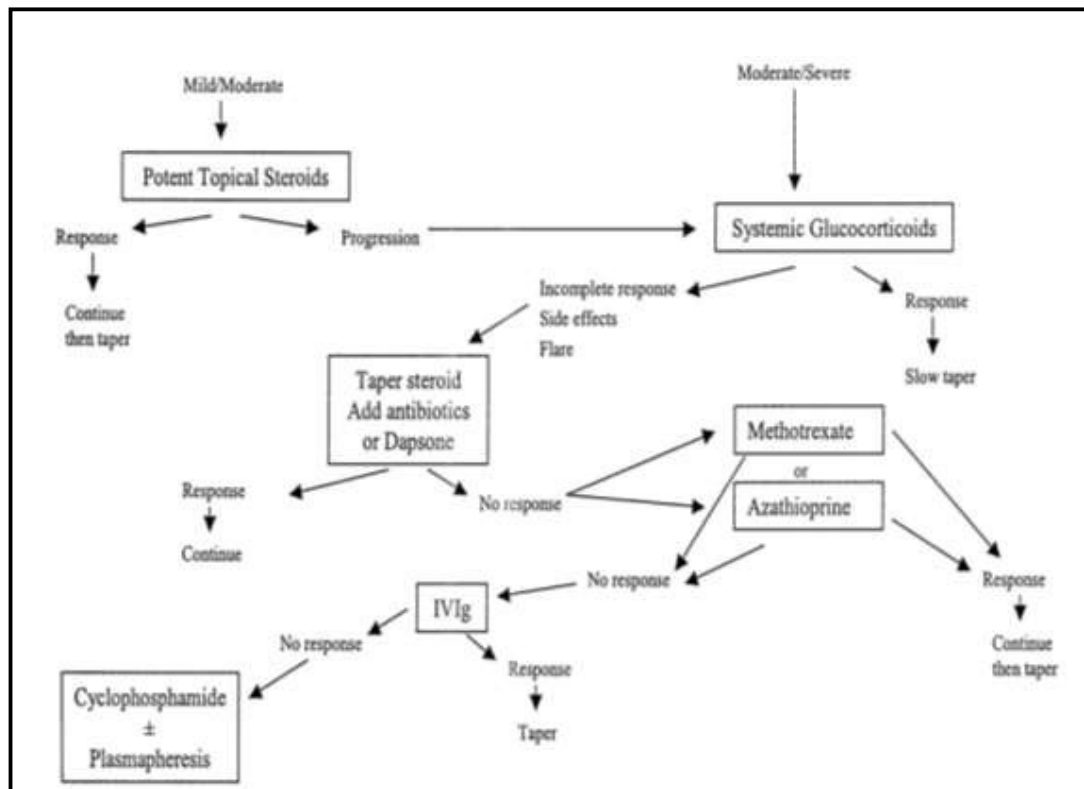


Figure 10: Management logarithm for Mucous membrane Pemphigoid <sup>[15]</sup>

## REFERENCES

1. Gonçalo Ric, Severo Mlb, Medeiros De Amc, Oliveira De Pt, Silveira Da Éjdd. Vesiculobullous autoimmune diseases with oral mucosa manifestations: retrospective and follow-up study. *RGO Rev Gaúcha Odontol.* 2018;66(1):42-9.
  2. Ramos-e-Silva M, Ferreira A, Jacques CMC. Oral involvement in autoimmune bullous diseases. *Clin Dermatol.* 2011;29(4):443-54.
  3. Suliman NM, Åstrøm AN, Ali RW, Salman H, Johannessen AC. Oral mucosal lesions in skin diseased patients attending a dermatologic clinic: a cross-sectional study in Sudan. *BMC Oral Health.* 2011;11:24.
  4. Prakash A, Ganjikunta, Sreenath, Hussain S, Harsha D. Intraepithelial vesiculobullous lesions: review and A case report; 2021.
  5. Schmidt E, Zillikens D. Pemphigoid diseases. *Lancet.* 2013;381(9863):320-32.
  6. Erugula SR, Singaraju DK, Govada J, Rajajee KTSS, Sudheer MVS, Sudharshan Kumar A et al. Vesiculobullous lesions of the oral cavity. *Int Arch Integr Med.* 2016;3(11):154-63.
  7. Sitaru C, Zillikens D. Mechanisms of blister induction by autoantibodies. *Exp Dermatol.* 2005;14(12):861-75.
  8. Glick M. *burket's oral medicine, 12e.* PMPH; 2015.
  9. Lerna Di V, Casanova DM, Goldust M, Ricci C. Pemphigus vulgaris and bullous pemphigoid: update on diagnosis and treatment. *Dermatol Pract Concept.* 2020;10(3):e2020050.
  10. Alpsy E, Akman-Karakas A, Uzun S. Geographic variations in epidemiology of two autoimmune bullous diseases: pemphigus and bullous pemphigoid. *Arch Dermatol Res.* 2015;307(4):291-8.
  11. Pollmann R, Schmidt T, Eming R, Hertl M. Pemphigus: a comprehensive review on pathogenesis, clinical presentation and novel therapeutic approaches. *Clin Rev Allergy Immunol.* 2018;54(1):1-25.
  12. Fitzpatrick SG, Cohen DM, Clark AN. Ulcerated lesions of the oral mucosa: clinical and histologic review. *Head Neck Pathol.* 2019;13(1):91-102.
  13. Rajendran R, Shivapathasundharam. *Shafer's textbook of oral pathology.* 5th ed. Elsevier publications.
  14. Arbache ST, Nogueira TG, Delgado L, Miyamoto D, Aoki V. Immunofluorescence for the diagnosis of autoimmune blistering diseases: a 10-year Brazilian overview. *An Bras Dermatol.* 2014;89(6):885-9.
  15. Mutasim DiyaF. Management of autoimmune bullous diseases: pharmacology and therapeutics. *J Am Acad Dermatol.* 2004;51(6):859-77; quiz 878.
-

16. Paavai T, Tha Dr. D. Medical management of vesiculobullous lesions in oral cavity. *Int J Sci Res (IJSR)*. 2017;6(4, April):1136-8.
  17. Berk MA, Lorincz AL. The treatment of bullous pemphigoid with tetracycline and niacinamide. A preliminary report. *Arch Dermatol*. 1986;122(6):670-4.
  18. Korman N. Bullous pemphigoid. *J Am Acad Dermatol*. 1987;16(5 Pt 1):907-24.
  19. Person JR, Rogers RS. Bullous cicatricial pemphigoid. Clinical, histopathologic and immunopathologic correlations. *Mayo Clin Proc*. 1977;52(1):54-66.
-