

Case study

Giant Pulmonary Artery Aneurysm associated to severe mitral stenosis: Review and case report

Abstract:

Pulmonary artery aneurysm is a rare abnormality of pulmonary vasculature that is frequently associated with pulmonary hypertension. However, the evolution and treatment of this pathology are still not clear. A 33-year-old patient with a medical history of transcatheter mitral commissurotomy was admitted for dyspnea class III of the NYHA and lower extremity edema. The clinical examination found the semiology of mitral stenosis and signs of both right and left heart failure. The electrocardiogram showed complete atrial fibrillation and right ventricle hypertrophy. Chest X-ray found cardiomegaly and a prominent aspect of the left aortic knob reminding an aneurysm of the left pulmonary artery. The echocardiography Doppler found a pure tight mitral stenosis (mitral surface = 0.8 cm²), a dilation of the trunk of the pulmonary artery (diameter = 74 mm), and of its branches. The right cardiac cavities were also dilated with an important tricuspid regurgitation and major pulmonary hypertension (systolic pulmonary arterial = 95 mmHg). The thoracic angioscan angiography revealed aneurysmal dilation of the trunk of the pulmonary artery and its branches without dilation of their distal parts (diameter of the pulmonary artery = 76 mm; Right pulmonary artery diameter = 51 mm, left pulmonary artery diameter = 40 mm). Under diuretic, anticoagulating, and analgesic treatment the clinical signs improved, and then the patient was referred to the cardiovascular surgery department for mechanical mitral valve replacement and plastic surgery of the pulmonary artery.

Keywords: Pulmonary artery aneurysm, mitral stenosis, pulmonary hypertension, case report

Aim of the Study

The purpose of this article is to report our rare case and review the pertinent literature.

Introduction:

Aneurysms are uncommon abnormalities of the pulmonary arteries that can be potentially life-threatening.

Its incidence has been estimated to be 1 in 14,000 autopsies [1]. Contrary to aortic aneurysms, there is no clear definition of PA aneurysms. There have been no standard diameter size parameters that define PAA. Most commonly, PAA is defined as dilatation greater than 40 mm. Main pulmonary aneurysm can be defined, based on the recent literature, as a dilatation greater than 1.5 times the upper limit of normal, which is equivalent to 43.4 mm in males and 40.4 mm in females. The maximum described diameter of the MPA was 106–170 mm [2]. The frequency of pulmonary aneurysms (PAA) is independent of age and gender [3].

Aneurysms can be true or pseudo aneurysms. By definition, a true aneurysm is a local dilatation of a blood vessel, involving all three layers of the vessel wall: intima, media, and adventitia.

Otherwise, pseudoaneurysms do not affect all arterial walls and are at increased risk of rupture [4].

These lesions are in 70% central aneurysms involving the pulmonary trunk, right or left main pulmonary artery and in 30% peripheral aneurysms arising from segmental or intrapulmonary branches [1].

The pathophysiology of the PA aneurysm is related to vessel wall stress that leads to vessel progressive dilatation or even rupture that carries an extremely high mortality rate (50–100%) [4]. Aneurysm dissection, airway compression, and thrombus formation on the pulmonary artery are other serious complications of large PA aneurysms.

Clinical manifestations of PAAs are usually nonspecific or asymptomatic[5]. Most patients present with unremarkable symptoms such as dyspnoea, cough, chest pain, and hemoptysis and are referred due to vascular dilatation on imaging[4]. Heart failure symptoms can also be observed, secondary to pulmonary regurgitation, trachea or bronchi compression, or pulmonary emboli from the enlarged MPA [3,6].

Table 1 :The etiology of PAA may be congenital or acquired[5,7]

CONGENITAL	ACQUIRED	
	True aneurysms	Pseudoaneurysms
*Increased pulmonary blood flow (Eisenmenger's syndrome) *Heart defects (Pulmonary valvular abnormalities, Ductus arteriosus, Atrial septal defects, Ventricular septal defects, Hypoplastic aortic valve) *Connective tissue abnormalities (Ehlers – Danlos syndrome, Marfan syndrome, Cystic medial necrosis)	*Pulmonary arterial hypertension related Lung conditions other than pulmonary hypertension: Bronchiectasis and pulmonary; fibrosis; Interstitial lung diseases COPD *Pulmonary artery hypertension *Vasculitis: Behcet's disease *Idiopathic	*Post-infectious (Endocarditis Tuberculosis, Syphilis, Pyogenic bacteria, Pneumonia) *Malignancy related: Metastasis, Primary lung cancer *Iatrogenic: Cardiac surgery; Chest tube placement; Lung biopsy; PA catheter placement; PA arteriography; Lung resection; Radiation in the past *Traumatic

Diagnosis:

Physical examination may detect a systolic murmur combined with a diastolic murmur due to pulmonary valve insufficiency [6]. The electrocardiogram is usually normal but the deviation of the cardiac axis toward the right or bundle branch blocks can be present [8].

Chest x-ray shows an enlarged PA, hilar enlargement, pulmonary nodule, or pulmonary mass. Accurate echocardiogram focusing on RV outflow tract/PA view allows early diagnosis.

The value of echocardiography in diagnosing peripheral aneurysms is limited and 26 mm is the echocardiographic reference value for MPA dilatation [6].

Cardiac computed tomography is very helpful in assessing the size of the pulmonary artery and excluding other causes of dilated pulmonary artery. Owing to its high spatial resolution, contrast-

enhanced computed tomography is considered to be the primary technique for diagnosing pulmonary artery dilation as it offers a unique opportunity to evaluate the presence, size, shape, exact location of the aneurysm, and concomitant cardiovascular abnormalities. The upper limit of the normal diameter of the main pulmonary artery on computed tomography is 29 mm and of the right interlobar artery is 17 mm [9]. CT angiography is an excellent modality because it can easily identify wall thrombi, dissections, or other abnormalities. Multiplanar reconstruction helps in surgical planning [8].

In addition to cardiac computed tomography angiogram, magnetic resonance imaging is also considered the gold standard to confirm the diagnosis and provide additional information about the size, number, location, and extent of PAA, especially in the detection of possible intimal flap. It may show the arterial wall thickening in connective tissue diseases and also provide information regarding hemodynamics in cases of post-stenotic dilatation due to disease involving the pulmonary valve [10]. CMR is a useful non-invasive modality to quantify the pressure gradient of pulmonary artery stenosis without the need for contrast agents or radiation exposure and to detect other causes of dilated pulmonary artery [8].

Heart catheterization is deemed essential for establishing the diagnosis, while it helps to rule out causes of the dilated pulmonary artery and to establish the pressures in heart chambers quintessential for diagnosis [8].

Treatment:

Once a pulmonary aneurysm is diagnosed, determining the appropriate treatment is a challenge, as there are no clear guidelines on recommended treatment. As previously mentioned, PAA has multiple etiologies and therapeutic strategies vary and are based on underlying etiology, hemodynamics, and associated complications.

Most PAA appear to be relatively benign, especially if they remain asymptomatic. On the other hand, PAA anatomy is associated with poor prognosis. Clear risk factors for PAA dissection and rupture are still lacking. Analysis of case reports revealed that predictors of high risk were: Rapid PAA diameter progression (>2 mm/year), tissue weakness due to infection and/or pregnancy, PA diameter >75 mm, or PA systolic pressure >50 mm Hg [2].

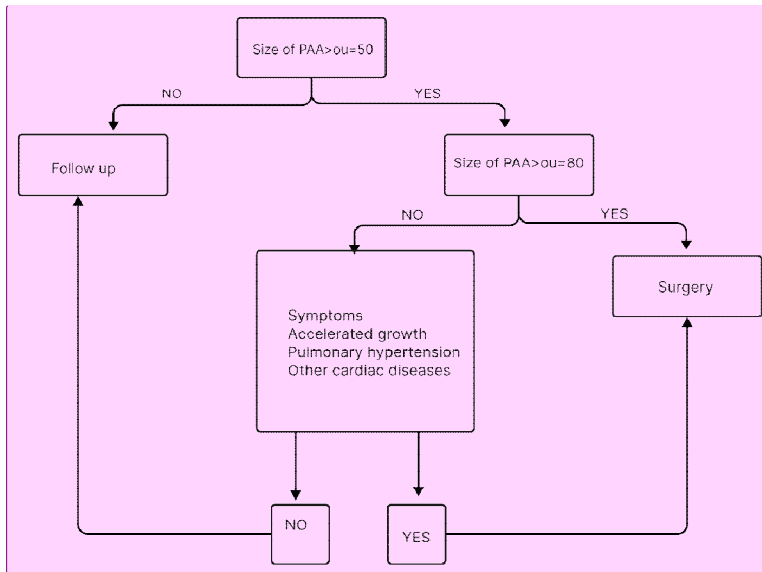
Conservative treatment options include targeted medical management of underlying disease, management of pulmonary hypertension, and regular radiological follow-up for PAA. Surgical techniques such as aneurysmorrhaphy, lobectomy, bilobectomy, aneurysmectomy, and pneumonectomy are described in the literature but are associated with an increased risk of morbidity and mortality, especially in patients with pulmonary hypertension. Endovascular interventions, such as coil embolization and vascular plugs represent good alternatives for treatment, but there are no specific guidelines for their use [7].

Conservative treatment should be selected in asymptomatic patients without pulmonary hypertension and unstable PAA size. In case of vasculitis or infectious etiology, causative treatment should be assigned. Interventional treatments, such as coil embolization and vascular plugs, are treatment options for iatrogenic causes and for small branches [7,11].

Symptomatic patients or those with accelerated PAA increase with pulmonary hypertension (defined as RVSP >35 mmHg) should undergo surgery [12,13]. Asymptomatic patients with a PAA diameter ≥ 80 mm should also be referred for cardiac surgery [6,12,13].

This raises the question of when to choose high-risk procedures and when to choose conservative treatment.

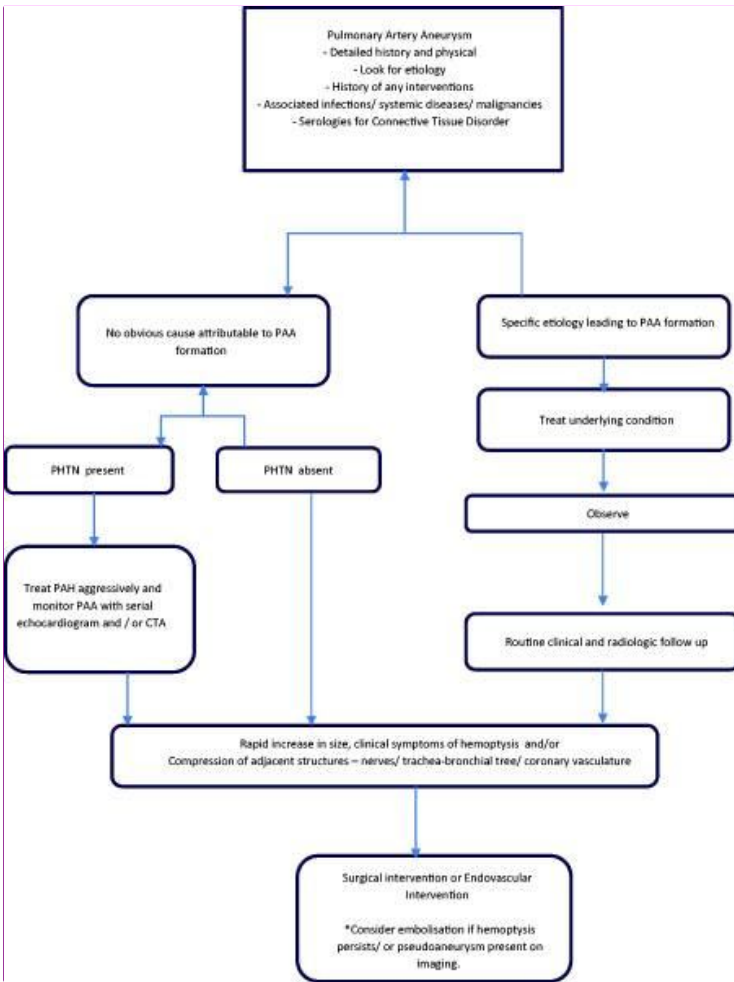
There is no consensus on how to treat PAA and currently, there are no treatment guidelines outlining the choice between risky procedures and conservative management. However, some authors have proposed management algorithms. The management scheme proposed by Reisenauer [12] is described below (Fig1).



Comment [AC1]: ou is not a common acronym, please explain. Also mention the units while writing the measurements of diameter.

Figure 1 : Algorithm for management for pulmonary artery aneurysm proposed by Reisenauer.

Gupta and his team proposed another management algorithm based on the experience of the Department of Medicine of Monmouth Medical Center in USA described in the figure below [7]:



Comment [AC2]: This figure is not clear.

Figure 2 : Algorithm for management for pulmonary artery aneurysm proposed by Gupta. PAH: pulmonary arterial hypertension; PAA: pulmonary artery aneurysm; PHTN: pulmonary hypertension; CTA: computed tomography angiography. *Indicates a special point to be considered.

Outcomes:

High risk of sudden death, compression of the left main coronary artery, right PA thrombosis, lung compression, and atelectasis are associated with a PA diameter larger than 55mm and high pressure of PPA [2]. Rupture of the PAA leading to intrapulmonary hemorrhage and PAA dissection are the main complications with a fatal prognosis [14].

Since PAA is uncommon and rare, data regarding surgical outcomes are poor. However, perioperative morbidity is similar to that of the repair of aneurysms of the ascending aorta. Ventilation difficulties represent the main postoperative problems [11].

Although endovascular treatments of PAA carry fewer inherent risks compared to surgery, they maintain similar risks to other endovascular embolization procedures throughout the body. These risks include contrast-induced nephropathy, non-target embolization, arterial dissection, arterial thrombosis, and partial or complete end-organ infarction [3].

Case Summary:

A 33-year-old woman with a medical history of transcatheter mitral commissurotomy for severe mitral stenosis 8 years ago, presented with worsening dyspnea associated with lower-extremity edema that appeared 2 weeks before her admission.

The general examination found a conscious patient. Her heart rate was 94 b/m, and her blood pressure was 110/68 mm Hg. She was polypneic with a respiratory rate of 20 breaths/min, and an **O₂** saturation of 97% on ambient air. Physical examination revealed infundibulopulmonary shock, apex diastolic rolling of 4/6th intensity with fine bibasilar crackles, positive spontaneous turgidity of the jugular veins, and pitting edema involving her lower extremities bilaterally. Further physical examination was normal.

Comment [AC3]: Replace it with O2

Her blood test did not reveal any abnormalities.

The electrocardiogram showed an arrhythmia complete by atrial fibrillation with an average ventricular rate of 94 cycles per minute, a QRS axis at +110°, and a right ventricular preponderance.

Chest X-ray (Fig. 3) demonstrated cardiomegaly (with a cardiothoracic ratio of 67%) due to the expense of the right heart chambers and the left atrium, a double contour aspect of the lower right arch, a prominent aspect of the left middle arch, large vascular hilum and rarefaction of the vascular network at the periphery.

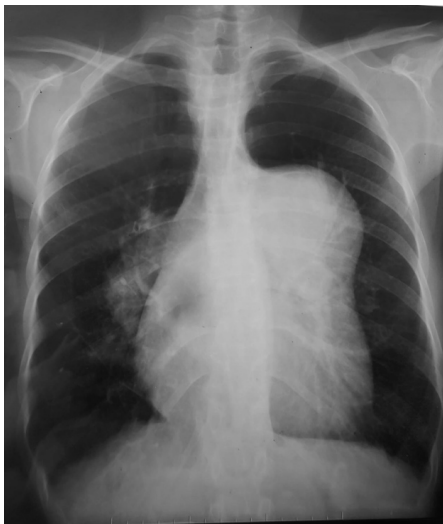

Fig. 3: Chest X-ray showing cardiomegaly with the prominent middle left arch and double outline of the lower right arch.

The echocardiography (Fig. 4) found mitral valves thickened, very altered, and of limited opening (mitral area = 0.8 cm² by mean gradient planimetry OG-LV = 17 mmHg) without associated mitral regurgitation. The aortic sigmoids were remodeled but of correct opening without aortic regurgitation. Significant tricuspid insufficiency with Major PAH (95 mmHg). A significant expansion of both the left and right atrium. Dilation size of the right ventricle. The pulmonary artery is dilated (diameter = 74 mm in parasternal section left centered on the pulmonary artery, the diameter ratio of pulmonary artery/aorta diameter = 2.5) as well as its two branches without contrast in the pulmonary artery or its branches.

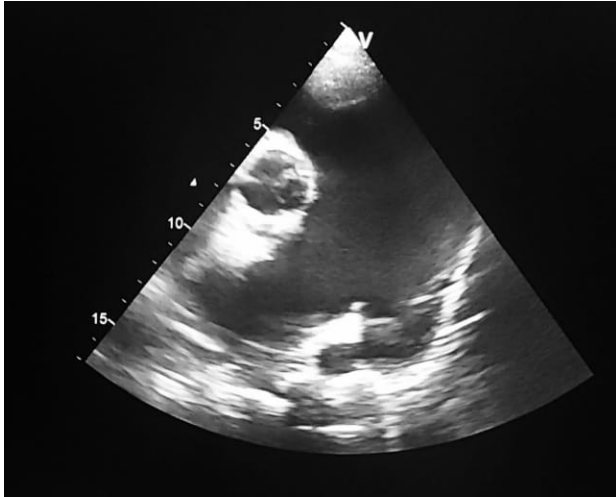


Fig. 4: ETT 2D short-axis parasternal view centered on the pulmonary artery showing significant dilation of the trunk of the pulmonary artery and its branches.

Chest CT angiography (Fig. 5 and 6) revealed aneurysmal dilation of the pulmonary artery and its Branches without dilation of their distal parts (diameter of the pulmonary artery = 76 mm; Right pulmonary artery diameter = 51 mm, left pulmonary artery diameter = 40 mm).

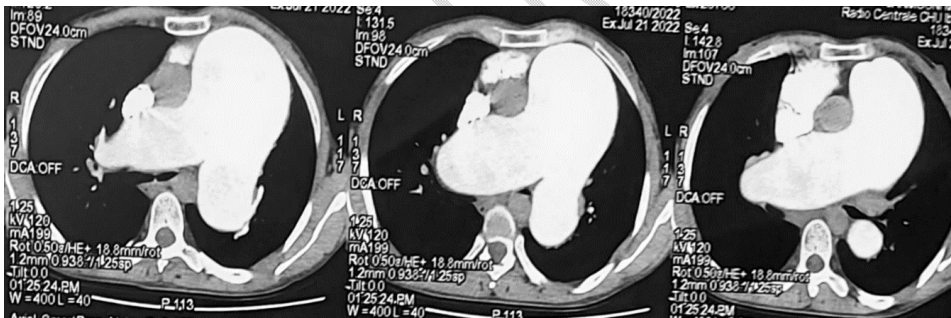


Fig. 5: Chest CT showing aneurysmal dilatation of the trunk of the artery lung and its branches.

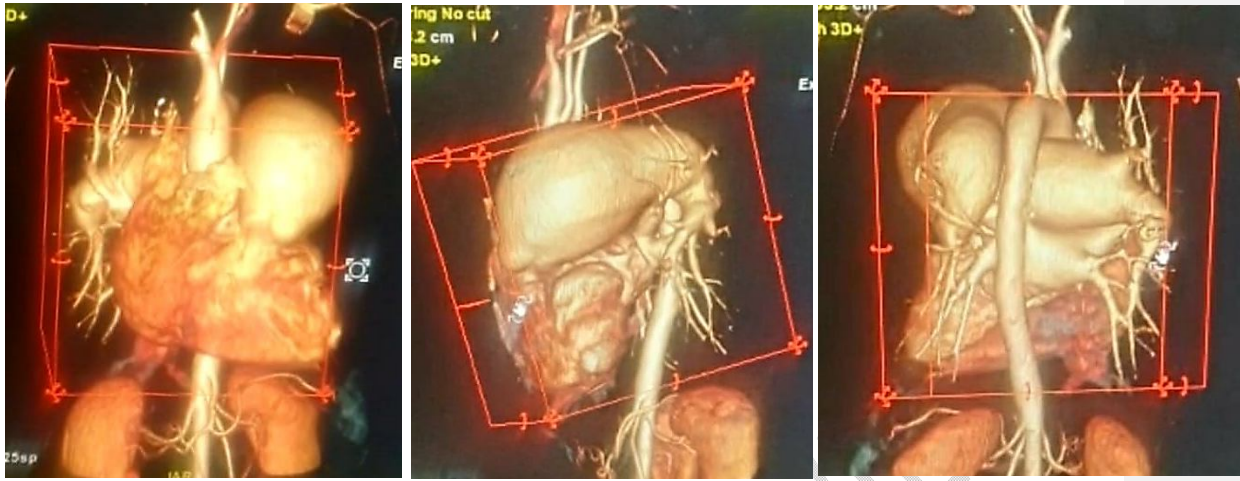


Fig. 6: Three-dimensional reconstruction of the heart and the massively dilated trunk of the pulmonary artery and its branches main pulmonary artery

Good evolution was noted under diuretic, anticoagulant, and analgesic treatment, and the patient was referred to the cardiovascular surgery department for mechanical mitral valve replacement and plastic surgery of the pulmonary artery.

Discussion:

Proximal pulmonary artery aneurysms, defined by a ratio of the diameter of the pulmonary artery to that of the aorta greater than 2 are rare and bilateral aneurysms are exceptionally described [15]. The clinical manifestations are nonspecific and rare. PAA can remain asymptomatic and the diagnosis, in this case, is made fortuitously on the chest X-ray showing widening of the pulmonary arch. Sudden death can also be a diagnostic circumstance [16]. It is highly probable that the patient's symptoms concerning worsening and lower-extremity edema were secondary to the left heart valve disease represented by this significant mitral stenosis that needs surgical treatment.

PAA etiologies are dominated by bacterial infections (syphilis, tuberculosis) or mycosis infections, inflammatory arteritis (giant cellular arteritis, Behçet), congenital or acquired heart disease, and valvulopathy. Traumatic etiologies are also cited. The primitive forms are exceptional and are associated in half of the cases with a heart defect: ductus arteriosus persistence, atrial septal defect, or interventricular defect [7]. Chronic PAH can be a source of aneurysm of the pulmonary artery by direct attack of the wall with atherosclerosis and media necrosis leading to aneurysmal distension [17]. But it has not yet been proven that treatment lowering the pulmonary artery pressure could significantly affect the lack of its progression [8]. Pulmonary hypertension. In the case of the patient in question, the most probable mechanism of dilatation PA was pulmonary hypertension secondary to severe mitral stenosis.

Many complications can be noticed such as pulmonary embolism, dissection or rupture of the aneurysm, right heart failure and compression of the trunk of the left coronary artery, the right superior pulmonary vein, the superior vena cava, trachea, and recurrent nerve [19].

Surgical repair (Dacron interposition [Dupont], homograft, prosthesis or reconstruction with pericardial patch, aneurysmorrhaphy or arterioplasty) is recommended when discovering these aneurysms [20]. Most often, surgery should be proposed when the operative risk for the patient is sufficiently low, or when there is a progressive increase in the diameter of the pulmonary artery or in presence of PA dissection [21]. Amongst available treatment methods for the aforementioned patient, and after taking the risk of cardiac surgery into consideration, it was decided that the most appropriate one would be repairing the aneurysm in order to prevent the artery from widening in the future with mitral valve replacement.

It was noticed in a Japanese study that the PA aneurysm area showed increased EP4 receptor (for the cyclooxygenase-2-dependent PGE2) expression compared to non-PAA areas [18]. Increased expression of this receptor was also described in non-striated muscle cells, macrophages, and in abdominal aortic aneurysm areas [22,23]. The activity of metalloproteinase 2 and the production of interleukin 6 are increased by PGE2, via the EP4 receptor, leading to the degradation of elastic fibers and thus redounding to the AAA progression [22, 24]. Nonsteroidal anti-inflammatory drugs and selective COX-2 inhibitors suppress PGE2 synthesis. However, those drugs ought not to be used at length due to their adverse drug reactions (such as the increased risk of gastrointestinal bleeding with the use of NSAID and cardiovascular events with the use of COX-2 inhibitors). An interesting goal of pharmacotherapy would be to inhibit the progression of aneurysms by a selective EP4 receptor antagonist that can be one of the treatment options in the future [5].

Conclusion:

Patients with PAA are most often asymptomatic or do present with nonspecific symptoms and thus are rarely diagnosed. To date, due to the low prevalence of PA aneurysms, there are no guidelines for diagnosis, management, or follow-up on these patients. Surgical treatment should be considered in Pulmonary artery dilatation over 80 mm, accelerated growth of aneurysm, pulmonary hypertension, and concomitant other cardiac diseases. However, a multidisciplinary plan of action is necessary to increase survival while minimizing procedure-related morbidities and mortalities.

Ethical approval

The study was exempt from ethical approval in our institution.

Consent

Written informed consent was obtained from the patient for publication of this case report and accompanying images. A copy of the written consent is available for review by the Editor-in-Chief of this journal on request.

Research registration (for case reports detailing a new surgical technique or new equipment/technology)

None.

References:

1. Gruber PJ, Askin FB, Heitmiller RF. Pulmonary artery aneurysm in a pregnant woman. *Ann Thorac Surg* 2001;71:1023-5.

2. Duijnhouwer AL, Navarese EP, Van Dijk APJ, et al.. Aneurysm of the pulmonary artery, a systematic review and critical analysis of current literature. *Congenit Heart Dis* 2016; 11: 102-109.
3. Gallego P, Rodríguez-Puras MJ, Serrano Gotarredona P, et al.. Prevalence and prognostic significance of pulmonary artery aneurysms in adults with congenital heart disease. *Int J Cardiol* 2018; 270: 120-125.
4. Park HS, Chamarthy MR, Lamus D, et al.. Pulmonary artery aneurysms: diagnosis and endovascular therapy. *Cardiovasc Diagn Ther* 2018; 8: 350-361.
5. Marzec K, Jaworska-Wilczyńska M, Grobelny K, Kolsut P, Michałowska I, Stokłosa P, Hryniewiecki T. Pulmonary artery aneurysm as a result of group 2 pulmonary artery hypertension in a patient with significant mitral and aortic valve disease - review and case report. *Kardiochirurgia i Torakochirurgia Pol.* 2020 Sep;17(3):143-148.
6. Sheikhzadeh S, De Backer J, Gorgan NR, et al.. The main pulmonary artery in adults: a controlled multicenter study with assessment of echocardiographic reference values, and the frequency of dilatation and aneurysm in Marfan syndrome. *Orphanet J Rare Dis* 2014; 9: 203.
7. Gupta M, Agrawal A, Iakovou A, Cohen S, Shah R, Talwar A. Pulmonary artery aneurysm: a review. *Pulm Circ.* 2020 Feb 28;10(1):2045894020908780.
8. Malviya A, Jha PK, Kalita JP, Saikia MK, Mishra A. Idiopathic dilatation of pulmonary artery: A review. *Indian Heart J.* 2017 Jan-Feb;69(1):119-124.
9. Nguyen E.T., Silva C.I., Seely J.M., Chong S., Lee K.S., Müller N.L. Pulmonary artery aneurysms and pseudoaneurysms in adults: findings at CT and radiography. *Am J Roentgenol.* 2007;188:W126–W134.
10. Ugolini P., Mousseaux E., Sadou Y. Idiopathic dilatation of the pulmonary artery: report of four cases. *MagnReson Imaging.* 1999;17(July (6)):933–937.
11. Kreibich M, Siepe M, Kroll J, et al.. Aneurysms of the pulmonary artery. *Circulation* 2015; 131: 310-316.
12. Reisenauer JS, Said SM, Schaff HV, et al.. Outcome of surgical repair of pulmonary artery aneurysms: a single-center experience with 38 patients. *Ann Thorac Surg* 2017; 104: 1605-1610.
13. Kuwaki K, Morishita K, Sato H, et al.. Surgical repair of the pulmonary trunk aneurysm. *Eur J Cardiothoracic Surg* 2000; 18: 535-539.
14. DeLima LG, Wynands JE, Bourke ME, Walley VM. Catheter-induced pulmonary artery false aneurysm and rupture: case report and review. *J CardiothoracVascAnesth* 1994; 8: 70-75.

Comment [AC4]: Please remove double dot after et al from all the references.

15. Bartter T, Irwin RS, Nash G. Aneurysm of the pulmonary arteries. *Chest* 1988;94:1065–75
16. Kodikara S, Sivasubramaniam M. Bilateral pulmonary artery aneurysms. *Leg Med* 2009;(Suppl. 11):S496–7.
17. Butto F, Lucas RV, Edwards JE. Pulmonary arterial aneurysm: a pathologic study of five cases. *Chest* 1987;91:237–41.
18. Akagi S, Nakamura K, Sarashina T, et al.. Progression of pulmonary artery dilatation in patients with pulmonary hypertension coexisting with a pulmonary artery aneurysm. *J Cardiol* 2018; 71: 517-522.
19. Decuyper V, Delcroix M, Budts W. Left main coronary artery and right pulmonary vein compression by a large pulmonary artery aneurysm. *Heart* 2004;90:e21–121
20. Arom KV, Richardson JD, Grover FL, Feris G, Trinkle JK. Pulmonary artery aneurysm. *Am Surg* 1978;44:688–92.
21. Mastroroberto P, Chello M, Zofrea S, Del Negro G, De Francesca F, Maltese G. Pulmonary artery aneurysm [Letter]. *Ann Thorac Surg* 1997;64:585–6.
22. Yokoyama U, Ishiwata R, Jin MH, et al.. Inhibition of EP4 signaling attenuates aortic aneurysm formation. *PLoS One* 2012; 7: e36724.
23. Dilmé JF, Solà-Vilà D, Bellmunt S, et al.. Active smoking increases microsomal pgesynthase-1/pge-receptor-4 axis in human abdominal aortic aneurysms. *Mediators Inflamm* 2014; 2014: 316150.
24. Mamun A, Yokoyama U, Saito J, et al.. A selective antagonist of prostaglandin E receptor subtype 4 attenuates abdominal aortic aneurysm. *Physiol Rep* 2018; 6: e13878.