

A Case Report on Primary Renal Synovial Sarcoma

ABSTRACT

Primary Renal Synovial Sarcoma, a rare tumor, comprises of only 1% of all malignant tumours arising from the kidney. Synovial sarcomas are deep-seated tumors which arise in close proximity of large joints of young adults and comprise of 5–10% of all soft tissue neoplasms. Primary synovial sarcoma of kidney being rare carries a poor prognosis. It can only be diagnosed by Histopathology and immunohistochemistry. Here we present a case of a 43 year old male who presented to us with complaints of abdominal lump on the right side. Patient underwent exploratory laparotomy with right nephrectomy for renal mass. Histopathology confirmed it to be a Monophasic Synovial Sarcoma.

Keywords: Histopathology; primary renal synovial sarcoma; tumour; kidney.

1. INTRODUCTION

Primary renal synovial sarcoma (PRSS) was described by Faria in 2000 [1-3]. Despite all features, the natural history of the tumour, the management of this tumour is still unclear [4-5]. Synovial sarcoma (SS) or sarcoma of tissues arising close to joints, is a rare type of soft tissue sarcomas, and comprise of 5 to 10% of all Soft Tissue Sarcomas. SS is commonly seen in males around the proximal large joints. Other unusual sites include the heart, head and neck, lungs, and kidneys. Owing to its rarity and difficulty in distinguishing from other renal pathologies, very few cases have been tackled. We present a case of PRSS which was diagnosed by Histopathology.

2. CASE PRESENTATION

A 43 year old gentleman presented with symptoms of gastric outlet obstruction and abdominal lump on right side since 2 months. Patient gave no history of hematuria, fever, pain. There were no known co-morbidities.

Clinical Examination revealed a 25 x 25cm lump in the right flank with smooth surface, ballotable, minimal movement with respiration and extending towards right iliac fossa, not crossing the midline.

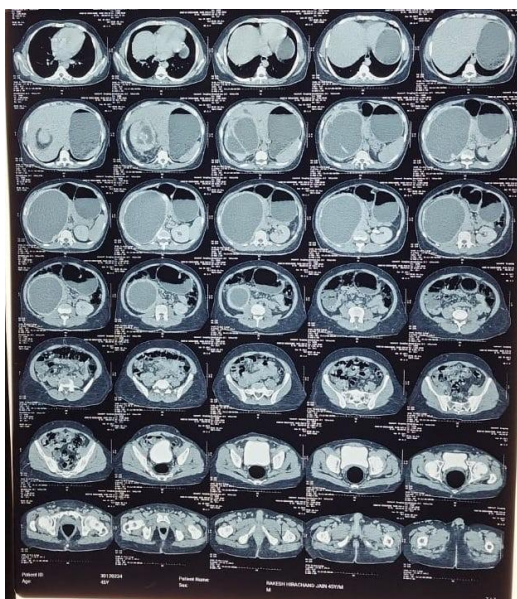

Fig. 1. Mass causing gastric outlet obstruction

USG of the abdomen revealed a large 20 x 18 cm sub-hepatic mass. CECT Abdomen and pelvis revealed the right kidney replaced by a

cystic structure measuring 17 x 14 x 20 cm with mild enhancing septa with surrounding fat stranding and prominent vessels. Right ureter is not visualised, gross stomach dilatation due to secondary mass effect. 18-FDG PET-CT revealed it to be a localized lesion.

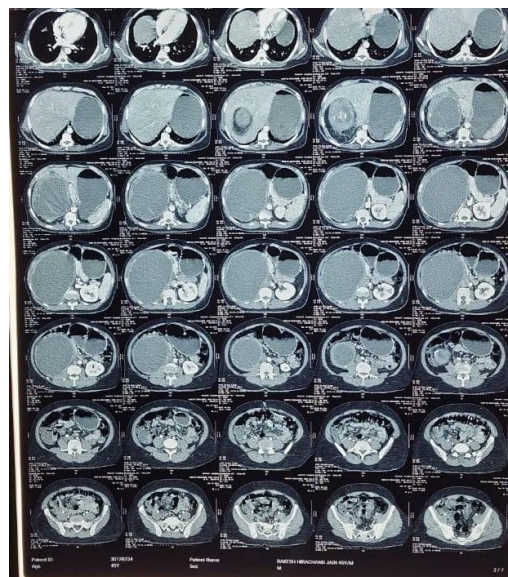

Fig. 2. CT Image of large mass arising from renal parenchyma

Patient underwent an exploratory laparotomy with right nephrectomy and the mass was excised in-toto. Intraoperatively, a large mass was noted arising from the right kidney with adhesion noted to the ascending and transverse colon, tumour was abutting the IVC. Careful adhesiolysis was done, right ureter was transected and the specimen was delivered and sent for HPE.

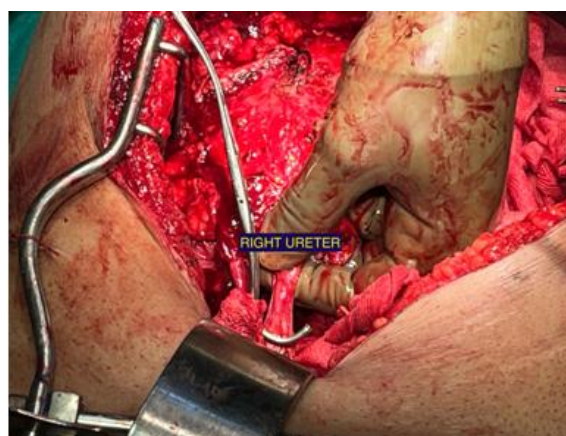


Fig. 3. Right Ureter Identified and Transected

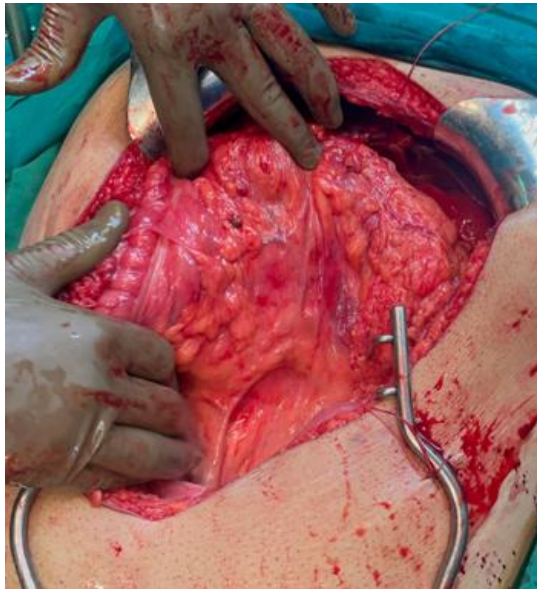

Fig. 4. Adhesion of Viscera to Mass

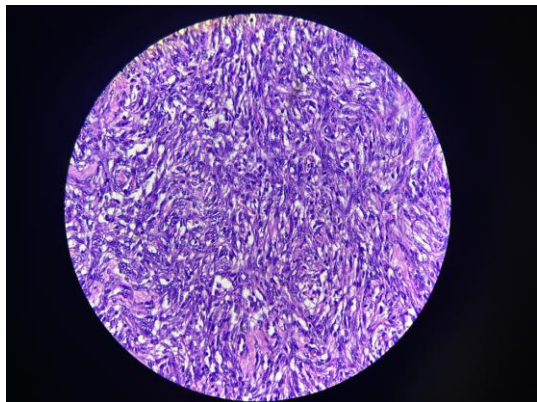


Fig. 5. HPE Showing Bundles of spindle cells in clusters (H&E 40x)

Histopathology, revealed a tumour composed of spindle cells arranged in storiform pattern, cells showing scanty cytoplasm with oval hyperchromatic nuclei, vascular tumour emboli detected with hemangiopericytomatous vasculature. Large areas of hyalinisation & foci of calcification were evident.

3. DISCUSSION

Primary Renal sarcomas are rare neoplasms of the kidney and comprise of only one percent of malignant renal tumours. Most frequently occurring renal sarcoma is leiomyosarcoma in 40-60% of cases reported [1]. "Other neoplasms that involve the kidney include rhabdomyosarcoma, malignant fibrous histiocytoma, fibrosarcoma, angiosarcoma,

hemangiopericytoma, Liposarcoma and rarely synovial sarcoma" [6-11].

"With limited data and less follow-up time these tumors have shown a generally aggressive behavior" [1-3]. Microscopically, these tumors show mitotically active, monomorphic plump spindle fascicles. "Synovial sarcomas are microscopically grouped into; monophasic synovial sarcoma (MSS), biphasic synovial sarcoma (BSS) and poorly differentiated synovial sarcoma (PDSS) which carries a poor prognosis. The MSS cell variant consists of spindle cells with no evidence of differentiation. MSS is more frequent than the biphasic form" [11]. Radiotherapy can also be considered in a patient having a localized disease. A combination of doxorubicin with ifosfamide has been tried for an advanced disease combined with radical nephrectomy. However, currently, there are no clear-cut guidelines regarding the use of chemotherapy for patients with PRSS. Further studies are required to develop a standardized management protocol.

4. CONCLUSION

Primary Renal Synovial Sarcoma is a rare tumour and is diagnosed on Histopathology combined with immune-histochemistry and genetic analysis. Surgical excision with tumour-free margins remains the mainstay of treatment. Radiotherapy has proven to be useful as an adjuvant therapy in presence of local spread of tumour. Chemotherapy may be beneficial when distant metastases is present. However, more studies are required for standardizing the management of this rare disease for better prognosis and results.

CONSENT

As per international standard or university standard, patient(s) written consent has been collected and preserved by the author(s).

ETHICAL APPROVAL

As per international standard or university standard written ethical approval has been collected and preserved by the author(s).

COMPETING INTERESTS

Authors have declared that no competing interests exist.

REFERENCES

1. Zia Z, Al Shakarchi J, Bagree R. Case report: primary synovial sarcoma of kidney. *The Internet Journal of Urology*. 2007; 2:1528–32. [Google Scholar]
 2. Park SJ, Kim HK, Kim CK. A case of renal synovial sarcoma: Complete remission was induced by chemotherapy with doxorubicin and ifosfamide. *Korean J Intern Med*. 2004;19:62–5. [PMC free article] [PubMed] [Google Scholar]
 3. Argani P, Faria PA, Epstein JI. Primary renal synovial sarcoma: Molecular and morphologic delineation of an entity previously included among embryonal sarcomas of the kidney. *Am J Surg Pathol*. 2000;24:1087–96. [PubMed] [Google Scholar]
 4. Tsai YK, Lin CJ, Wang JH,. Primary synovial sarcoma of the kidney: A case report. *Chin J Radiol*. 2004;29:359–63. [Google Scholar]
 5. Murphy WM, Beckwith JB, Farrow GM. Atlas of tumor pathology. Washington, DC: AFIP. Tumors of the kidney, bladder, and related urinary structures. 1994;219–30. (3rd series). Fascicle 11. [Google Scholar].
 6. Mancuso T, Mezzelani A, Riva C, et al. Analysis of SYT-SSX fusion transcripts and bcl-2 expression and phosphorylation status in synovialsarcoma. *Lab Invest*. 2000;80:805–13. [PubMed] [Google Scholar]
 7. Kawai A, Woodruff J, Healey JH, et al. SVT-SSX gene fusion as a determinant of morphology and prognosis in synovial sarcoma. *N Engl J Med*. 1998;338:153–60. [PubMed] [Google Scholar]
 8. Skytting B, Nilsson G, Brodin B, et al. A novel fusion gene, SYT-SSX4, in synovial sarcoma. *J Natl Cancer Inst*. 1999;91:974–5. [PubMed] [Google Scholar]
 9. Paulino AC. Synovial sarcoma prognostic factors and patterns of failure. *Am J Clin Oncol*. 2004;27:122–7. [PubMed] [Google Scholar]
 10. Huned D, Kam JH, Lee LS, Tiwari RV. Primary renal synovial sarcomapresenting with a retroperitoneal bleed. *BMJ Case Rep*. 2021;14(3):e237099. DOI: 10.1136/bcr-2020-237099. PMID: 33737273; PMCID: PMC7978333.
 11. Bakhshi GD, Khan AS, Shaikh AS, Khan MA, Khan MA, Jamadar NM. Primary renal synovial sarcoma. *Clinics and Practice*. 2012;2(2):e44.
-