

Mesodiverticular Band of Meckel's Diverticulum Causing Strangulated small bowel

A case report

Abstract

The Mesodiverticular band is an embryologic remnant of the vitelline artery which provides the arterial supply to the Meckel's Diverticulum. In the event of an error of involution a patent or non-patent arterial band persist and extend from the mesentery to the apex of the Meckel's Diverticulum. This results in the formation of a snare-like aperture through which bowel loops can herniate and become obstructed. We report a case of 50 years old male patient, show presented with strangulation and gangrene of a small bowel caused by Mesodiverticular band of the Meckel's Diverticulum. He presented with severe pain in abdomen distension of abdomen and vomiting. Emergency explorative laparotomy revealed gangrene of Meckel's Diverticulum along with adjacent ileal segment caused by Mesodiverticular band of Meckel's Diverticulum. The Mesodiverticular band was released from the ileal mesentery and the gangrenous ileal segment with Meckel's Diverticulum was resected and end to end ileo-ileal anastomosis was performed.

Keynotes

Mesodiverticular band, Meckel's Diverticulum, Strangulation.

Introduction

“Mesodiverticular band, is a rare congenital intestinal malformation. It originates from the embryonic remnant of vitelline artery and is usually associated with Meckel's Diverticulum. Persistent Mesodiverticular band may cause small bowel Strangulation due to forming an internal hernia by trapping the loops of bowel. This abnormally is associated with high mortality”. [1,2,3,4,5]

“The lifetime risk of complication of Meckel's Diverticulum is estimated at 4% to 6% one of them is intestinal obstruction which is more common presentation among adults. As the preoperative diagnosis of intestinal obstruction which is caused by Mesodiverticular band is difficult” [5]. “It is associated with high mortality and morbidity. Early diagnosis and immediate surgery will prevent the strangulation and bowel gangrene. Therefore, Mesodiverticular band which is one of the complication of Meckel's Diverticulum should be kept in mind”. [5]

“Small bowel obstruction due to Mesodiverticular band of Meckel's Diverticulum can be managed by laparoscopic surgery with the help of harmonic scalpel and endo-GIA linear stapler. Endo-staplers and reduces the mortality/morbidity and hospitalization”. [8,9]

Case report

A 50 years-old male patient presented with severe pain in abdomen, distension, vomiting and constipation since 3 days. Patient was admitted at Jatal hospital and research center on 18/02/2015. On physical examination, revealed abdominal distension, tenderness and guarding with exaggerated bowel sounds, suggestive of small bowel Strangulation. Plain x-ray abdomen, ultrasonography and a clinical diagnosis of acute intestinal obstruction was confirmed and patient taken up explorative laparotomy. After Opening the abdomen, 200-300 cc hemorrhagic fluid was aspirated. On inspecting the small bowel, there was strangulation of the ileal segment which was gangrenous along with gangrenous Meckel's Diverticulum. Meckel's Diverticulum measuring 7x3 cm and tip of the Meckel's Diverticulum attached to Mesodiverticular band. Dilated loops of ileum were noted and tight Mesodiverticular band of Meckel's diverticulum causing strangulation and gangrene of small bowel. The band was cut with electric cautery, and gut was de-rotated. Mesodiverticular band of Meckel's diverticulum, creates a snare-like opening and internal hernia through which bowel loops herniate and become strangulated (Fig 1, 2,). Resection of small bowel gangrenous segment of 20 cm in length along with Mesodiverticular band of Meckel's Diverticulum was done and healthy ileo-ileal segment anastomosis

performed by hand sewn, two layered method. (Fig 3,4). The post-operative period was uneventful and patient discharged home after 8 days of surgery.

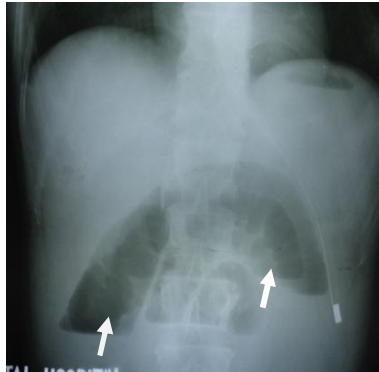


Figure 1- Plain X-ray Abdomen
E/o Small bowel obstruction

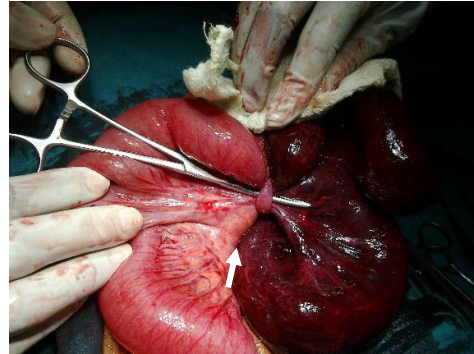


Figure 2- Intra operative photograph
Showing Mesodiverticular Band of MD
with small bowel gangrene

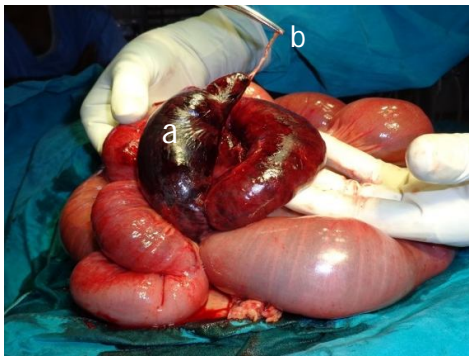


Figure 3- Intra operative photograph
Showing a- Gangrenous M.D Size 7x3 cm
and b- Mesodiverticular Band

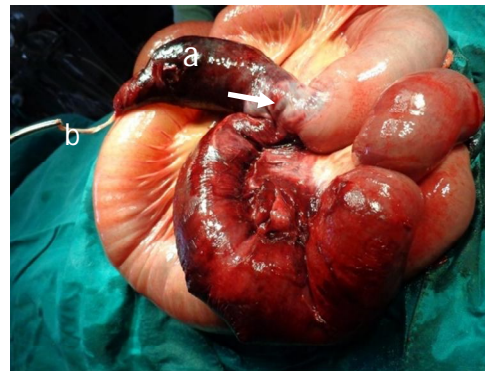

Figure 4- Intra operative photograph
Showing a- Gangrenous MD, b- Mesodiverticular Band,
and c- small bowel gangrene

Discussion

“Meckel’s Diverticulum is the most common congenital anomaly of the gastrointestinal tract. The most common complication of Meckel’s Diverticulum in pediatric population is lower gastrointestinal bleeding while the most common complication in adult is small bowel obstruction. Life time risk of complication in Meckel’s Diverticulum represents of 4-6%. Rarely Meckel’s Diverticulum is complicated by a Mesodiverticular band, which is believed to be a remnant of vitelline artery. When it causes intestinal strangulation and it is associated with high mortality”. [1,2,3,4,5]

“Less frequently, we may encounter an axial torsion of Meckel’s Diverticulum and segmental volvulus small bowel volvulus secondary to axial torsion of ileum or small bowel obstruction due to ileal compression by the band associated with axial torsion of Meckel’s Diverticulum”. [7,11]. Development of small bowel volvulus around the band or compression of the small bowel by the band result in small bowel obstruction. In our case obstruction caused by both mechanisms. Small bowel obstruction and strangulation due to Mesodiverticular band of Meckel’s Diverticulum is one of the rarest complication of Meckel’s Diverticulum.

“Recently laparoscopy has been tried as useful diagnostic and therapeutic tool for a patient with small bowel obstruction due to Mesodiverticular band”. [8,9]

Conclusion

Mesodiverticular band of Meckel’s Diverticulum causing small bowel strangulation in adults is a rare case. Preoperative diagnosis is challenging due to rarity of the condition. Early surgery is important to prevent strangulation and gangrene of the bowel.

Ethical Approval:

As per international standard or university standard written ethical approval has been collected and preserved by the author(s).

Consent

As per international standard or university standard, patient(s) written consent has been collected and preserved by the author(s).

References

1. Prasad Brahme, Divakar Jain, Vishal Narkhed, Rajesh Mahey, Satish B. Dharap. Mesodiverticular band of Meckel's diverticulum, A rare cause of strangulated small bowel obstruction in an adult: A case report. International journal of scientific research volume-7[issue -9] September -2018, Print ISSN No.2277-8179
2. Kuru, Serdar & Bulu, Hakan & Kismet, Kemal & Aydin, Altan & Yavuz, Alper & Tantoglu, Utku & Boztas, Arzu & Coskun, Ali. (2013). Mesodiverticular Band of Meckel's Diverticulum as a Rare Cause of Small Bowel Obstruction: Case Report and Review of the Literature. *Viszeralmedizin: Gastrointestinal Medicine and Surgery*. 29. 401-405. 10.1159/000357533XXX.
3. Dr. Mrigendra Singh¹ , Dr. Subhash Chawla² , Dr. Shivam Sharma³ , Dr. Himanshu Tanwar⁴ , Dr. Shobhit Maheswari⁵ Post Graduate Student¹ , Professor and Head MIS² , Senior Resident³ , Post Graduate Student⁴ , Post Graduate Student⁵ Department of Minimal Invasive Surgery, M. M. I. M. S. R, Mullana, Ambala, Haryana, India, Small Bowel Obstruction Due to Mesodiverticular Band of Meckel's Diverticulum: A Rare Presentation DOI: 10.21275/SR22111121120
4. Sumer A, Kemik O, Olmez A, Dulger AC, Hasirci I, Iliklerden U, Kisli E, Kotan C. Small Bowel Obstruction due to Mesodiverticular Band of Meckel's Diverticulum: A Case Report. *Case Rep Med*. 2010;2010:901456. doi: 10.1155/2010/901456. Epub 2010 Aug 9. PMID: 20814563; PMCID: PMC2931429.
5. Hüseyin Emre Arslan, Sezgin Zeren, Mehmet Fatih Ekici, Mustafa Cem Algin İntestinal Obstrüksiyonun Nadir Bir Nedeni: Mezodivertiküler Band ARare Cause of Intestinal Obstruction: Mesodiverticular Band
key DOI: 10.4274/tjcd.galenos.2020.2020-1-4 Turk J Colorectal Dis 2020;30:138-142
6. Aziz Sumer,1Ozgun Kemik,1Aydemir Olmez,1A. Cumhuriyet Dulger,2Ismail Hasirci,1Umit Iliklerden,1Erol Kisli,1and Cetin Kotan Small Bowel Obstruction due to Mesodiverticular Band of Meckel's Diverticulum: A CaseReport. <https://doi.org/10.1155/2010/901456>
7. Bamarni, Sahand MD; HungFong, SuySen MD; Mino, Jeffrey MD, FACS; Misra, Subhasis MD, MS, FACSIFS: Short Reports 6(4):p e33, October/December 2021. | Systematic review of mesodiverticular band: a rare cause of small bowel strangulation and hemoperitoneum in adults
DOI: 10.1097/SR9.0000000000000033
8. Reji Chandran, Small Bowel Obstruction Due to Mesodiverticular Band of Meckel's Diverticulum Managed by Laparoscopy: A Rare Case Report Abstract Volume: 5 Issue: 3 ISSN:
9. Takura K, Takayama S, Kani H, Sakamoto M, Ishikawa K, Katada T. A case of intestinal obstruction caused by a mesodiverticular band in Meckel's diverticulum with ectopic pancreas treated by

laparoscopic surgery. *Int J Surg Case Rep.* 2021 Nov;88:106557. doi: 10.1016/j.ijscr.2021.106557. Epub 2021 Nov 2. PMID: 34741859; PMCID: PMC8577079.

10. Sethi NT, Chauhan A, Tiwari S. Meckel's Diverticulum with Mesodiverticular Band : An Unusual Presentation. *Med J Armed Forces India.* 2009 Jan;65(1):75-6. doi: 10.1016/S0377-1237(09)80065-8. Epub 2011 Jul 21. PMID: 27408200; PMCID: PMC4921525