

## ORIGINAL RESEARCH ARTICLE

### **A STUDY OF MORPHOLOGICAL VARIATIONS OF CAROTID BIFURCATION AND BRANCHING PATTERN OF EXTERNAL CAROTID ARTERY IN ADULT NIGERIAN CADAVERS**

#### **ABSTRACT**

**Background:** Understanding the morphological differences in the branching pattern of carotid vessels has played a significant role in successful surgical operations around the neck region. This study aimed at evaluating the morphological variants of the external carotid artery (ECA) in relation to its carotid bifurcation (CB) and its branches. **Method:** After obtaining twenty-five (25) hemi-necks and later dissected, 25 ECAs were examined (13 right and 12 left). The patterning of the superficial branches and CB from common carotid artery were photographed and later analyzed in terms of variations of origin. **Results:** CB appeared as V-shaped in 24 cases (96%). Superior thyroid artery (STA) originated majorly from both the ECA (40.91%) and from the CB (36.36%). The percentage distributions of occurrence of arterial branch origins from ECA in both hemi-neck sides are as follows; ascending pharyngeal (85.71%), lingual (84%), facial (88%) and occipital (95%). **Conclusion:** In adult Nigerian cadavers, the V-shaped carotid bifurcation pattern is more common and the CB was more prevalent at the level of the upper border of thyroid cartilage. Higher numbers of origins were observed more in STA compared to other superficial branches of ECA.

**Keywords:** External carotid artery, carotid bifurcation, morphological variations.

#### **INTRODUCTION**

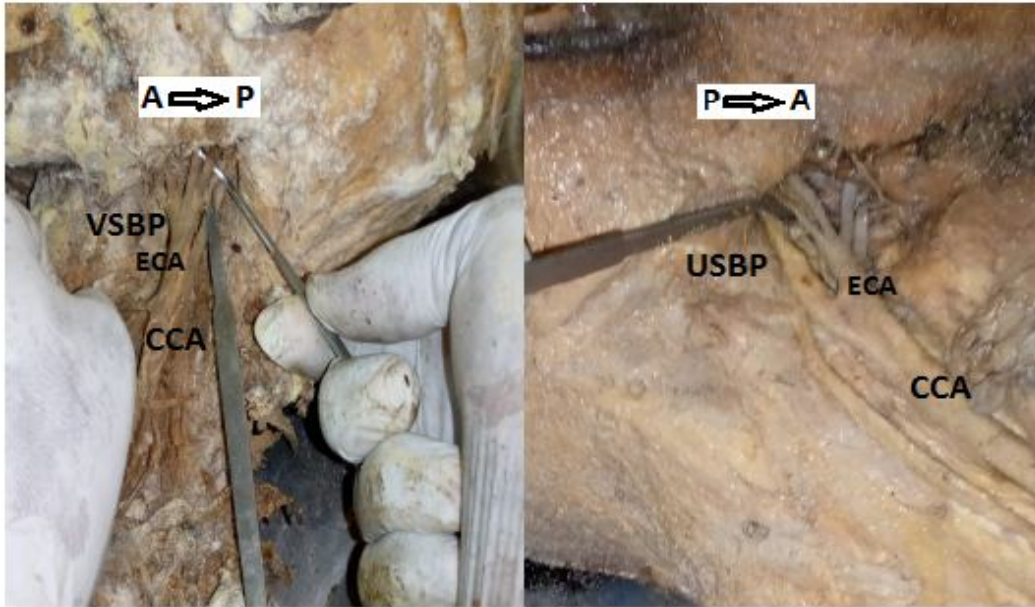
“The external carotid artery (ECA) is arguably the most relevant final branches of the common carotid artery (CCA) as it forms the principal arterial supply to systems within the front of the neck and the face” (Chaurasia, 2006). “The ECA has 8 named branches dispensed to the head, neck, and face. The superior thyroid (STA), lingual (LA), and facial arteries (FA) arise from its anterior aspect, the occipital (OA) and posterior auricular arteries (PAA) from the posterior aspect and the ascending pharyngeal artery (APA) is the only branch which arises medially. The maxillary and superficial temporal arteries are their terminal branches” (Standring, 2008). “The knowledge of variations of ECA and its branches and their recognitions during diagnostic imaging are useful for vascular procedures like

carotid endarterectomy, an extracranial or intracranial bypass in occlusive cerebrovascular diseases, skull base tumors and aneurysms” (Gluncicet *et al.*, 2001). “Furthermore, the ECA and its branches are used for intra-arterial infusion chemotherapy of head and neck cancer” (Li *et al.*, 2017).

Anatomical variations of the ECA have been reported in various researches in parts of the world (Mata *et al.*, 2012; Acaret *et al.*, 2013; Rao *et al.*, 2014; Ovhalet *et al.*, 2016; Dakare and Bhuiyan, 2018). Arguably, no study has been done on the morphological patterns of the ECA in adult Nigerian cadavers. This study aimed to evaluate the morphological variants of the ECA about its carotid bifurcation and its branches.

## **MATERIALS AND METHODS**

The study was carried out on thirteen (13) adult formalin-fixed cadavers of undetermined age. Twenty-six (26) hemi-necks were obtained and twenty-five (25) were dissected for this study. Therefore, 25 external carotid arteries (ECAs) were examined, 13 right and 12 left ECAs. The dissected specimens were procured from the Departments of Anatomy of the University of Port Harcourt and Bayelsa State Medical University, both located in South-Southern Nigeria. Only adult formalin-fixed cadavers with no traumatic or surgical evidence in the neck region were used for this study. The hemi-heads were dissected to expose the arterial branches of the head and neck. The arrangement of the superior thyroid, lingual and facial arteries was photographed and later analyzed in terms of variations of origin. Exposure to the ECA and its branches was achieved following dissection procedures as provided by Cunningham's manual of practical anatomy volume 3.



**Figure 1.** Bifurcation pattern of the common carotid artery; V and U shaped bifurcation patterns (**VSBP** = V-shaped Bifurcation Pattern, **USBP** = U-shaped Bifurcation Pattern, **A** = Anterior, **P** = Posterior)

## RESULTS

The result was presented in two categories, the findings related to; carotid bifurcation and superficial branches of the external carotid artery. All data were categorized according to the sides (right and left).

### I. ECA in relation to its point of carotid bifurcation (CB)

The morphological characteristics of the CB were studied in 25 cases. It was found that the CB appeared as the letter V in 24 cases (96%) and the letter U in 1 case (4%). It was found most frequently in 21 cases (84%), that the CB was at the level of the upper border of thyroid cartilage (normal CB) and in 4 cases (16%) it was above the upper border of thyroid cartilage (high CB).

### II. ECA in relation to its branches

a) *Superior thyroid artery (STA)*: The morphology of STA was studied in 22 cases. It was found that the STA originated; from the CCA in 4 cases (18.18%) of which 1 case was on the right (4.54%) and 3 cases on the left (13.64%), from the CB in 8 cases (36.36%) with 6 cases on the right (27.27%) and 2 cases on the left (9.09%), it had a common trunk with the lingual

artery called thyrolingual trunk (TLT) in 1 case on the right (4.54%), and from the ECA in 9 cases (40.91%) of which 2 cases on the right (9.09%) and 7 cases on the left (31.82%).

**Table 1. Percentage distribution of sites of origin of STA on the right and left sides**

Site of origin of STA	No. of Right (%)	No. of Left (%)	Total (%)
From the ECA	2 (9.09%)	7 (31.82%)	9 (40.91%)
From the CCA	1 (4.54%)	3 (13.64%)	4 (18.18%)
From the CB	6 (27.27%)	2 (9.09%)	8 (36.36%)
From TLT	1 (4.54%)	-	1 (4.54%)


*STA = Superior Thyroid Artery, ECA = External Carotid Artery, CCA = Common Carotid Artery, CB = Carotid Bifurcation, TLT = Thyrolingual Trunk, No. = Number*

b) *Ascending pharyngeal artery (APA):* The morphology of APA was studied in 7 cases. It took origin from the ECA in 6 cases (85.71%) of which 2 cases were on the right (28.57%) and 4 cases on the left (57.14%). It had a common trunk with the OA in 1 case on the right (14.29%).

**Table 2. Percentage distribution of sites of origin of APA on the right and left sides**

Site of origin of APA	No. of Right (%)	No. of Left (%)	Total (%)
From the ECA	2 (28.57%)	4 (57.14%)	6 (85.71%)
From a common trunk with OA	1 (14.29%)	-	1 (14.29%)

*APA = Ascending Pharyngeal Artery, ECA = External Carotid Artery, OA = Occipital Artery*




**Figure 2.** A left hemi-neck showing the common carotid artery (CCA) and its branches; superior thyroid artery (STA), external carotid artery (ECA), internal carotid artery (ICA), lingual artery (LA), facial artery (FA), and ascending pharyngeal artery (APA).

c) *Lingual artery (LA)*: The morphology of LA was studied in 25 cases. It took origin from the ECA in 21 cases (84%) with 9 cases on the right (36%) and 12 cases on the left (48%). It had a common trunk with the FA called linguofacial trunk (LFT) in 2 cases on the right (8%), a common trunk with STA called thyrolingual trunk (TLT) in 1 case on the right (4%), and was superimposed with the facial artery (being posterior) in 1 case on the right (4%).

**Table 3. Percentage distribution of sites of origin of LA on the right and left sides**

Site of origin of LA	No. of Right (%)	No. of Left (%)	Total (%)
From the ECA, separately	9 (36%)	12 (48%)	21 (84%)
From TLT	1 (4%)	-	1 (4%)
From LFT	2 (8%)	-	2 (8%)
Superimposed with the FA from the ECA	1 (4%)	-	1 (4%)

*LA = Lingual Artery, ECA = External Carotid Artery, TLT = Thyrolingual Trunk, LFT = Linguofacial Trunk, FA = Facial Artery*



**Figure 3.** A right hemi-neck showing the common carotid artery (CCA) and its branches; superior thyroid artery (STA), external carotid artery (ECA), internal carotid artery (ICA), lingual artery (LA), thyrolingual trunk (TLT).

d) *Facial artery (FA)*: The morphology of the FA was studied in 25 cases. It took origin from the ECA in 22 cases (88%) of which 10 cases were on the right (40%) and 12 cases on the left (48%). It had a common trunk with the lingual artery called the linguofacial trunk in 2 cases on the right (8%) and was superimposed with the lingual artery (being anterior) in 1 case on the right (4%)

**Table 4: Percentage distribution of sites of origin of FA on the right and left sides**

Site of origin of FA	No. of Right (%)	No. of Left (%)	Total (%)
From the ECA, separately	10 (40%)	12 (48%)	22 (88%)
From LFT	2 (8%)	-	2 (8%)
Superimposed with the LA from the ECA	1 (4%)	-	1 (4%)

*LA = Lingual Artery, ECA = External Carotid Artery, LFT = Linguofacial Trunk, FA = Facial Artery*

e) *Occipital artery (OA)*: The morphology of the OA was studied in 20 cases. It took origin from the ECA in 19 cases (95%) with 9 cases on the right (45%) and 10 cases on the left (50%). It had a common trunk with the ascending pharyngeal artery in 1 case on the right (5%).

**Table 5: Percentage distribution of sites of origin of OA on the right and left sides**

<b>Site of origin of OA</b>	<b>Right (%)</b>	<b>Left (%)</b>	<b>Total (%)</b>
From the ECA	9 (45%)	10 (50%)	19 (95%)
From a common trunk with APA	1 (5%)	-	1 (5%)

*APA = Ascending Pharyngeal Artery, ECA = External Carotid Artery, OA = Occipital Artery*

## **DISCUSSIONS**

“Knowledge about the various branching patterns of the external carotid artery is important during laryngectomy, thyroidectomy, and glossectomy. It helps to avoid complications during plastic and reconstructive surgeries of the head and neck region. It is also necessary to know these variations during preoperative selective arterial angiograms in case of head, and neck tumors, arterial embolization, and intra-arterial chemotherapy” (Sanjeev et al., 2010). The purpose of this study was to evaluate the morphological variants of the ECA about its carotid bifurcation and superficial branches.

### **I. ECA in relation to its point of carotid bifurcation (CB)**

“The CB is an important anatomical and surgical landmark requiring special mention in atherosclerotic plaque and its consequent management by carotid stenting and endarterectomy” (Michalinose *et al.*, 2016). Out of the 25 cases that were evaluated in this study, 21 (84%) of them showed that the CBs were found to be at the level of the upper border of the thyroid cartilage, which is the normal level of CB. This is in correlation with the report of Fontaine and Drizenko (1996) and Rouviere and Delmas (1997), that the CB is at the level of the intervertebral disc of C3 - C4, big cornu of the hyoid bone or the upper border of the thyroid cartilage. Cases of higher and lower carotid bifurcations, above and below the upper border of thyroid cartilage respectively, have been reported (Kopuz *et al.*, 1997; Gluncic *et al.*, 2001).

In 4 cases (16%) of the CBs examined in this study, the level of CB was found to be above the upper border of thyroid cartilage which is a higher level of CB. Higher levels of CB have been reported in studies done by Lucevet *et al.* (2000), Ito *et al.* (2006), Sanjeev *et al.* (2010), Al-Rafiahet *et al.* (2011), Mompeo and Bajo (2015) and Deepa *et al.* (2018). “A higher level of CB may cause further distal extension of plaque in cases of atherosclerotic plaque. Hence,

making standard approaches inadequate for plaque removal and arteriotomy repair” (Deepa *et al.*, 2018; Michaliniset *al.*, 2016; Hayashi *et al.*, 2005).

“Furthermore, a higher level of CB should caution surgeons regarding the proximity of the hypoglossal nerve and Superior cervical ganglion as well as possible STA origin from the CB” (Lo *et al.*, 2006; Kurkcuogluet *al.*, 2015). A lower level of CB below the upper border of thyroid cartilage has been reported by Lucevet *al.* (2000), Ito *et al.* (2006), Sanjeev *et al.* (2010), and Al-Rafiahet *al.*(2011). No lower level of CB was found in this study. CB was as low as intrathoracic bifurcation has also been reported by (Gailloudet *al.*, 2000; Gomez and Arnuk, 2013). A lower level of CB may be associated with Klippel-feil anomaly (Gailloudet *al.*, 2000) and may cause difficulties during surgeries like cervical discectomy (Gulsenet *al.*, 2009). Regarding previous similar studies, it can be deduced that a normal level of CB is more common, a higher level of CB is less frequent, and a lower level of CB is rarely seen, this correlate well with the present study.

The CB pattern was examined in 25 cases, in this study. It was found in 24 cases (96%) that the CB had a 'V-shaped pattern and a 'U' shaped pattern in 1 case (4%) (Figure 1). 'U' shaped patterns of CB were also reported by Gavrilidouet *al.* (2013), in their study on the morphological characteristics of the CB in 46 cases. They found most frequently in 24 cases (52.17% of cases), that the CB appears as the letter "V" and the letter "U" in 2 cases (4.35% of cases). From reference to previous similar studies and the results of this study, it may be noted that the 'U' shaped CB are less frequent.

**Table 6. Comparison of the percentage distributions of the carotid bifurcations (CB) in relation to ECA with previous studies**

Study	Year	Sample size	Country	Normal (%)	Higher (%)	Lower (%)
Lucevet <i>al.</i>	2000	40	Croatia	50	37.5	12.5
Ito <i>et al.</i>	2006	80	Japan	57.5	31.2	11.3
Sanjeev <i>et al.</i>	2010	74	India	56.76	16.22	27.02
Al-Rafiahet <i>al.</i>	2011	60	Saudi Arabia	48.3	46.6	5
Mompeo and Bajo	2015	38	Spain	63.15	36.85	-

Deepa <i>et al.</i>	2018	80	India	75	25	-
<b>Present study</b>	2023	25	Nigeria	84	16	-

## II. ECA in relation to its branches

“The branches of the ECA are the key landmarks for adequate exposure and appropriate placement of cross-clamps such that there is a fruitful elimination of plaque and the adverse effects of post-surgical procedures are highly reduced. Caution must be paid with ligation of blood vessels of the carotid triangle because if these blood vessels are not distinguished, this may have catastrophic consequences in cerebral circulation or it can cause bleeding in the region of the ECA” (Hayashi *et al.*, 2005; Delic *et al.*, 2010). “Knowledge about the various branching patterns of the external carotid artery is important during laryngectomy, thyroidectomy, and glossectomy. It helps to avoid complications during plastic and reconstructive surgeries of the head and neck region” (Dakare and Bhuiyan, 2018).

The superior thyroid artery (STA) is the surgical landmark for distinguishing the external carotid artery (ECA) from the internal carotid artery (ICA). The STA was found to originate from the ECA in 9 cases (40.91%), from CCA in 4 cases (18.18%), from CB in 8 cases (36.36%), and from a common trunk with the LA (thyrolingual trunk) in 1 case (4.54%) in this study. The variations in the origin of the STA are very important in surgery. During the process of ligating STA from the bottommost part of the ECA based upon related investigations, it is believed that surgeons are able to perform such surgical operations (Lo *et al.* 2006; Vásquez *et al.*, 2008). Regarding previous similar studies and the present study, it may be noted that the origination of the STA from above CB and at CB is more common and its origination from the CCA is less frequent, this correlates well with the present study.

**Table 7. Comparison of the percentage distributions of the superior thyroid artery (STA) in relation to ECA with previous studies**

Study	Year	Sample Size	Country	Prevalence of site of origin in %		
				Above CB	At CB	Below CB
Al-Rafiah <i>et al.</i>	2011	60	Saudi Arabia	3.3	76.7	18.3
Mata <i>et al.</i>	2012	36	Brazil	51.2	45.3	3.5
Lo <i>et al.</i>	2006	67	New	46.2	52	1.5

			Zealand			
Acaret <i>et al</i>	2013	200	Turkey	51	31	18
Ozgur <i>et al</i>	2009	40	Turkey	25	40	35
Dakareand Bhuiyan	2018	40	India	17.94	76.92	5.12
<b>Present study</b>	2023	25	Nigeria	45.46	36.36	18.18

In this study, the APA originated from the ECA in six cases. This similarity in anatomical variation was also observed by Al Rafiah *et al.* (2011) in 6.7% of cases. Although in line with radiographic studies done by Cappabianca *et al.* (2012) and Small *et al.* (2014), the APA originated from the CCA or the CB at 6.5% and 9.6%, respectively. Also, the origin of APA in the occipital artery (OA) was reported by Lappaset *et al.* (2002), Sanjeev *et al.* (2010), and Shivaprakash and Ashok (2022), having a prevalence of 20%, 24.32%, and 12%, respectively. In line with the current study, this pattern of origin was seen in 14.29% of the cases.

**Table 8. Comparison of the percentage distributions of the ascending pharyngeal artery (APA) in relation to ECA with previous studies**

Study	Year	Sample Size	Country	Prevalence of site of origin (common trunk with the OA) in %
Sanjeev <i>et al</i>	2010	74	India	20
Lappaset <i>et al</i>	2002	-	Greece	24.32
Shivaprakash and Ashok	2022		India	12
<b>Present study</b>	2023	25	Nigeria	14.29

Both the lingual artery (LA) and facial artery (FA) take their origin from the ECA in 21 cases (84%) and 22 cases (88%), respectively, while sharing a common trunk called the linguofacial trunk in 8% of them in this present study. This is in agreement with a similar study done by Anuradha and Chitra (2017) which found the prevalence of origins of both the LA and FA at the anteromedial surface of the ECA as a separate branch in 27 cases (90%) of

the 30 cases and both sharing a common trunk as the linguofacial trunk in 10% of the cases. Likewise, Sanjeev *et al.* (2010) reported that the lingual artery was found to arise from the anteromedial surface of the external carotid artery as a separate branch in 78.38% (29/37) of the cases and shared a common trunk in 7 cases (18.92%) with the facial artery (linguofacial trunk). Furthermore, the lingual artery arose from a common trunk with the facial as a linguofacial trunk in 14% of the cases by Lappas (2002) and in 7.5% of the cases by Ozgur *et al.* (2008). Comparably, the study by Sanjeev *et al.* (2010) showed that the facial artery was found to arise from the anteromedial surface of the external carotid artery as a separate branch in 81.08% (30/37) of the cases.

In this present study, the occipital artery (OA) took origin from the ECA in 19 cases (95%) with 9 cases on the right (45%) and 10 cases on the left (50%). This is in agreement with the study done by Charles *et al.* (2021), which showed that the occipital artery emanated from the ECA in all cases except one, where it took origin from the carotid bifurcation. The knowledge of OA as a branch of the ECA is well known. Suzuki *et al.* (2000) reported that both OA and ascending pharyngeal artery (APA) were separated from the ECA by the common trunk.

## CONCLUSIONS

The carotid bifurcation (CB) at the level of the upper border of thyroid cartilage (normal CB) is more prevalent, Higher CB above the upper border of the thyroid cartilage is less prevalent and lower CB below the upper border of the thyroid cartilage is the least prevalent. The V shaped carotid bifurcation is more common and the U shaped carotid bifurcation less is frequent.

The superior thyroid artery (STA) can take origin from the CCA (below CB), from the CB, and the ECA directly or indirectly through the common trunk with the lingual artery (LA). The origination of the STA above the CB and at the CB is more common.

The knowledge of the variations in the origin and levels of bifurcation of ECA and its branching patterns may be relevant towards avoiding complications during various surgical and radiological procedures.

Arguably, most studies are not without limitations. In this study, there was limited number of cadavers. Acquisition of human cadavers in Nigeria medical schools can be very challenging

and this limits the rate at which cadaveric studies are carried out in the country. Furthermore, only male cadavers were readily available for cadaveric examination. This makes it difficult to generalize the study results in a dimorphic Nigerian population.

### **Ethical Approval :**

This study was approved by the Research Ethics Committee of the University of Port Harcourt (UPH/CEREMAD/REC/MM71/008).

### **REFERENCES**

- 1) Acar M., Salbacak A., Sakarya M., Zararsiz I., Ulusoy M. (2013). The morphometrical analysis of the external carotid artery and its branches with multidetector computerized tomography angiography technique. *Int J Morphol.* 31:1407-14.
- 2) Al-Rafiah A., EL Haggagy A., Aal I., Zaki (2011) A. Anatomical study of carotid bifurcation and origin variations of the ascending pharyngeal and superior thyroid arteries. *Folia Morphol (Praha).* 70(1):47–55.
- 3) Anuradha, M., Chitra, S. (2017). A study of the common origin of lingual and facial artery from the external carotid artery. *International Journal of Anatomy Research.* 5(1): 3656-3658
- 4) Cappabianca, S., Scuotto, A., Iaselli, F., et al. (2012). Computed tomography and magnetic resonance angiography in the evaluation of aberrant origin of the external carotid artery branches. *Surgical and Radiologic Anatomy.* 34(5) 393–399
- 5) Charles, A.S., Rabi, S., Jain, A., Rana, P.K. (2021). Origin and branching pattern of external carotid artery – a cadaveric study. *European Journal of Anatomy.* 25(2): 187-196
- 6) Chaurasia BD (2006). *BD Chaurasia's human anatomy regional and applied dissections and clinicals; volume 3.* 4th edition. CBS publishers and distributors.
- 7) Dakare S., and Bhuiyan P. (2018). A Morphological Study of Branches of External Carotid Artery in Adult Human Cadavers. *Anatomical Society of India* 67. 162–165.
- 8) Deepa D., Minnie P., Tintu S. (2018). Variations in the origin of superior laryngeal artery. *Anat Cell Biol.* 49:254-8.

- 9) Delić J., Bajtarević A., Isaković E. (2010). Positional variations of the external and the internal carotid artery. *Acta Med Salin*;39:86-9.
- 10) Fontaine C. and Drizenko A. (1996). Les artères de la tête et du cou. (pp. 401-407). In: Chevrel J.P. *Anatomie clinique. Tête et cou*. Paris: Ed. Springer
- 11) Gailloud P., Murphy K., Rigamonti D. (2000). Bilateral thoracic bifurcation of the common carotid artery associated with Klippel-Feil anomaly. *AJNR Am J Neuroradiol*;21:941-4.
- 12) Gavrilidou P., Iliescu D., Baz R., Border P. (2013). Morphological characteristics of the external carotid artery. *ARS Medica tomitana*. 2(73).
- 13) Gluncic V., Petanjek Z., Marusic A., Gluncic I. (2001) High bifurcation of common carotid artery, anomalous origin of ascending pharyngeal artery and anomalous origin of ascending pharyngeal artery and anomalous branching pattern of external carotid artery. *Surg Radiol Anat* 23: 123-125.
- 14) Gomez CK, Arnuk OJ. (2013). Intrathoracic bifurcation of the right common carotid artery. *BMJ Case Rep*;2013:bcr2012007554.
- 15) Gulsen S, Caner H, Altinors N. (2009). An anatomical variant: low-lying bifurcation of the common carotid artery, and its surgical implications in anterior cervical discectomy. *J Korean Neurosurg Soc*. 45:32-4.
- 16) Hayashi, N., Hori, E., Ohtani, Y., Ohtani, O., Kuwayama, N., Endo, S. (2005). Surgical anatomy s of the cervical carotid artery for carotid endarterectomy. *Neurol. Med. Chir. (Tokyo)*, 45(1):25- 9;
- 17) Ito H, Mataga I, Kageyama I, Kobayashi K.(2006). Clinical anatomy in the neck region - The position of external and internal carotid arteries may be reversed. *Okajimas Folio AnatJpn*. 82(4):157–168.
- 18) Kopuz C., Turan R. & Tekat A. (1997). Unusual bifurcation-level variation of the left common carotid artery: anatomic presentation of a surgical case. *Bull. Assoc. Anat.* 81 (253), 13-14

- 19) Kurkcuoglu A, Aytekin C, Oktem H, Pelin C. (2015). Morphological variation of carotid artery bifurcation level in digital angiography. *Folia Morphol (Warsz)* 74:206-11.
- 20) Lappas DA, Kamberos SP, Gisakis IG, Takis CH, Lykaki G. Anatomic study of the variations in the origin of the branches of the external carotid artery. *Beta Medical Arts* 2002;81:28-31.
- 21) Li N, Fuwa N, Toyomasu Y, Takada A, Nomura M, Kawamura T et al. (2017). A novel external carotid arterial sheath system for intra-arterial infusion chemotherapy of head and neck cancer. *Cardiovasc InterventRadiol.* 40(7): 1099-1104.
- 22) Lo, A., Oehley, M., Bartlett, A., Adams, D., Blyth, P. and Al-Ali, S. (2006). Anatomical variations of the common carotid artery bifurcation. *ANZ J. Surg.*, 76(11):970-2.
- 23) Lucev N, Bobinac D, Maric I, Drescik I (2000) Variations of the great arteries in the carotid triangle. *Otolaryngol Head Neck Surg* 22: 590-591.
- 24) Mata Joao, Mata Fabiana, Marcio Souza, HisaoNishijo, Tales Ferreira (2012). Arrangement and prevalence of branches in the external carotid artery in humans. *IJAE.* 117(2):65-74.
- 25) Michalinos A, Chatzimarkos M, Arkadopoulos N, Safioleas M, Troupis T. (2016). Anatomical considerations on surgical anatomy of the carotid bifurcation. *Anat Res Int.* 2016: 1-8
- 26) Mompeo B, Bajo E. (2015). Carotid bifurcation: clinical relevance. *Eur J Anat.* 19:37-42
- 27) Ovhal, A.G., Ansari, M.M., Rajgopal, L. (2016). A cross sectional study of variations in the external carotid artery in cadavers. *Indian Journal of Clinical Anatomy and Physiology.* 3(3): 285-289
- 28) Ozgur, Z.; Govsa, F. & Ozgur, T.(2008) Assessment of origin characteristics of the front branches of the external carotid artery. *J. Craniofac. Surg.*, 19(4):1159-66.
- 29) Rao, N.S, Gangadhara, K.M., Rao, H.R.K. (2014). Trifurcation of external carotid artery and variant branches of first part of maxillary artery. *International Journal of Anatomy Research.* 2(3): 561-565.

- 30) Rouvière H. and Delmas A. (1997). Anatomie Humaine descriptive topographique et fonctionnelle. Tome 2. 14th edition. Paris: Ed. Masson. pp. 196-210.
- 31) Sanjeev I k, anita h, ashwini, Mahesh u. (2010). Branching pattern of external carotid artery in human cadavers. *Journal of clinical and diagnostic research*. 4(5):3128-3133
- 32) Shivaprakash, S., Ashok K.R. (2022). Study of Branching Pattern of External Carotid Artery. *International Journal of Anatomy Research*. 10(2): 8367-8371.
- 33) Small, J.E., Harrington, J. and Watkins, E. (2014). Prevalence of arterial branches arising from the extracranial internal carotid artery on CT angiography. *Surgical and Radiologic Anatomy*. 36(8) 789–793
- 34) Standring S.(2008). Gray's anatomy: Anatomical basis of clinical practice. 40th Edition. Edinburgh: Elsevier Churchill Livingstone.
- 35) Suzuki, T., Moriyama, T., Moriwaki, H., Yagihashi, A., Yajima, N. & Takahashi, G. (2000). Anomalous artery directly connecting the external and internal carotid arteries. *Annals of Anatomy*. 182(1): 59-63.
- 36) Vázquez, T.; Cobiella, R.; Marañillo, E.; Valderrama, F. J.; McHanwell, S.; Parkin, I. & Sañudo, J. R. (2008). Anatomical variations of the superior thyroid and superior laryngeal arteries. *Head Neck*, 31(8):1078-85.