

Original Research Article

PATTERNS OF COMPUTED TOMOGRAPHY UROGRAPHY FINDINGS IN RADIOLOGY DEPARTMENT OF A TERTIARY HOSPITAL IN RIVERS STATE: 2 YEARS RETROSPECTIVE STUDY.

ABSTRACT

Background: Computed tomography urography (CTU), is a radiological examination and has largely replaced traditional intravenous urography (IVU) as the gold standard in the imaging of the genitourinary tract, hence it is now used as a primary imaging technique to evaluate patients with diseases involving the urinary tract.

Objective: The aim of this study is to ascertain and document the indications as well as possible findings on CTU carried out on various patients sent to the Radiology department of a tertiary hospital in our environment.

Methods: A retrospective study and descriptive design was employed in this study. A total of 140 patient's data was used. A *P*-value below 0.05 was considered statistically significant.

Results: One-hundred and forty patients were studied over a 24-months period. The commonest age range is 41 to 50 years and also with most abnormalities. It also showed that more males presented for CTU than females. The most frequent indication for CTU is flank pain (31.4%, n=44). The most common finding in this study is hydronephrosis (39.3%, n=55) and it showed significant association with age (*P*-value=0.036). Stone is the next common finding with the inferior pole (n=23, 48.9%) as the commonest site for stones. Few congenital anomaly was noted with kinked

ureters (n=9, 50.0%) been the most common. Right sided renal cyst is more frequent than left (n=21, 44.7% vs n=20, 42.6%) and inferior pole is the most common location.

Conclusion CTU is the imaging modality of choice in evaluating the genitourinary system with the advantage of giving additional information. Flank pain is the most prevalent indication in this study. Hydronephrosis is the commonest finding with significant association with age.

Keywords: Computed Tomography Urography, Patterns, Findings.

INTRODUCTION

Computed tomography urography (CTU), is a radiological examination and has largely replaced traditional intravenous urography (IVU) as the gold standard in the imaging of the genitourinary tract, hence it is now used as a primary imaging technique to evaluate patients with diseases involving the urinary tract. CTU has a higher sensitivity for detecting upper tract disease than IVU, with a reported pooled sensitivity on metaanalysis of 96%, compared with the sensitivity of IVU of 50% to 60%. It is an examination that uses a CT scan and a special contrast medium or dye injected into a vein.

It gives both anatomical and functional information albeit with a higher radiation dose.[1] The urinary tract includes the kidneys, bladder and the ureters that carry urine from the kidney to bladder. CTU is most commonly performed as a three phase computed tomography technique used to evaluate the kidneys, ureter and urinary bladder.

The indications of CTU include; Trauma to the urinary system, infections- example recurrent urinary tract infections, congenital collecting system anomaly- examples renal tubular ectasia, megaureter, obstructive uropathy like hydronephrosis and hydroureter, neoplasms-

Comment [n1]: Kindly change 'and' to 'replace'.

Comment [n2]: Kindly restructure the sentence as following: 'with a reported pooled sensitivity of 96% on meta-analysis.'

Comment [n3]: Replace with such as

Comment [n4]: Replace with 'like'

examples Wilms tumour, renal carcinoma etc, acquired- examples stricture, calculi, obstructive uropathy, haematuria from the kidney, ureter or bladder.

Comment [n5]: Replace with including

Comment [n6]: Replace with like.

One advantage of CTU over IVU is that in the latter the image acquisition is multiple unlike in a CTU where acquisition of image is single. However, CTU demonstrates other abdominal structures better than IVU. CTU, is particularly helpful in cases of very small calculi as images are acquired in slices and so even the minutest details will not go unnoticed.

CTU has also shown a high sensitivity, specificity and accuracy for diagnosing diseases of the urinary tract and collecting system.[2] CT urogram uses X-rays to generate multiple images of a slice of the area in the part of the body being studied, including bones tissues and blood vessels.[3]

TECHNIQUE- Is a non-invasive radiological examination of the urinary tract. It is done by injecting an iodine based contrast solution into a vein in the hand or arm. The contrast flows into the kidneys, ureter and bladder outlining each of the structures. CT urogram makes use of ionizing radiation (X-rays) to generate multiple thin slice (5mm) images of the urinary system at specific time intervals starting just above the kidneys and ending just below the pubic bone. These images are then sent to a computer and are reconstructed into two dimensional (2D) and three dimensional (3D) images respectively.

PREPARATION – The patient is given an appointment. On arrival, patient will be asked to drink about 1000mls of water and not voiding approximately 90 minutes prior to examination, this is to ensure full bladder and better contrast. However, depending on patient's condition guidelines about eating or drinking before a CT urography may vary.

Comment [n7]: Kindly change as 'Which will ensure

A member of the healthcare team is to take a short medical /drug history from the patient. The questions includes;Any previous allergies particularly to iodine?, any previous severe reaction to X-ray dyes, if it is a female patient last normal menstrual history is important to rule out pregnancy, has patient had any previous illness?, is the patient on any medication like NSAIDS, oral hypoglycaemics, blood thinners etc, any history of asthma, heart disease, kidney disease or organ transplant?

Risks/ Complications–The procedure is generally safe however, the possible complications includes: Allergic reactions-Nausea, itching, hives, flushing or feeling of warmth.Pain- there could be pain and or swelling at injection sites.

Radiation hazard- A single CT urography exposure has minimal or no risk of secondary malignancy but multiple exposures could increase chances of developing cancers, not forgetting that the benefits of accurate diagnosis far outweighs the risk of radiation exposure.

AIMS/OBJECTIVES:To ascertain and document the indications as well as possible findings on CTU carried out on various patients sent to the Radiology department of a tertiary hospital in our environment.

This will also serve as statistical information that could be referred to by other researchers.

METHODOLOGY:The study was carried out **the** Radiology Department of RSUTH, sited at Port-Harcourt, Rivers State Nigeria.The records of all patients referred for CTU for various medical reasons between 1st January, 2021 and 31stDecember, 2022 were studied. The Biodata, indications for the investigation and the CTU findings were obtained and recorded.

Comment [n8]: Replace it with 'at'

Sample size calculation: A sample size of 140 was obtained based on alpha-level of 0.05, proportion of CTU utilization from a Nigerian study yielded 57.9%,^[4]precision level of 10%, and non-response rate of 15%, following the sample size formula for cross-sectional studies.^[5]

Comment [n9]: Kindly rephrase the sentence well.

Ethical approval is not considered necessary in this kind of study

Procedure for CT urography

Usually patient lies on their back on a couch attached to a CT scanner, although sometimes they may lie on their side or even prone. Straps and pillows may be used to maintain position and keep still during examination. A three phase scan is usually done at specific time intervals.

An intravenous (IV) line will be placed into a vein in the hand or arm through which the X-ray dye will be injected.

Prior to injection of the dye, a scan is done to acquire some images this is the unenhanced phase. This would enable the doctor detect calculi and or urinary tract abnormalities. On injection of about 80-100mls of iodine based contrast another scan is done immediately to outline soft tissues including the kidneys, nephrographic phase. The third and final image acquisition is done after 15minutes to properly demonstrate functionality of the kidneys, ureter and also outline the bladder, the mandatory excretory phase.

Inclusion criteria: Every patient sent to the Radiology department for computed tomography urography.

Exclusion criteria: Patients allergic to the contrast media being used.

Chronic renal failure patients, this group may need to do a baseline biochemical test to ascertain their renal clearance.

Data analysis: The IBM Statistical Package for Social Sciences (SPSS) version 21.0 for Windows was employed in statistical analysis. Tables and charts were used to display data as appropriate. Descriptive statistics employed means and standard deviation for numerical data, and absolute frequencies and percentages for categorical data. Frequencies and proportions were determined and comparisons across the two groups in the study performed using Chi Square/ Fisher's exact tests. A p-value below 0.05 was considered statistically significant.

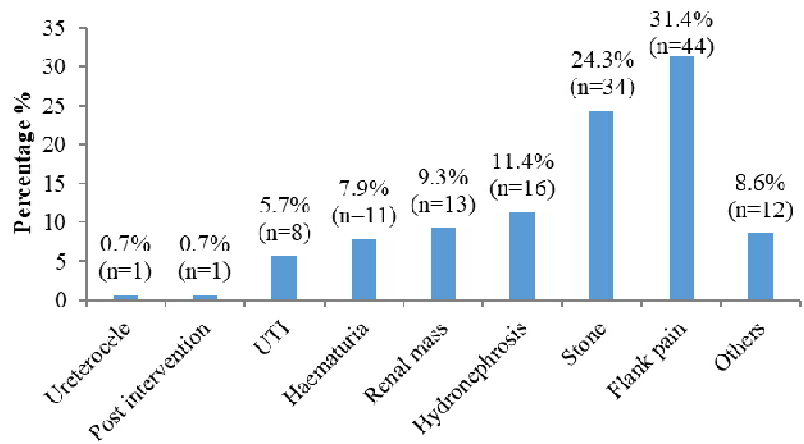
RESULTS

Mean age of the study population \pm SD Age = 44.71 \pm 15.31 years

Table 1: Age and gender characteristics of the study population

Variables	Frequency	Percentage
Age Category		
\leq 19 years	5	3.6
20 – 30 years	16	11.4
31 – 40 years	35	25.0
41 – 50 years	46	32.9
51 – 60 years	17	12.1
61 – 70 years	12	8.6
\geq 71 years	9	6.4
Gender		
Female	55	39.3
Male	85	60.7

The above table showed that the commonest age range is 41 to 50 years, followed by 31 to 40 years and least among the extreme ages (< 19 years or >71 years). It also showed that more males presented for CTU than females.



Indications for computed tomography urography

Figure 1: Bar chart showing indications for computed tomography urography (CTU) in the study population

Note - Some of the indications classified as others include; obstructive uropathy, pericardial effusion, ascites, genital tract malignancy and acute chronic kidney disease.

Figure 1 revealed that the commonest indications for CTU is flank pain (31.4%, n=44), followed by stone (24.3%, n=34), hydronephrosis 11.4%, n=16) and the least indications are ureterocele and post intervention (0.7%, n=1).

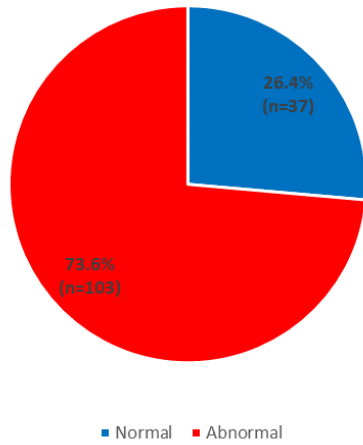


Figure 2: Pie chart showing the prevalence of abnormal findings on CTU among patients in the study.

This figure showed that of the 140 patients, 26.4%, n=37 had normal reports and 73.6%, n=103 had abnormal reports.

Table 2:CTU findings among the patients in the study

Variables	Frequency	Percentage
Stone		
Present	47	33.6
Absent	93	66.4
Level/location of stone (N=47)		
Superior moiety	12	25.5
Middle moiety	12	25.5
Inferior moiety	23	48.9
Hydronephrosis		
Present	55	39.3
Absent	85	60.7
Grade (N=55)		
1	2	3.6
2	18	32.7
3	13	23.6
4	19	34.5
5	3	5.5
Location of hydronephrosis		
Right	27	49.1
Left	22	40.0
Bilateral	6	10.9
Congenital anomaly (N=18)		
Extra renal pelvis	2	11.1
Bifid ureters	5	27.8
Kinked ureter	9	50.0
Malrotation	2	11.1

Table 2 displaced the most common findings in this study, with hydronephrosis (39.3%, n=55) as the commonest finding. Grade 4 is more frequent (n=19, 34.5%), grade 2 is commoner than grade 3(n=18, 32.7% vs n=13, 23.6%) while grade 5 and grade 1 are the least (n=3, 5.5% vs n=2,

3.6%) respectively. Right sided hydronephrosis was more common than left (n=27, 49.1% vs n=22, 40.0%). Bilateral hydronephrosis was noted in 10.9% (n=6) patients only.

Stone was seen in 47(33.65) of the study population in which the inferior pole (n=23, 48.9%) is the commonest site for stones while superior and middle poles have equal number each (n=12, 25.5%).

Few congenital anomalies were noted with kinked ureters (n=9, 50.0%) being the most common, followed by bifid ureters (n=5, 27.8%), then malrotation with extrarenal pelvis had equal prevalence of 11.1%, n=2 each.

UNDER PEER REVIEW

Table 3: Prevalence of abnormal CTU findings based on age and sex of the patients in the study

Variables	Normal CTU n (%)	Abnormal CTU n (%)	Total n (%)
Age Category			
≤19 years	1 (20.0)	4 (80.0)	5 (100.0)
20 – 30 years	5 (31.2)	11 (68.8)	16 (100.0)
31 – 40 years	11 (31.4)	24 (68.6)	35 (100.0)
41 – 50 years	16 (34.8)	30 (65.2)	46 (100.0)
51 – 60 years	1 (5.9)	16 (94.1)	17 (100.0)
61 – 70 years	1 (8.3)	11 (91.7)	12 (100.0)
≥71 years	2 (22.2)	7 (77.8)	9 (100.0)
Fisher's Exact = 8.280; p-value = 0.198			
Gender			
Female	13 (23.6)	42 (76.4)	55 (100.0)
Male	24 (28.2)	61 (71.8)	85 (100.0)
Chi-square = 0.363; p-value = 0.547			

Table 3 displaced that the age range with the highest abnormality is 41-50 years (n=30, 65.2%), followed by 31-40 years (n=24, 68.6%) then followed by 51-60 years (n=16, 94.1%) .

Table 4: Characteristics of renal cysts in the study

Variables	Frequency	Percentage
Prevalence of cysts		
Right	21	44.7
Left	20	42.6
Bilateral	6	12.8
Most prominent poles		
Inferior	23	48.9
Middle	12	25.5
Superior	12	25.5

Table 4 is showing that right sided renal cyst is more frequent than left (n=21, 44.7% vs n=20, 42.6%) while bilateral renal cyst (n=6, 12.8%). The most occurring location for renal cyst is inferior pole with middle and superior poles having equal incidence (n=12, 25.5%).

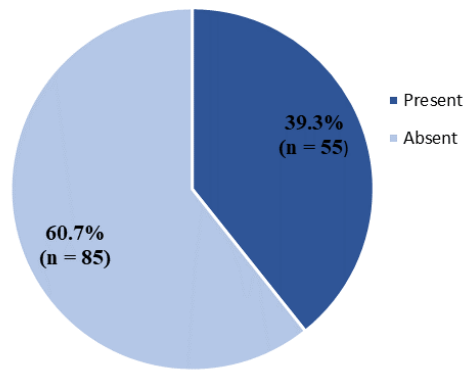


Figure 3: Pie chart showing prevalence of hydronephrosis among the study population

Comment [n10]: Brief comment on pie chart figure 3 need to be added.

Table5: Comparison of hydronephrosis based on age and sex in the study population

Variables	Hydronephrosis		Total n (%)
	Present n (%)	Absent n (%)	
Age Category			
≤19 years	2 (40.0)	3 (60.0)	5 (100.0)
20 – 30 years	9 (56.2)	7 (43.8)	16 (100.0)
31 – 40 years	11 (31.4)	24 (68.6)	35 (100.0)
41 – 50 years	8 (47.1)	9 (52.9)	17 (100.0)
51 – 60 years	9 (75.0)	3 (25.0)	12 (100.0)
61 – 70 years	4 (44.4)	5 (55.6)	9 (100.0)
≥71 years	4 (44.4)	5 (55.6)	9 (100.0)
Fisher's exact = 13.066; p-value = 0.036*			
Gender			
Female	22 (40.0)	33 (60.0)	55 (100.0)
Male	33 (38.8)	52 (61.2)	85 (100.0)
Chi-square = 0.019; p-value = 0.889			

*Statistically significant

The above table showed that ages 31 to 40 years had the highest incidence of hydronephrosis, followed by 20 to 30 and 51 to 60 years with equal values, then 41-50 years while the ages in the extremes had the least occurrence of hydronephrosis. There is a significant association with hydronephrosis and age with p-value of 0.036. The prevalence of hydronephrosis is more in

males than females, however there is no significant association with hydronephrosis and sex p-value=0.889.

Table 6: Congenital abnormalities

Variables	Congenital anomaly				Total
	Extra renal pelvis n (%)	Bifid ureters n (%)	Kinked ureter n (%)	Malrotation n (%)	
Age Category					
20 – 30 years	1 (33.3)	1 (33.3)	1 (33.3)	0 (0.0)	3 (100.0)
31 – 40 years	1 (20.0)	1 (20.0)	2 (40.0)	1 (20.0)	5 (100.0)
41 – 50 years	0 (0.0)	1 (25.0)	2 (50.0)	1 (25.0)	4 (100.0)
51 – 60 years	0 (0.0)	1 (33.3)	2 (66.7)	0 (0.0)	3 (100.0)
61 – 70 years	0 (0.0)	1 (50.0)	1 (50.0)	0 (0.0)	2 (100.0)
≥71 years	0 (0.0)	0 (0.0)	1 (100.0)	0 (0.0)	1 (100.0)
Fisher's Exact = 9.801; p-value = 1.000					
Gender					
Female	1 (8.3)	3 (25.0)	7 (58.3)	1 (8.3)	12 (100.0)
Male	1 (16.7)	2 (33.3)	2 (33.3)	1 (16.7)	6 (100.0)
Chi-square = 1.809;p-value = 0.777					

Table 5 revealed that extra renal pelvis is seen in 20 to 30 and 30 to 40 years only. Bifid ureters are noted across all ages except greater than or equal to 71years. Kinked ureters are seen in all age groups. Malrotation is noted in 31 to 40 and 41 to 50 years of age. Note no statistical

significance associations exist between ages and the abnormalities with p-value of 1.000. Equal sex distribution is seen in both extra renal pelvis and malrotation while female preponderance is noted in bifid and kinked ureters respectively. There is no significant association seen with p-value of 0.777.

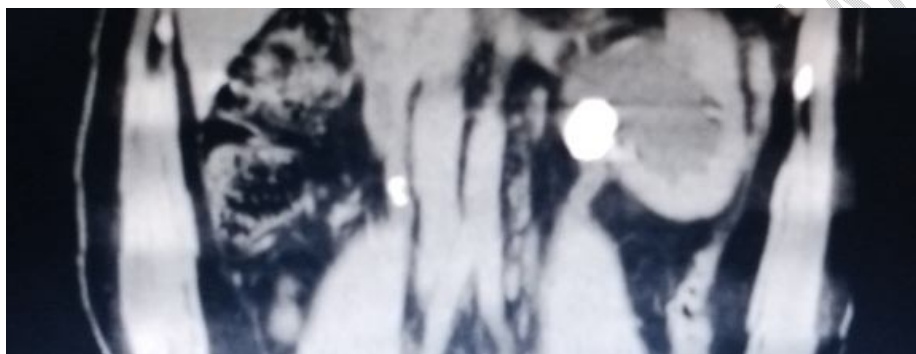

Figure 4 is a non-contrast coronal reformatted image showing an hyperdense lesion seen in the right ureter and at the left pelviureteric junction with associated marked ipsilateral pelvicalyceal system.

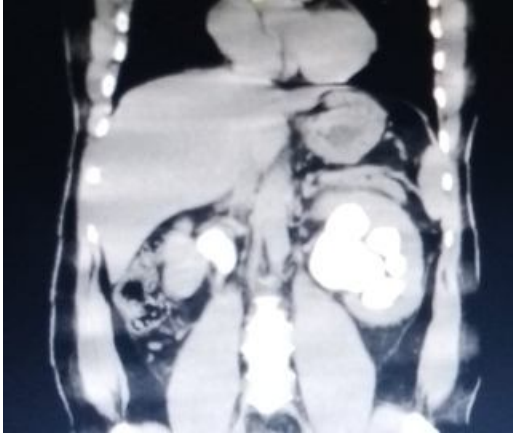


Figure 5 is a contrast enhanced coronal reformatted which is a follow up of the previous image, showing marked pelvicalyceal system on the left and moderate pelvic dilation on the right.

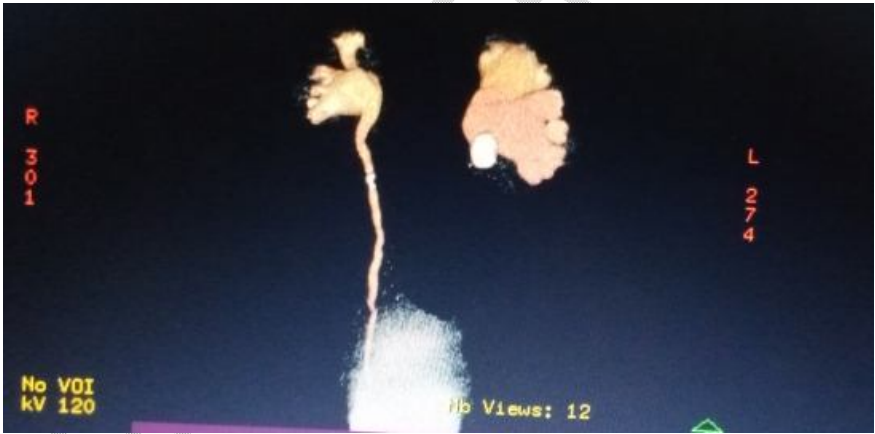

Figure 6 is a 3D volume rendered image showing the stones and hydronephrosis.

DISCUSSION

Imaging the urinary tract is taking a pivotal role not only in making diagnosis but also for interventional purposes. CT has established its role in this perspective. Due to the good imaging resolution and rapid examination time of helical CT scan, it has become an invaluable imaging modality for diagnosing urinary tract abnormalities. The radiation dose though high, but it has been reduced by using multiple detector CT scan, as a recent study showed that the radiation dose of CT urography was similar or just slightly greater than that of IVU.[6]

In our study, 140 patients with clinical manifestations of urinary tract disorders ~~that had CTU carried out on them, there were more men than women.~~ This possibly could be due to the fact that more men seek medical attention for urinary tract diseases than women in this part of the country, in contrast to Danjem SM et al study's which inferred[7] ~~that had more women than men in their study.~~

~~In contrast to the case study, Meenakumari et al[8], recorded more males with abnormal CTU findings than female patients,~~ this study showed more females with abnormal CTU findings (76.4%) than males (71.8%).

In this study patient from the age group 41-50years had more CTU 46 (100%) than any other age group, ~~this is in contrast to the study by Danjem SM et al.[7]Meenakumari et al[8] study, is in consonant with the case study with the age group of 41-50years having more CTU done than others.~~

Flank pain was the commonest indication in this study (31.4%). Closely followed by renal calculi (24.3%) and then hydronephrosis (11.4%), this is in contrast to Danjem SM et al[7] and

Comment [n11]: To improve the presentability of manuscript, kindly change into following sentences: 'In our study, 140 patients with clinical manifestations of urinary tract disorders underwent CTU with more number of males than females.'

Comment [n12]: Change into following sentence: 'in contrast to Danjem SM et al study's which inferred presence of a greater number of women than men.'

Comment [n13]:

Comment [n14]: Kindly restructure the sentences into following: ' Unlike the case study authored by Meenakumari, et al(8) which recorded greater males with the abnormal CTU finding, this study.....''

Comment [n15]: Kindly add this sentence: 'which was in consonant with case study by Meenakumari et, al(8), while contrasting with case study done by Danjem SM et, al(7)

Skip et al.[9] The least indications were ureterocele and post intervention (0.7%) which could probably be due to the fact that these conditions are rare in our environment.

The findings from CTU could be normal or abnormal, that is CTU could be negative or positive respectively. The positive findings could range from non-malignant to malignant conditions of the urinary tract effect of pathologies from adjacent structures.

Out of 140 patients that had CTU for clinical signs and symptoms of urinary tract diseases, 37 cases (26.4%) had normal (negative) findings while 103 cases (73.8%) had abnormal (positive) findings. The normal findings of (26.4%) of cases could possibly be due to the following reasons; inappropriate clinical history because some conditions like muscle spasm could mimic renal calculi, or inflammatory renal condition like pyelonephritis and so the patient could be referred for CTU, and hence a negative CTU finding. The abnormalities detected in (73.8%) of the study population, support the high sensitivity of CTU in the detection of urinary tract disorders.[9,10]

In this group of patients the commonest finding was hydronephrosis constituting 55 cases (39.3%), commoner on the right 27 cases (49.1%), with grade 4 been the commonest 19 cases (34.5%). This supports the fact that obstructive uropathy is common in our environment though with no definition of cause(s) on CTU. Furthermore, the study showed that obstructive uropathy was seen more amongst females 22 cases (40.0%) in the 31-40years age group (31.4%) probably because more females had abnormal CTU findings. This finding is in agreement with older/previous studies.[6,9] In this index study, there was significant association between age and hydronephrosis (p -value=0.036). The prevalence of hydronephrosis is more in males than females, however there is no significant association with hydronephrosis and sex (p -value=0.889). Other

findings on CTU, seen in this study include calculi (33.6%) more at the inferior moiety (48.9%), renal cysts more common on the right (44.7%), and at the inferior pole (48.9%).

Congenital anomalies like extra renal pelvis (11.1%), bifid ureters (27.8%), malrotation (11.1%) and kinked ureter (50.0%) with the latter been the most common anomaly was also seen. Note no statistical significance associations exist between ages and the abnormalities with p-value of 1.000. Equal sex distribution is seen in both extra renal pelvis and malrotation while female preponderance is noted in bifid and kinked ureters respectively. There is no significant association seen with p-value of 0.777.

CONCLUSION: CTU is the imaging modality of choice in evaluating the genitourinary system with the advantage of giving additional information.

STUDY LIMITATION: The study design is retrospective.

ETHICAL APPROVAL: Not required for this study.

REFERENCES

1. McTavish JD, Jinzaki M, Zou KH, Nwafel RD, Silverman SG. Multi-detector row CT urography: comparison of strategies for depicting the normal urinary collecting system. *Radiol* 2002;225(3):783-90. DOI:10.1148/radiol.2253011515.
2. Cowan NC. CT urography for haematuria. *Nat Rev.Urol.*2012;9(4):218-26(Pubmed)(Google Scholar). DOI:10.1038/nrurol2012.32.
3. Wang LJ, Wong YC, Huang CC, Wu CH, Hung SC, Chen HW, Multidetector CTU is more accurate than excretory urography for diagnosing transitional cell carcinoma of the

upper urinary tract in adults with haematuria. *J.Urol.* 2010;183(1):48-55.

DOI:10.1016/j.juro.2009.08.144

4. Omisano O, Bioku M, Williams O, Akinola O, Balogun F, Ikuero SA. 5-year review of the presentation and management of urolithiasis in a Nigerian teaching hospital. *J Surgery.* 2019;7(5):143-7.DOI:10.11648/j.js.20190705.16.

5. Katz DL, Wild DMG, Elmore JG, Lucan SC. Sample size calculation for epidemiological studies. *Jekel's Epidemiology, Biostatistics, Preventive Medicine and Public Health* 4th ed. Philadelphia: Saunders/Elsevier.2014;p.155.

6. Caoili EM, Cohan RH, Korobkin M, Platt JF, Francis IR, Faerber GJ, Montie JE, Ellis JH. Urinary tract abnormalities initial experiences with multi-detector row CT urography. *Radiol* 2002;222(2):353-60.DOI:10.1148/radiol.2222010667.

7. Danjem SM et al. Assessment of CTU in the diagnosis of urinary tract abnormalities in a tertiary hospital. *Jos J Med*2016;10(1):16-21.

8. Meenakumari A, Tseizo K, Kaku S. Evaluation of Obstructive Uropathy with Computed tomography urography and Magnetic Resonance Urography. A clinicoradiological study. *IOSR J Dent Med Sci* 2015;14:1-5.

9. Alderson SM, Hilton S, Papanicolaou N. CT Urography: Review of Technique and Spectrum of diseases. *Applied Radiol*2011;40(7/8):6 www.appliedradiology.com;2011. Accessed on 30/03/2023.

10. Lin WC, Wang JH, Wei CJ, ChangCY. Assessment of CT Urography in the Diagnosis of Urinary Tract Abnormalities. *J Chin Med Assoc* 2004; 67(2):73-8.

11. Nikolic O, Stojanovic S, Till V, Basta-Nikolic M, Petrovic K, Vucaj-Cirilovic V.
Multislice computed tomography urography in the diagnosis of urinary tract diseases.
Vojnosanit Pregl 2011;68(5):417-22. Doi:10.2298/vsp1105417N

UNDER PEER REVIEW