

Evaluation of the Effect of Methanol Seed Extract of *Carica papaya* (Pawpaw) on the Hematological Indices and Renal Health of Rats induced Kidney Damage.

Abstract

The kidney is one of the most important organs of the body saddled with critical physiological functions one of which is the elimination of metabolic waste products from the blood. Drugs, chemicals, pesticides, and pollutants can pose threat to the kidney and often times, collapse its functions and in order to minimize pressure on the already deteriorating organ, treatment should focus more on natural options than the conventionally sourced option of employing synthetics. Thus, the aim of this study was to evaluate efficacy of pawpaw seed extract in the treatment of experimentally induced kidney damage. Pawpaw Seed Extract (PSE). Seed obtained from ripe pawpaw fruit was dried at room temperature and afterwards extracted. Twenty five (25) adult male Wistar rats were divided five (5) rats per group. **Group I** was the normal control administered only distilled water. **Group II** was administered 100 mg/kg gentamicin and was never treated with extract. **Groups III-V** were administered 100, 200 and 400 mg/kg body weight of PSE respectively for 28 days after which animals were sacrificed and blood samples collected for analysis. Biochemical, haematological and histological parameters were determined using standard procedures. Results obtained from this study revealed that increased serum creatinine and urea levels were observed in Group II. However these were significantly ($P < 0.05$) reduced to in treated groups with the effect of treatment being more pronounced in groups administered 200 and 400 mg/kg of extract. It also revealed that extract did not alter the hematological indices of treated rats. In conclusion, PSE can reverse kidney damage and would not alter haematological status of treated animal.

Keywords: Haematological, Kidney, Urea, Creatinine, Serum

Introduction

Notably, kidney disease is one of health challenges that have adversely impacted mankind and has been widely implicated in untimely deaths [1] evident by the fact that an estimated 10% of the population suffers from it [2]. In most cases, treatment of kidney diseases require sophisticated approaches such as dialysis and transplantation which are not exorbitant but also have shortfalls such as immunological rejection of kidney graft, immune suppression and its attendant consequences [3]. Cellular destruction is implicated in direct damage may have a

biochemical, hematological or immunological basis [4]. Haematological parameters are dependable indicators in the diagnosis and treatment of diseases. The changes in different hematological and biochemical parameters have been linked to chronic kidney disease [5].

Plant based medications constitute dependable alternatives to their synthetic counterparts which are characterized by pitfalls some of which may equate or surpass the condition being addressed. They have been in use since prehistoric times and has delivered maximally to mankind [6]; [7]. This is substantiated by the fact that an estimated over 80% of the world's populations source medication from plant to meet their health needs. They are considered affordable, readily available and safe for human consumption [8].

The plant *Carica papaya*, commonly known as pawpaw and a member of the *Caricaceae* family is grown in many countries across the globe for its fruits. The fruit is known for its richness nutrients of immense health significance while various parts of the plant are have been employed extensively in the treatment of diverse human diseases [9]. The seed, latex, leaf, fruit, and flower of *C. papaya* are embodiments of bioactive compounds such as carotenoids glucosinolates benzyl isothiocyanate, which inform their relevance in the treatment of diseases [10]. Locally extract of *C. papaya* are consumed to boost testicular functions.

Materials and Methods

Collection of plant material

Ripe fruits of *Carica papaya* L. (solo dwarf variety) of the family *Caricaceae* were Harvest from a home garden in Uturu in Abia State, Southeast Nigeria. The pawpaw fruits were subsequently conveyed to the Department of Forestry, Michael Okpara University of Agriculture, Umumdiike Abia State Southeast Nigeria.

Processing of *Carica papaya* seed

The seeds obtained were washed using clean water and afterwards, dried at room temperature for 21 days. The dried seeds were ground into powder with the aid of a hammer mill with a 0.3 mm sieve. Petroleum spirit was employed to defat 1000 g of pawpaw seed powder at 40°C [11] for 8 h and subsequently using 70% ethanol at 80°C for 12 h. The 70% ethanol extract was condensed in a crucible with a water bath. The crucible with the extract was transferred to a 40 °C hot air oven for 24 h. The dried extract was weighed and was referred to as Pawpaw seed extract (PSE).

Animals

Adult male albino rats weighing between 120-150 g were procured from the Animal House of the Department of Science Laboratory Science, Akanu Ibiam Federal Polytechnic, Uwana, Afikpo. The rats were kept in well ventilated plastic cages under standard laboratory conditions and were allowed access to food and water *ad-libitum*. Animals were allowed to acclimatize for three weeks before the experiment was commenced.

Median Lethal Dose 50% (LD50%)

A total of nine adult male albino rats were used in the first phase of LD 50% determination. The rats were divided into three groups of three rats each. Each group was subsequently administered with 10, 100 and 1000 mg/kg of extract orally. Observation on animals lasted for 24 h to observe signs of toxicity. Following the fact that mortality was not observed after the first phase, the second phase comprising another three groups of one rat each was each which was administered

with 1600, 2900 and 5000 mg/kg of extract and afterwards, animals were observed for 48 h for signs of toxicity according to Lorke [12].

Induction of kidney damage

Kidney damage was induced by intraperitoneal administration of gentamicin 100 mg/kg/day for eight days [13].

Animal Grouping

A total of 25 rats were randomly divided into five (5) groups of five (5) rats each. The groups were treated thus:

Group I (Normal control): Rats were administered 2 mL of distilled water.

Group II: Rats with untreated damaged kidney

Group III: Rats with untreated damaged kidney+ 100 mg/kg PSE

Group IV: Rats with untreated damaged kidney+ 200 mg/kg PSE

Group V: Rats with untreated damaged kidney+ 400 mg/kg PSE

Treatment lasted for 28 days after which rats were humanely sacrificed and blood samples were processed for further analysis.

Biochemical analysis

Kidney function test was determined by introducing 2 mL of blood into the EDTA tube which was subsequently centrifuged at 4,000 rpm for 15 min and the plasma obtained was stored for biochemical analysis. Kits were used to determine the levels of urea, and creatinine.

Haematological evaluation

Evaluation of haematological indices such as the Red Blood Cells count, White Blood Cells count and Haemoglobin concentration as well as packed cell volume were performed with an automatic hematological analyzer (Coulter STKS, Beckman)

Tissue processing and histology

Harvested kidneys were pre-fixed in 10% formalin were histologically examined in accordance with the method described by Acheampong et al. [15]. The kidney samples were transferred removed from the formalin was immersed into a series of ethanol solutions of increasing concentration to remove in order to eliminate water from the tissue and replaced with alcohol. The dehydrated tissues were cleared with xylene to enhance the optical resolution. The tissues were waxed into a cassette, microtome, and flamed on a burner, washed under running water, dipped in an alkaline solution, and stained in Eosin Y (1%, for 10 min). The sections were then mounted in mounting media and observed under the light microscope.

Statistical Analysis

Data generated were expressed as Mean \pm Standard Deviation using SPSS (Ver. 23). Data were analysed using one way Analysis of Variance (ANOVA). Differences in mean were compared using Turkey Test. *p-values* less than 0.05 was considered statistically significant.

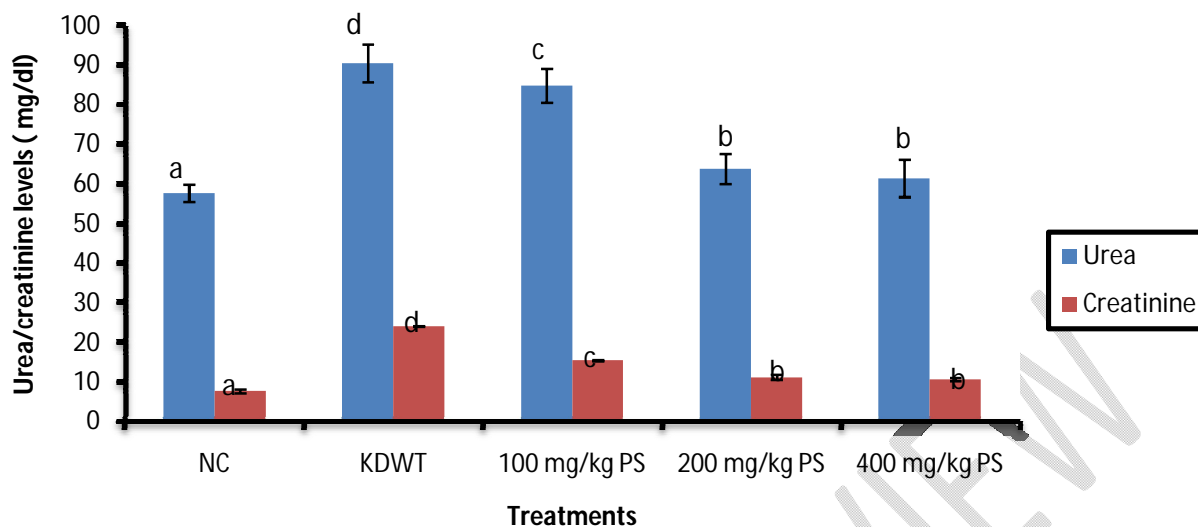


Figure 1: Urea and creatinine levels rats administered methanol seed extract of *Carica papaya* seed

Table 1: Haematological Indices of Rats administered Methanol Seed Extract of *Carica papaya*

Groups	PCV (%)	Hb (g/dL)	RBC($\times 10^{12}/L$)	WBC($\times 10^9/L$)
Group I (Normal Control)	43.47 \pm 0.97 ^{ab}	13.89 \pm 0.98 ^a	4.44 \pm 0.08 ^a	9.34 \pm 0.09 ^b
Group II (KDWT)	42.41 \pm 0.67 ^a	13.47 \pm 1.06 ^a	5.87 \pm 0.17 ^a	8.47 \pm 0.10 ^a
Group III (PS _{100 mg/kg})	45.34 \pm 0.20 ^b	14.78 \pm 1.00 ^{ab}	7.51 \pm 0.25 ^b	13.02 \pm 0.48 ^c
Group IV (PS _{200 mg/kg})	46.98 \pm 0.21 ^b	12.99 \pm 0.13 ^a	6.22 \pm 0.18 ^{ab}	8.04 \pm 0.38 ^a
Group V (PS _{400 mg/kg})	44.39 \pm 0.84 ^b	14.13 \pm 1.30 ^{ab}	6.45 \pm 0.61 ^{ab}	10.5 \pm 0.83 ^{bc}

Results are expressed as mean \pm standard deviation of five determinations. Values with the same superscript in a column are not significantly different ($P < 0.05$).

Table 2:Phytochemicals in Methanol Seed Extract of *Carica papaya*

Phytochemicals	Presence
Saponins	+++
Tannins	+++
Carbohydrate	+
Flavonoids	+++
Proteins	+
Glycosides	+
Alkaloids	+
Terpenoids	+
Steroids	+
Phenols	++
Oxalate	++

Results and Discussion

Biochemical markers are indispensable elements in rendering accurate diagnosis to diseases and in adopting ideal therapeutic approaches. Creatinine and urea are commonly deployed parameters in determining kidney functions [16]. Figure 1 shows the urea and creatinine levels of rats administered methanol seed extract of *Carica papaya* seed indicating that the serum creatinine and urea levels of rats induced kidney damage without treatment were significantly ($P < 0.05$) higher than those reported for the normal control. However, oral administration of pawpaw seed extract (PSE) significantly ($P < 0.05$) reduced serum levels of creatinine and urea. The ability of the extract to reverse gentamicin induced kidney damage in rats was evident by the pronounced improvement on the distorted kidney architecture observed on the damaged kidney following oral administration of extract. Although, through which healing was made possible was not known, it is not out of place to opine that curative effect of the extract could have resulted from the antioxidant and/ or free radical scavenging activities of the extract owing to its high flavonoid and alkaloids concentration all of which are reportedly inherent in *Carica papaya* leaf. This is in agreement with the findings of this study which has shown that pawpaw seed extract is an embodiment of the aforementioned phytochemicals Table 2 [17]; [18]. The findings from this study are consistent with the finding of Inayat et al. [19] showed that treatment with *C. papaya* leaves extract improved ratio of kidney weight/body weight. Blood, known to circulate metabolic products from and to the various regions of the cardiovascular system can be influenced by the clinical status of the tissue environment [20] hence, the functional properties of hematological parameters [21]. Blood parameters are key indicators in diagnosing the actual physiological status of an organism [22] Table 1 shows the hematological indices of rats administered methanol seed extract of *Carica papaya* indicating that the PCV, Hb and RBC of

mice induced kidney damage without treatment were not significantly ($P > 0.05$) differently from those reported for the normal control. Similarly, PCV, Hb and RBC and TWBC reported for groups III-V administered 100, 200 and 400 mg/kg of PSE were not significantly ($P < 0.05$) lower than those reported for the normal control. This is consistent with the finding made by Timothy et al. (2022) which showed that oral administration of aqueous extract of *Carica papaya* leaf had no adverse effect on the blood indices of treated rats. It also contradicts the outcome of a study by Hammad[23] which reported a decreased Red Blood Corpuscle (RBC) following oral administration of pawpaw leaf extract. The photomicrographs of the kidney of rats obtained from the treated groups shows normal tubules and glomeruli.

Conclusions

It is established through this study that methanol seed extract has the ability to address toxin induced kidney damage. Thus, holds promise a novel candidate in further search for dependable therapies that could be useful in treating toxin related kidney damage.

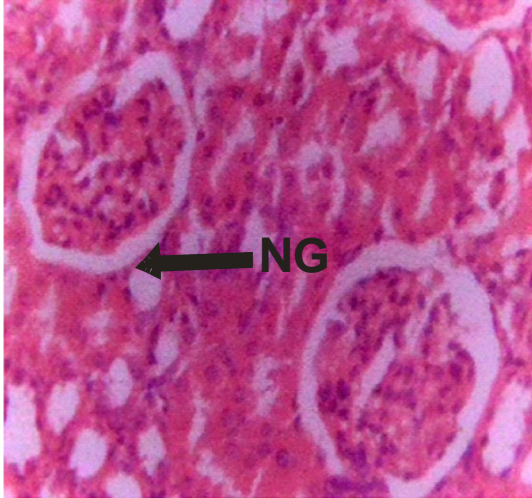


Plate 1

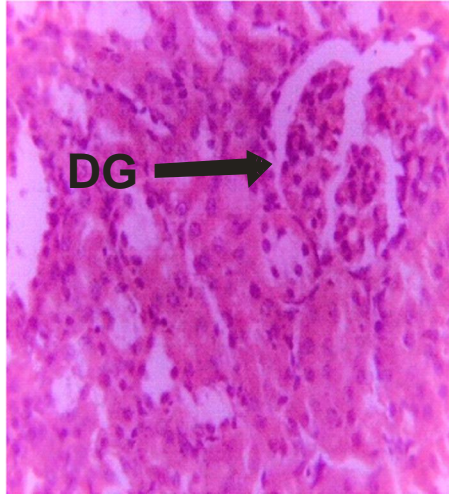


Plate 2

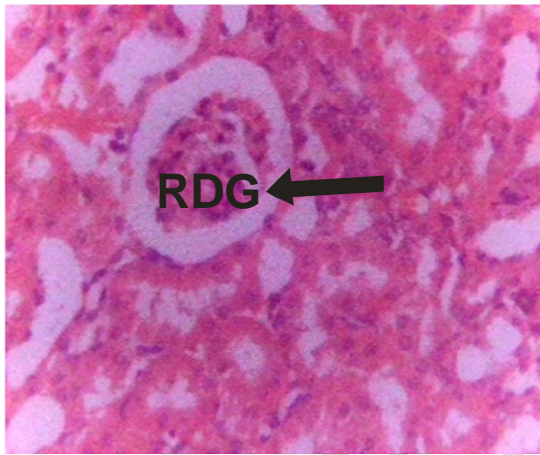


Plate 3

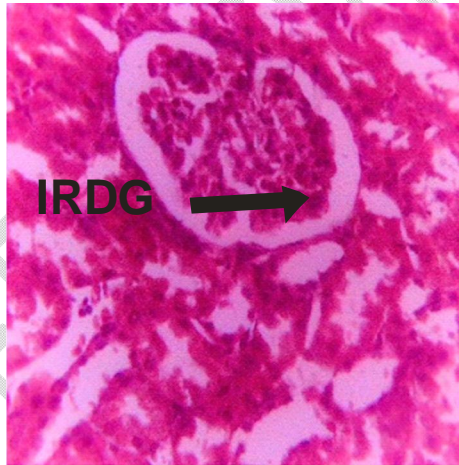

Plate 4

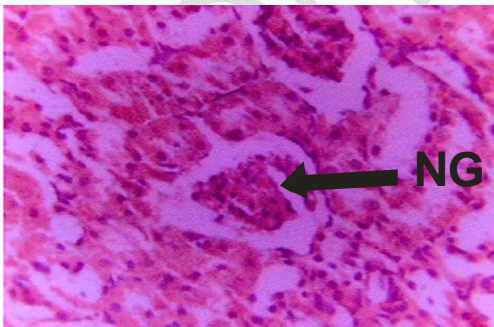


Plate 5

Plates 1-5: Histopathological slides

References

- [1] Levey AS, Atkins R, Coresh J, *et al.* Chronic kidney disease as a global public health problem: approaches and initiatives – a position statement from Kidney Disease Improving Global Outcomes. *Kidney Int.* 2007; 72(3):247-259.
- [2] World Kidney Day: Chronic Kidney Disease, 2015. Available from: <http://www.worldkidneyday.org/faqs/chronic-kidney-disease/>. Accessed December 10, 2017.
- [3] Sands JM, Verlanders JW. Anatomy and Physiology of the Kidney. In: Toxicology of the Kidney 3rd ed (Tarloff JB, Lash, LH eds). CRC Press, Boca Raton, FL, 2005, 3-56.
- [4] Mukharjee JB (2000) Forensic Medicine and Toxicology (2nd Edn).
- [5] Mitku MT, Tewodros G, Amare AT, Gashaw G. Anemia and Its Associated Factors Among Type 2 Diabetes Mellitus Patients Attending Debre Berhan Referral Hospital, North-East Ethiopia: A Cross-Sectional Study. *J Blood Med.* 2020; 11:47–58.
- [6] Veeresham C, Natural products derived from plants as a source of drugs, *J. Adv. Pharm. Technol. Res.* 2012. 3 (4): 200.
- [7] Ekor M, The growing use of herbal medicines: issues relating to adverse reactions and challenges in monitoring safety, *Front. Pharmacol.* 2004. 4:177.
- [8] Asadbeigi M, Mohammadi T, Rafieian-Kopaei M, Saki K, Bahmani M, Delfan B. Traditional effects of medicinal plants in the treatment of respiratory diseases and disorders: An ethnobotanical study in the Urmia. *Asian Pac. J. Trop. Med.* 2014;7:364-8.
- [9] Krishna K, Paridhavi M, Patel JA, Review on nutritional, medicinal and pharmacological properties of Papaya (*Carica papaya* Linn.), *Asian Pac. J. Trop. Biomed.* 2008.
- [10] Rahmani AH, Aldebasi YH, Srikar S, Khan AA, Aly SM. Aloe vera, Potential candidate in health management via modulation of biological activities. 2015. *Pharm. Rev.* 9 (18) 120.
- [11] Trease GE, Evans WC. Pharmacognosy. 15th Ed. London: Saunders Publishers. 2002; pp. 42–44, 221–229, 246–249, 304–306, 331–332, 391–393.
- [12] Lorke D. A new approach to practical acute toxicity testing. *Arch Toxicol.* 1983; 54(4):275-287.
- [13] Karahan I, Atessahin A, Yilmaz S, Ceribasi AO, Sakin F. *Toxicology* 2005; 215: 198-204.

- [14] Acheampong DO, Barfffour IK, Boye A, Asiamah EA, Armah F.A, Adokoh CK, Oluyemi JF, Adrah B, Opoku R, Adakudugu E, Histoprotective effect of essential oil from citrus aurantifolia in testosterone-induced benign prostatic hyperplasia rat. *Advan Urol*. 2019.
- [15] Mitchell HR and Kline W. Core curriculum in nephrology, Renal Function Testing. *Am J Kidney Dis* 2006; 47: 174-183.
- [16] Miller NJ and Rice-Evans CA. Factors influencing the antioxidant activity determined by the ABTS radical cation assay. *Free Radical Research*. 1997; 26:195-199.
- [17] Adeneye AA and Benebo AS. Protective effect of the aqueous leaf and seed extract of *Phyllanthus amarus* on gentamicin and acetaminophen-induced nephrotoxic rats. *Journal of Ethno pharmacology*. 2008; 118:318-323.
- [18] Inayat UR, Mohammad B, Khalil UR. Evidence of the nephroprotective effect of *Carica papaya* L. leaves in streptozotocin-induced diabetic rats *Indian Journal of Traditional Knowledge*. 2016. 15(3): 460-465.
- [19] Muriithi NJ, Maina GS, Maina MB, Kiambi MJ, Juma KK, et al. Determination of Hematological Effects of Methanolic Leaf Extract of *Vernonia lasiopus* in Normal Mice. *J Blood Lymph*. 2015. 5: 139.
- [20] Jones RL, Peterson CM. Hematologic alterations in diabetes mellitus. *Am J Med*. 1981. 70: 339-352.
- [21] Pankaj PP, Varma MC. Potential role of *Spirulina platensis* in maintaining blood parameters in alloxan induced diabetic mice. *Int J Pharm Pharmaceut Sci*. 2013. 5: 450-456.
- [22] Timothy O, Okpakpor EE. Iniaghe, LO. Biosafety evaluation of *Carica papaya* aqueous leaf extract on haematological parameters and organ/bodyweight ratio in Wistar rats. 2022. *DUJOPAS*, 8:1.
- [23] Hammad A. Effect of Papaya leaf juice on hematological parameters of rats. *Hamdard j. pharm*. 2021. 2:08.