

**Successful treatment of Lipoid Proteinosis In a Young Adult with  
Isotretinoin.**

**Abstract**

*Lipoid proteinosis (LP) is an extremely rare autosomal recessive genodermatosis, characterized by persistent hoarseness and classical skin lesions. Amorphous hyaline depositions may affect any organ, but mainly the face and extremities. These depositions cause limitations in tongue movement, and hence, difficulty speaking. Biopsies of skin lesions usually show massive deposits of homogeneous, acidic, hyaline-like material at the epidermal junctions and superficial dermis that stains positive for periodic acid-Schiff stain (PAS-D). At present, there is no specific treatment for this extremely rare disease, but some studies have reported that treatment with acitretin and etretinate results in some improvement. This paper reports on the effectiveness of isotretinoin for the first time for treatment of this disease.*

**Keywords:** Lipoid proteinosis, hoarseness, periodic acid Schiff, isotretinoin

## Introduction

Lipoid proteinosis (LP), or Urbach-Wiethe disease, is a very rare autosomal recessive skin disease that initially presents with laryngeal deposition of amorphous vitreous material, leading to persistent hoarseness at birth or in early childhood, as expressed by a soft cry<sup>[1]</sup> that is accompanied by classic skin changes such as scarring, fragility, discomfort, papules and/or nodules infiltrating the eyelid<sup>[2]</sup>.

The deposition of an amorphous vitreous substance on the tongue usually limits the tongue's movements and causes speech difficulties. In addition, these infiltrates can lead to the appearance of papules and scars resembling chickenpox<sup>[3]</sup>. It primarily affects the face and extremities. However, any organ in the body can be affected, such as the respiratory system, which causes airway obstruction, and the central nervous system, resulting in seizures<sup>[4]</sup>.

There is currently no specific established therapeutic option to treat lipoid proteinosis, but this paper reports a positive response with treatment by isotretinoin.

## Case Presentation

A 20-year-old man born to first degree consanguineous parents (48-year-old father and 43-year-old mother) presented with hoarseness that was noticed by his mother at birth and was clear when he was crying. This hoarseness has persisted until the current date. At the age of 17, recurrent skin lesions started to appear every 2-4 months on his face and upper extremities that left disfiguring lesions as scars when healed.

Clinical examinations revealed that the patient had hoarseness while talking. On the first examination, lesions (mainly on the face) were described as multiple papulopustular with atrophic scars similar to chickenpox (Figure 1). Areas of friction (elbows, knees, hands, dorsae) developed verrucous hyperkeratotic plaques (Figure 2). Typical beaded papules (monilia

ornaments blepharosis) were also present on the eyelid margins (Figure 3), and the patient had difficulty protruding his tongue (Figure 4).

The patient underwent ENT consultation, which reported vocal cord thickening and hyaline depositions at the larynx and posterior pharyngeal wall, oral cavity, and tongue. Laboratory investigations included a full blood count, measurement of serum glucose level, hepatic and renal function tests, and lipid profile, all of which were within normal levels. A skin biopsy from the upper back showed massive deposits of homogeneous, eosinophilic, hyaline-like material at the dermal-epidermal junctions and at the superficial dermis (H&E) (Figure 5) The hyaline like-material was positive on periodic acid-Schiff stain (PAS-D) (Figure 6).

Based on clinical and histopathological findings, the patient was diagnosed with a case of lipoid proteinosis. He was started on isotretinoin 20 mg/day in August 2021, with follow up examinations every two months. The drug dose was adjusted according to body weight at every follow-up visit. Baseline investigations were also conducted and repeated every two months. Six months following treatment initiation, the hoarseness partially improved, and the tongue could be partially protruded. The skin lesions also decreased in number. ENT follow up reported decreased vocal cord thickening and decreased hyaline depositions in the larynx and oral cavity. One year after follow-up, no new lesions had appeared, and a 70% improvement in voice quality was noted.

## **Discussion**

Lipoid proteinosis is a rare autosomal recessive disease caused by a homozygous mutation of the Q276X in the ECM1 gene, resulting in deposition of hyaline-like material in

multiple tissues <sup>[5]</sup>. Usually, hoarseness during crying in infancy is the initial symptom noticed, along with cutaneous lesions of acne, papulopustular lesions, beaded papules along the eyelids, and oral mucosal lesions appearing later in childhood, often after the age of 10 <sup>[6]</sup>. In agreement with this, the case study presented here shows a history of soft crying since birth, which continued as hoarseness when talking in early childhood. Skin lesions also appeared at age of 17 years as recurrent skin lesions every 2-4 months on his face and upper extremities that left disfiguring scars.

Cutaneous lesions of LP mainly affect sun-exposed areas: the face, elbows and hands. They appear characteristically in the form of thickened facial skin with a waxy texture covered with yellow, infiltrated, flat plaques, and papules among disfiguring scars <sup>[7]</sup>. In the present case, skin lesions appeared on the face and the upper extremities during puberty, which left post-healing scars in the form disfiguring lesions. Infiltration of oral mucosa, the vocal cords and frenulum by an amorphous hyaline-like material also characterizes LP lesions, leading to hoarseness and restricted tongue protrusion. In addition, attacks of respiratory distress might occur, whereby the airway is affected <sup>[6]</sup>.

Histopathological findings of LP include deposition of homogeneous, eosinophilic, hyaline-like material at the dermal-epidermal junctions and superficial dermis. In addition, the hyaline like-material is positive on periodic acid-Schiff stain (PAS-D) <sup>[8]</sup>. The skin biopsy from the upper back of the present case showed massive deposits of homogeneous, eosinophilic, hyaline-like material at the dermal-epidermal junctions and at the superficial dermis (H&E). The hyaline like-material was positive on periodic acid-Schiff stain (PAS-D).

Because of the rarity of lipoid proteinosis, there is a serious limitation in terms of trials of therapeutic options. Of those that do exist, some studies have reported good results with the

treatment of acitretin and etretinate <sup>[9-11]</sup>. The present case was treated with isotretinoin and showed impressive improvement.

It is thought that retinoids modulate the metabolism of the connective tissue matrix of the dermal-epidermal junction and the dermis <sup>[12]</sup>. At present, no previous studies have been published to support the usefulness of isotretinoin on both cutaneous lesions and hoarseness <sup>[13]</sup>. Therefore, isotretinoin may be a superior treatment to acitretin and etretinate, the former of which has the qualities of a resistance to tolerance, ease of dose modification and minimal side effects over the long term compared to other variants of retinoid. In a similar case that used acitretin, there was no obvious cutaneous improvement; however, there was significant improvement in hoarseness <sup>[10]</sup>. In another two young girls in Egypt treated with acitretin, there was complete remission of cutaneous lesions and improvement of the hoarseness after one year <sup>[14]</sup>. Since there is limited experience with isotretinoin in treating LP, future studies are advised to evaluate and monitor its effects on LP patients despite our experience with this case providing impressive results.

**Ethical approval:** IRB received

## References

1. Urbach E, Wiethe C. Lipoidosis cutis et mucosae. *Virchows Arch A Pathol Pathol Anat* 1929; 273:285.
2. Hamada T. Lipoid proteinosis. *Clin Exper Dermatol*. 2002; 27:624-629. PMID: 12472532.
3. Hougenhouck-Tulleken W, Chan I, Hamada T, Thornton H, Jenkins T, et al: Clinical and molecular characterization of lipoid proteinosis in Namaqualand, South Africa. *Br J Dermatol* 151:413-423 (2004).

4. Mcgrath JA. Lipoid proteinosis. *Handb Clin Neurol* 2015; 132:317.
5. van Hougenhouck-Tulleken W, Chan I, Hamada T, Thornton H, T Jenkins T, McLean WHI, et al. Clinical and molecular characterization of lipoid proteinosis in Namaqualand, South Africa. *Br J Dermatol*. 2004 Aug;151(2):413-23. doi: 10.1111/j.1365-2133.2004.06076.x.
6. Ramsey ML, Tschen JA, Wolf Jr. JE. Lipoid proteinosis. *International Journal of Dermatology*. 1985;24(4): 230–232.
7. Hu S, Kuo TT, Hong HS. Lipoid proteinosis: report of a possible localized form on both hands and wrists. *International Journal of Dermatology*. 2005; 44(5): 408–410.
8. Hamada T, McLean WHI, Ramsay M, Ashton GHS, Nanda A, Jenkins T, et al. Lipoid proteinosis maps to 1q21 and is caused by mutations in the extracellular matrix protein 1 gene (ECM1). *Hum Mol Genet* 2002;11:833-40.
9. Toosi S, A. H. Ehsani AH. Treatment of lipoid proteinosis with acitretin: a case report. *Journal of the European Academy of Dermatology and Venereology* 2009; 23(4):482–483.
10. Gündüz O, Sahiner N, Atasoy P, Senyücel C. Acitretin treatment for lipoid proteinosis. *Case Rep Dermatol Med*. 2012;2012:324506.
11. Gruber F, Manestar D, Stasic A, Grgurevic Z. Treatment of lipoid proteinosis with Etretinate. Case report *Acta Derm Venereol*. 1996 Mar;76(2):154-5.
12. Daly TJ, Weston WL. Retinoid effects on fibroblast proliferation and collagen synthesis in vitro and on fibrotic disease in vivo. *J Am Acad Dermatol* 15:900–902, 1986.
13. Nickle SB, Peterson N, Peterson M. Updated Physician's Guide to the Off-label Uses of Oral Isotretinoin. *J Clin Aesthet Dermatol*. 2014 Apr; 7(4): 22–34.

14. Bakry OA, Samaka RM, Houla NS, Basha MA. Two Egyptian cases of lipoid proteinosis successfully treated with acitretin. DOI: <http://dx.doi.org/10.3315/jdcr.2014.1168>. (J Dermatol Case Rep. 2014; 8(1): 29-34).

## Figures:

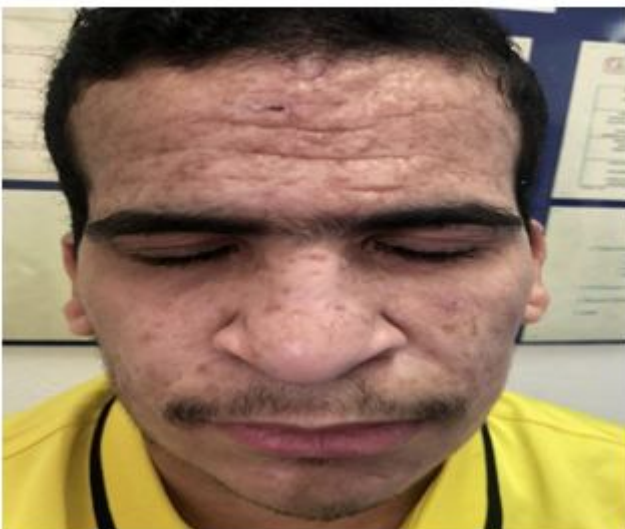


Figure 1: Skin lesion on the face

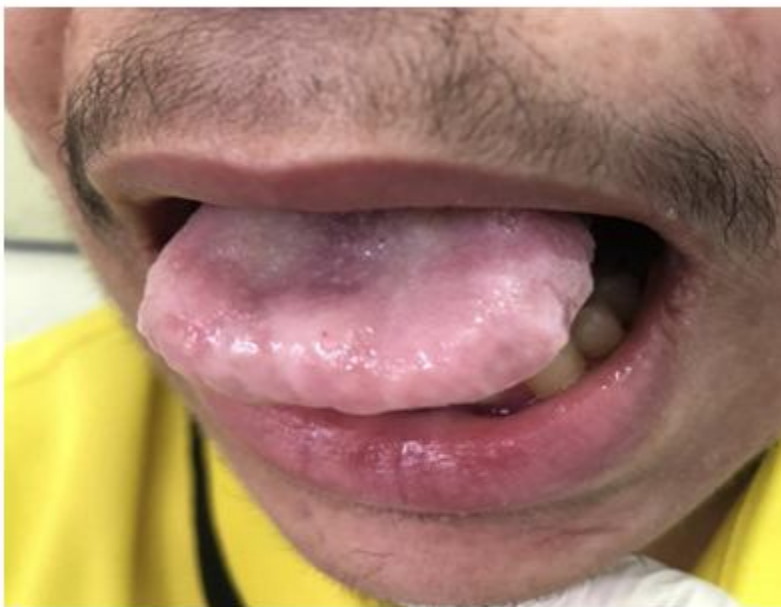

Figure 2: Difficulty in tongue protrusion

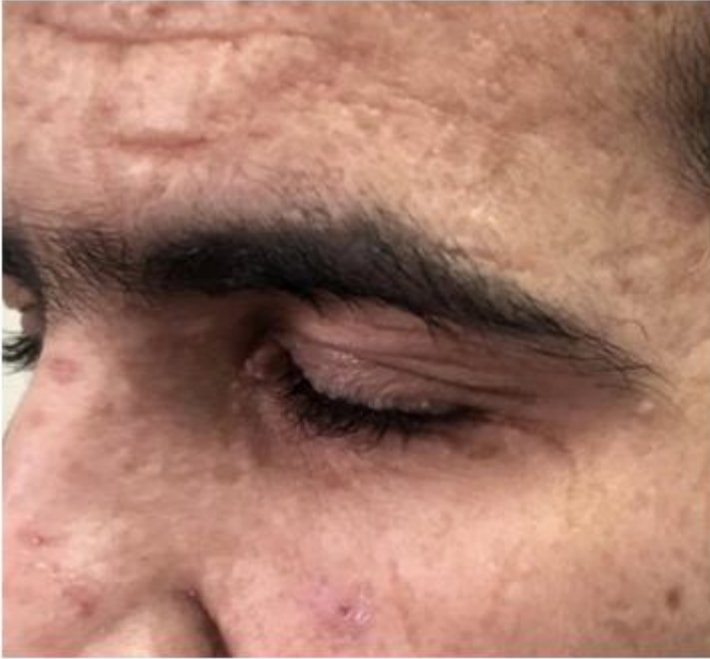

Figure 3: Typical beaded papules occur on the eyelid margins "moniliform blepharosis"

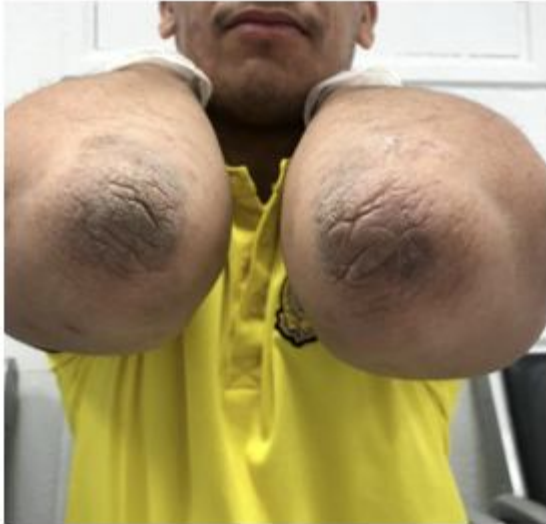

Figure 4: Elbows developed verrucous hyperkeratotic plaques

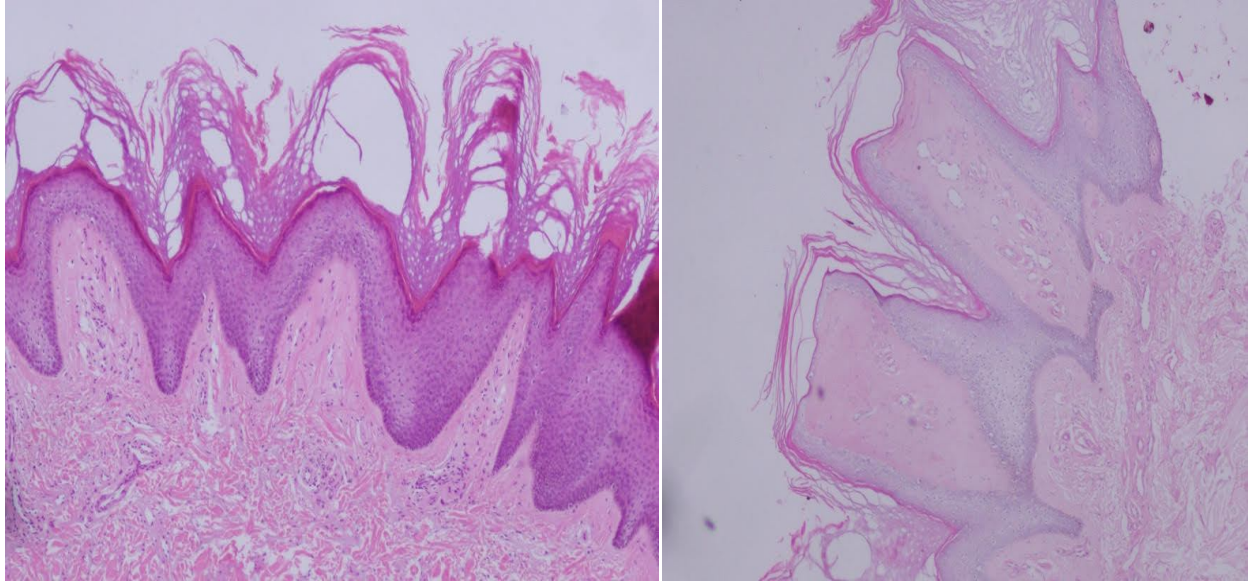


Figure 5: Massive deposits of homogeneous, eosinophilic, hyaline-like material at the dermal-epidermal junctions and at the superficial dermis (H&E).

UNDER PEER REVIEW