

## Evaluation of the hepatotoxic potential of the methanol leaf extract of *Lantana camara*

### Abstract

Owing to its extensive blood supply and significant role in metabolism, the liver is particularly susceptible to xenobiotics. Thus, it is exposed to high doses of the toxicant or its toxic metabolites. The kidney is highly susceptible to toxicants because a high volume of blood flows through the organ and it filters large amounts of toxins which can concentrate in the kidney tubules. Thus, the aim of this work was to evaluate the hepatotoxic potential of methanol leaf extract of *Lantana camara*. Freshly harvested leaf of *L. camara* was processed into fine powder. Exactly 500 g of powdered plant sample was soaked in methanol for 72 h. 20 adult male wistar rats were divided into four groups of five rats each. Group 1 was the normal control and was administered 2 ml of distilled water, Groups 2-4 were administered 100, 200, and 400 mg/kg of MLELC for 28 days during which animals were weighed weekly. At termination of the administration of extract, the rats were sacrificed and blood sample collected and analysed with the aid of standard procedures. There was no significant difference in the creatinine levels of rats administered extract and that reported for the normal control. The body weight of rats recorded at the 4<sup>th</sup> week was significantly ( $P < 0.05$ ) higher than that reported at week 0. The liver weight of groups was all groups was not significantly ( $P > 0.05$ ). Kidney weight of rats was not significantly ( $P > 0.05$ ) different from that reported for the control. The activity of the AST, ALT and ALP in rats administered MLELC was significantly ( $P > 0.05$ ) higher than that reported for the normal control. In conclusion, it can be deduced from this study that *Lantana camara*, though a useful therapeutic plant, is toxic and must be applied with caution.

**Keywords:** Blood, Toxic, *Lantana camara*, creatinine, Urea

### Introduction

Plant based therapeutics dates back to prehistoric times and have served mankind through all ages evident by the fact that an estimated 80% of the global population sources medical supports from plant based medicinal preparations [1] an observation supported by a widely held irrational impression among users which appears to have exonerated plant based therapies from deleterious side effects [2], a notion which has oftentimes been implicated in the abuse of such preparations and their attendant consequences which sometimes may be fatal [3].

The liver, an essential organ that is saddled with the task of metabolism, is prone to injury orchestrated by xenobiotics metabolism in addition which can translate to mild elevation of liver enzymes and sometimes fulminated liver failure. On the other hand, the kidney another important organ of the body is highly susceptible to toxicants owing to the high volume of blood that passes through it and offering it the opportunity to filters large amount of toxins which can concentrate in the kidney tubules. Nephrotoxicity can result to systemic toxicity causing decreasing decreased ability to excrete wastes, inability to maintain body fluid and electrolyte balance [4].

*Lantana camara* Linn is a flowering ornamental as well as an essential oil producing plant belonging to the family *Verbenaceae* L. Its significance in trado-medicinal practices is widely known and appreciated [5]. *Lantana camara* is characterized by an ovate, tough, greenish leaf which with a size 2-10 cm (length) and 2-6 cm (width). Medicinally, the said plant has been employed extensively in the treatment of ailments such as cancer, tumors, tetanus, cuts, eczema, measles, chickenpox, fevers, rheumatism, and asthma [6]. Thus, it is imperative to probe the potential toxic effect of using *L. camara* on certain critical organs of the body.

## **Materials and Methods**

### **Collection of plant materials**

Fresh leaves of *Lantana camara* were harvested from a farm in Afikpo North Local Government Area of Ebonyi State. The leaves were subsequently conveyed to the herbarium unit of the Department of Forestry, Michael Okpara University of Agriculture Umudike, South-Eastern Nigeria in a black polythene bag.

## **Sample Preparation**

Leaves of *L. camara* were thoroughly washed and afterwards dried at room temperature for six days. With the aid of a grinding machine, the dry *L. camara* leaves were ground to fine powder. The resulting powdered sample was preserved in a moisture free, air-tight container. Exactly 500 g of powdered plant sample was steeped in 96% methanol for 72 h. The resulting extract was filtered and concentrated using a rotary evaporator. The residue obtained was dried in desiccator.

## **Animals**

Adult male albino rats weighing between 150-180 g were purchased from the Animal House of Akunu Ibiam Federal Polytechnic Afikpo, Unwana. The rats were housed and maintained in well ventilated transparent plastic cages under standard laboratory conditions and were allowed unrestricted access to food and water. The rats were acclimatized for two weeks before experiment.

## **Median Lethal Dose 50% (LD50%)**

The LD 50% was conducted in two phases. In the first phase, nine rats were divided into three groups of three rats was each subsequently administered 10, 100 and 1000 mg/kg of methanol extract of *L. camara* orally. Animals were observed for 24 h for signs of toxicity. After it was observed that none of animals died, another three groups of one rat each was each administered 1600, 2900 and 5000 mg/kg of extract and animals observed for 48 h for signs of toxicity [7].

## **Animal Grouping**

Twenty adult rats were divided into five groups of five rats and treatment administered as follows:

**Group I** (Normal Control): Rats were administered 2 mL of distilled water

**Group II:** Animals were administered 100 mg/kg of MLELC

**Group III:** Animals were administered 200 mg/kg of MLELC

**Group IV:** Animals were administered 400 mg/kg of MLELC

Administration of extract lasted for 28 days during which their body weight was recorded on weekly basis. The animals were humanely sacrificed by cervical dislocation. Organs (kidney and liver) were harvested which blood sample was collected in an appropriate container.

### **Determination of Liver Enzyme Activity**

#### **Biochemical analysis**

Liver and kidney function tests were performed using exactly 2 mL of blood introduced into the EDTA tube centrifuge at 4,000 rpm for 15 min. The resulting plasma was stored for analysis. Kits were used to determine the activity of aspartate aminotransferase (AST), alanine transaminase (ALT), alkaline phosphatase (ALP) as well as the levels of urea, and creatinine.

#### **Weekly body weight measurement**

Animals were weighed at the start of the study which was considered day 0 and was continued for four weeks at interval of one week.

#### **Organ weight measurement**

Liver and kidney harvested from rats at the end on the 28<sup>th</sup> day of the study were suspended in saline soaked gauze pad to retard dryness. Their weights determined (paired organs were

weighed together) to one decimal place and calculated for organ body weight ratio [8] using the formulae below.

$$\text{Organ weight ratio} = \frac{\text{Organ weight (g)}}{\text{Body weight (g)}} \times 100$$

### **Histopathological Studies**

Organs were fixed in 4% formaldehyde solution, embedded in paraffin wax and sliced. Sliced sections were fixed on slides and stained with H&E staining. The tissue sections were observed under a microscope (100 X) for analyzing any change in the cells [9].

### **Statistical Analysis**

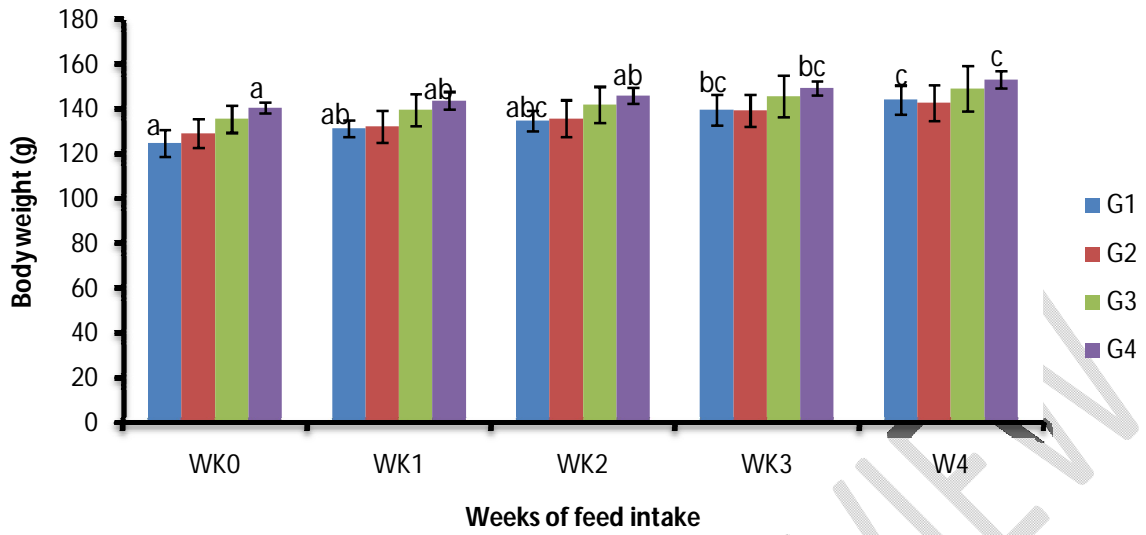
Data obtained were expressed as Mean  $\pm$  Standard Deviation with the aid of SPSS (Ver. 23). Data were analysed using one way Analysis of Variance (ANOVA). Differences in mean were compared using Duncan Multiple Test Range. *P-value* less than 0.05 was considered statistically significant.

**Table 1: Selected Kidney Function Markers of Rats administered Methanol extract of *Lantana camara***

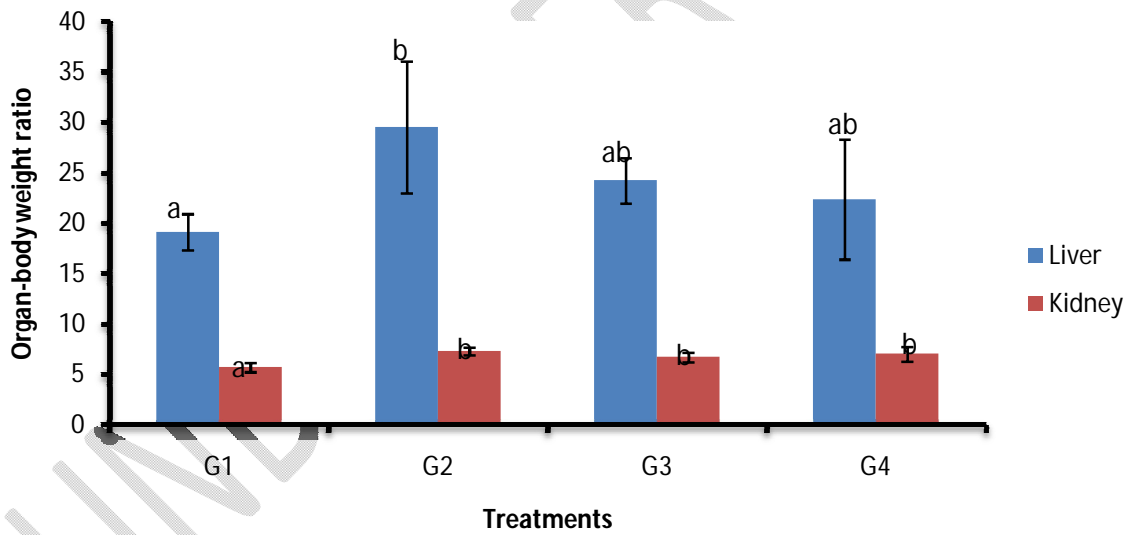
<b>Groups</b>	<b>Creatinine (mg/dl)</b>	<b>Urea (mg/dl)</b>
<b>Group 1(Normal Control)</b>	0.64±0.01 <sup>a</sup>	24.86±0.10 <sup>a</sup>
<b>Group 2 (100 mg/kg) MLELC</b>	0.65±0.01 <sup>a</sup>	26.06±0.23 <sup>ab</sup>
<b>Group 3 (200 mg/kg) MLELC</b>	0.74±0.01 <sup>a</sup>	27.31±2.36 <sup>ab</sup>
<b>Group 4 (400 mg/kg) MLELC</b>	0.63±0.05 <sup>a</sup>	21.42±1.34 <sup>a</sup>

Results are expressed as mean ± standard deviation of five determinations. Value with the same superscript in a column are not significantly (P<0.05) different.

UNDER PEER REVIEW



**Figure 1:** Body weight of rats fed methanol leaf extract of *Lantana camara*.



**Figure 2:** Organ-body weight ratio of rats administered methanol leaf extract of *Lantana camara*

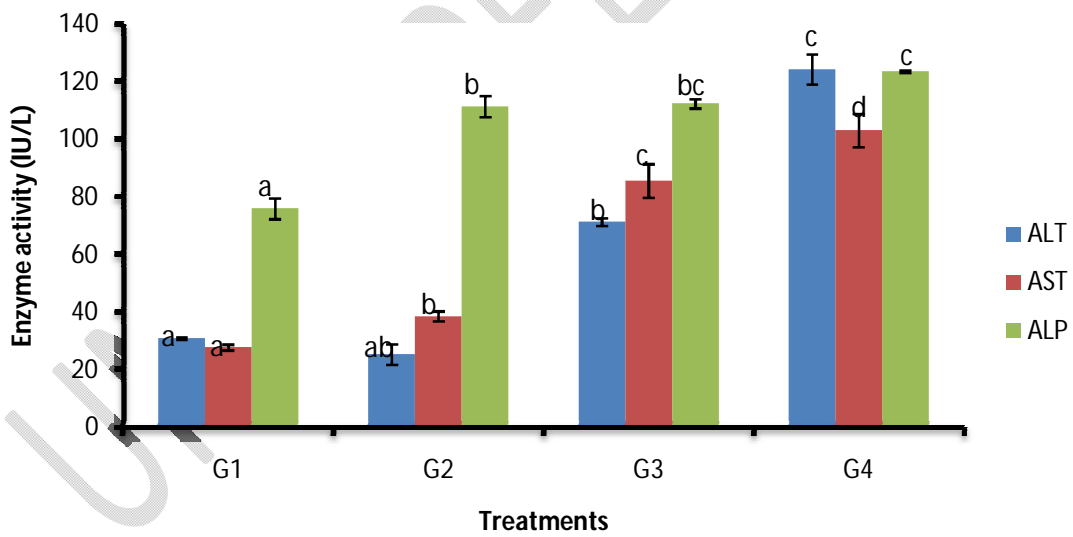


Figure 3: Liver enzyme activity in rats administered methanol leaf extract of *L. camara*

## Results and Discussion

Hepatotoxicity is the toxicity that relates mainly to the liver. Owing to its involvement in metabolism, the liver is primarily prone to xenobiotics, thus it exposed to high doses of the toxicant or its toxic metabolites. The kidney is highly susceptible to toxicants because a high volume of blood flows through the organ and it filters large amounts of toxins which can concentrate in the kidney tubules. Ingestion of a toxic substance can adversely impact body weight and a declined body weight under such a situation could be indicative of an appreciable level of toxicity [10]. Furthermore, organ/body weight ratio can be relied upon to identify and evaluate toxicity of a substance [11]. The liver and kidney are some of major organs affected by metabolic reactions triggered by toxicants [11]. Table 1 shows the two markers of kidney functions (Urea and Creatinine) indicating that there was no significant difference in the creatinine levels of rats administered extract and that reported for the normal control. Figure 1 shows the body weight of rats administered extract showing that body weight of rats recorded at the 4<sup>th</sup> week was significantly ( $P < 0.05$ ) higher than that reported at week 0. Figure 2 shows organ-body weight ratio indicating that The liver weight of rats administered extract 100 g of extract was not significantly ( $P > 0.05$ ) different from that reported for rats administered 200 mg, and 400 mg/kg of extract which in turn was not significantly ( $P > 0.05$ ) different from that reported the normal control. Kidney weight of rats was not significantly ( $P > 0.05$ ) different from that reported for the control. The activity of the AST, ALT and ALP in rats administered extract was significantly ( $P > 0.05$ ) higher than that reported for the normal control. The increased activity of the liver enzymes following administration of methanol leaf extract of *Lantana camara* could be attributed to the damage to hepatocytes orchestrated by the toxicity of lantadene A and B, pentacyclic triterpenoid toxins which are reportedly present in the leaf. This is

consistent with the finding of Kellerman et al. 2005 which showed that *Lantana* species can induce hepatogenous photosensitization in livestock.

### **Conclusion**

This study, it has revealed that *Lantana camara* leaf extract has the potential to induce liver and kidney damage. Hence, its usage in the treatment of diseases must be done with extreme caution.

UNDER PEER REVIEW

## References

- [1] Shri JNM. Ginger: It's Role in Xenobiotic Metabolism, ICMR Bulletin. 2003; 33(6): 57-63.
- [2] Said O, Khalil K, Fulder S, Azaizeh H. Ethnobotanical survey of medicinal herbs of the Middle Eastern region. *J Ethnopharmacol.* 2002;83:251-65
- [3] Deng JF. Clinical Toxicity of Herbal Medicine in Taiwan, 7th International Conference on Health Problems Related to the Chinese. 1994
- [4] Jones AL. Anatomy of the normal liver. In: Zakin D, Boyer TD, Eds. *Hepatology: a textbook of liver disease*, 3rd ed. Philadelphia: WB Saunders, 1996; 3-32.
- [5] Joy JM, Vamsi S, Satish C, Nagaveni K. *Lantana camara* Linn: a review. *Int. j. phytother* 2012, 2, 66–73.
- [6] Lorke D. A new approach to practical acute toxicity testing. *Arch. Toxicol.* 1983; 54(4):275-287.
- [7] Day MD, Wiley CJ, Playford J, Zalucki MP. *Lantana: current management status and future prospects.* Australian Centre for International Agricultural Research Canberra Monograph 2003.
- [8] Akhtar N, Srivastara MK, Raizada RB. Assessment of chlorpyrifos toxicity on certain organs in rat, *Rattus norvegicus*. *J Environ Biol* 2009; 30(6): 1047-1053
- [9] Justin TA, Raja TR, Janakiraman U, and Manivasagam T. Neuroprotective Effect of Hesperidin on Aluminium Chloride Induced Alzheimer's Disease in Wistar Rats. *Neurochem. Res.* 2015; 40 (4): 767–776.
- [10] Nirogi R, Goyal VK, Jana S, Pandey SK, Gothi A. What suits best for organ weight Analysis: review of relationship between organ weight and body/brain weight for rodent toxicity studies. *Int J Pharm Sci Res.* 2014; 5(4):1525e1532.
- [11] Piao Y, Liu Y, Xie X. Change trends of organ weight background data in Sprague dawley rats at different ages. *J Toxicol Pathol.* 2013:29e34.
- [12] Kellerman TS, Coetzer JAW, Naudé TW and Botha CJ. 2005 *Lantana camara*, p.24-26. In: *Ibid.* (Eds), *Plant Poisonings and Mycotoxicoses of Livestock in Southern Africa.* 2nd ed. University of Oxford, Oxford.