

## Case study

### A CASE REPORT OF GIANT EYELID ECCRINE HIDROCYSTOMA

#### ABSTRACT

**Aims:** To report a case of a rare giant eyelid eccrine hidrocystoma confirmed on histopathological examination and successful surgical excision with no recurrence.

**Presentation of case:** A young male presented with a mass over his eyelid which was gradually increasing in size leading to drooping of the upper eyelid with no other associated symptoms. The mass 20x15x10 mm was present over the upper lid, non-mobile, non-tender and firm. On CT scan, a well-defined round to oval hypodense cystic mass was seen to be originating from the left upper eyelid. The cyst was excised and sent for histopathological analysis. Histological appearance of cystic spaces lined by cuboidal epithelium and containing mucinous fluid was suggestive of eccrine hidrocystoma. There was no recurrence till 2 months of follow up.

**Discussion:** Hidrocystoma or sudoriferous cysts are benign cysts originating from sweat glands. They occur in the eyelid but do not involve the eyelid margins. Eccrine hidrocystoma are 1-6 mm in size, generally 4 mm and cysts larger than 10 mm are rare. Larger cysts have been described as "giant eccrine hidrocystoma."

**Conclusion:** Giant eyelid eccrine hidrocystoma are unusual condition of the eyelid which must be considered in the differential diagnosis of eyelid tumours. They can be managed by complete surgical excision although recurrences are found to be common.

*Keywords: Eccrine; Hidrocystoma; Giant; Eyelid tumour*

#### INTRODUCTION

Hidrocystoma or sudoriferous cysts are benign cysts originating from sweat glands. These sweat glands can be of apocrine type, which are found in the eyelids, areolae, external ear, armpits, and genital region or, eccrine type which are found throughout the body<sup>[1]</sup>. Eccrine hidrocystoma is described as small, tense, cystic swellings<sup>[2]</sup>. They can be solitary (Smith and Chernosky type)<sup>[3]</sup> or multiple (Robinson type)<sup>[4]</sup>. They occur in the eyelid but do not involve the eyelid margins. They can have a clear appearance or be pigmented. Eccrine hidrocystoma are 1-6mm in size, generally 4 mm and cysts larger than 10mm are rare<sup>[5]</sup>. Larger cysts have been described as "giant eccrine hidrocystoma"<sup>[6,7,8]</sup>. We report a case of a young male with a rare presentation of giant eyelid eccrine hidrocystoma.

#### PRESENTATION OF CASE

A 17-year-old male presented to our institute with a swelling over the left upper eyelid for 4 months which was gradually increasing in size. The patient also complained of gradually progressive drooping of the left upper eyelid due to the swelling.

On examination, there was a 20x15x10 mm mass over the lateral left upper eyelid, away from the eyelid margin, which was soft, non-tender and immobile (Figure 1).

There were no other cysts on any other body parts. CT scan was performed which showed a well-defined round to oval shaped hypodense cystic lesion likely arising from the lateral aspect of the left upper eyelid, with no obvious intraconal extension. (Figure 2).

The cyst was excised in toto, under local infiltrative anaesthesia and the wound was closed in two layers. The excised cyst was sent for histopathological analysis (Figure 3).

Histopathological examination showed numerous cystic spaces lined by flattened cuboidal epithelium containing mucinous fluid with chronic inflammatory cells, suggestive of eccrine hidrocystoma (Figure 4).

Postoperatively, there was mild lid edema, the suture site was healthy and temporal subconjunctival haemorrhage was present. Oral antibiotics and non-steroidal anti-inflammatory drugs were given and the patient was discharged on postoperative day 5 (Figure 5). The patient was followed for 2 months. There was no recurrence, wound infection, or any other operative site complications at 1 and 2

months of follow up.

## DISCUSSION

A benign cystic tumour called an eccrine hidrocystoma develops from the ducts of the eccrine sweat gland. It is a rare condition that primarily affects adults. Solitary or multiple cysts are the most typical presentation, and they are most frequently found on the face, notably the eyelids. Eccrine sweat glands are essential for thermoregulation<sup>[1]</sup>. Uncertainty surrounds the pathophysiology of eccrine hidrocystoma. However, it is believed to be caused by either the cystic dilation of pre-existing ducts or the proliferation of sweat gland ducts. The disorder is more prevalent in women and has been linked to several other conditions, such as Graves' disease, diabetes, and hypothyroidism<sup>[2,9]</sup>. It is seen to be associated with syndromes like Schopf-Schulz-Passarge and Goltz-Gorlin syndrome<sup>[10]</sup>.

Eccrine hidrocystomas can be single or multiple and often manifest as tiny, painless, translucent dome-shaped lesions. They can be different sizes, ranging in diameter from a few millimetres to several centimetres. Usually asymptomatic, the lesions are diagnosed based on their clinical appearance<sup>[3]</sup>.

Eccrine hidrocystomas are histopathologically distinguished by cystic dilatation of the eccrine sweat gland ducts, which are surrounded by two layers of cuboidal or flattened epithelium. The cysts occasionally have a blue colour and may contain clear or slightly turbid fluid. Because they are localised to eccrine glands rather than apocrine glands, eccrine hidrocystomas can be distinguished from apocrine hidrocystomas<sup>[4,11]</sup>.

An unusual kind of eccrine hidrocystoma that can develop on the eyelids is known as giant eyelid hidrocystoma. In a report by Singh et al., an eyelid eccrine hidrocystoma was mistaken for a chalazion because of its position and appearance. After the lesion was removed, a histopathological analysis supported the eccrine hidrocystoma diagnosis<sup>[5]</sup>. In a different instance, Sheth and Raina described a patient who had unilateral ptosis and epiphora as a result of a large eccrine hidrocystoma<sup>[7]</sup>. In a case study, Eslami et al. described a giant eccrine hidrocystoma of the orbit that manifested as a slow-growing, painless swelling that progressed in the superonasal area of the orbit. A surgical resection was carried out, and histology verified the diagnosis<sup>[6]</sup>. Additionally, Ssi-Yan-Kai and Pearson reported a case of a recurrent, surgically treated giant orbital apocrine hidrocystoma<sup>[8]</sup>.

Other benign cystic lesions including apocrine hidrocystoma, sebaceous cysts, and dermoid cysts should be considered in the differential diagnosis of eyelid eccrine hidrocystoma. Malignant tumours such squamous cell carcinoma, basal cell carcinoma, and sebaceous gland carcinoma should also be taken into account<sup>[11]</sup>. Apocrine hidrocystomas can be challenging to identify from eccrine hidrocystomas. Based on their histological characteristics, which include bigger cysts bordered by an epithelium with decapitation secretion and apocrine glands that open into the cyst lumen and their location, they may be distinguished from eccrine hidrocystomas<sup>[3,8]</sup>. Dermoid cysts, which are often hard, non-fluctuating masses that contain skin adnexal structures including hair follicles and sebaceous glands, are another alternative diagnosis for eyelid eccrine hidrocystoma. A stratified squamous epithelial lining and the presence of keratin debris are further characteristics of sebaceous cysts<sup>[11]</sup>. Additionally, it is important to take into account benign tumours like syringomas and trichilemma<sup>[10]</sup>. The risk of metastatic disease should also be taken into account in individuals with a history of cancer, as metastatic lesions can resemble eccrine hidrocystomas in appearance<sup>[9]</sup>.

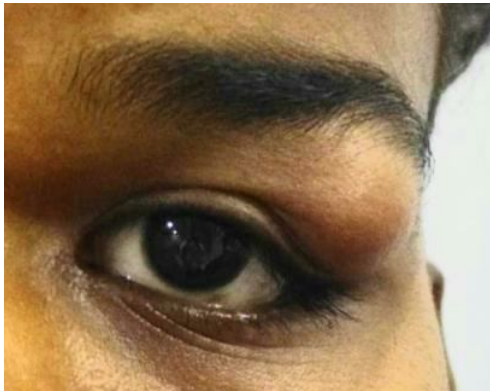Giant eccrine hidrocystomas are uncommon and difficult to treat because of their size and location. Cryotherapy, electrosurgery, carbon dioxide laser ablation, surgical excision, and other therapeutic techniques have all been discussed in the literature<sup>[5,6]</sup>. Complete excision may not be possible when the lesion is in the orbital region due to the possibility of damaging the nearby structures. As a safe and successful treatment option in these circumstances, drainage and sclerotherapy using 95% ethanol have been documented<sup>[6,7]</sup>. Multiple eccrine hidrocystomas have also been successfully treated with topical application of 15% aluminium chloride. Topical 0.03% atropine was found to be just as effective as 15% aluminium chloride in a randomised, single-blind controlled study at reducing

the size and number of eccrine hidrocystomas<sup>[12]</sup>. In addition to these forms of therapy, the underlying cause of the lesion should also be taken into account. Treatment of the underlying condition may result in a decrease in the size and quantity of the lesions in cases where the eccrine hidrocystoma is linked to a systemic disorder, such as Graves' disease<sup>[9]</sup>.

## CONCLUSION

A young male presented with a left eye upper eyelid mass. The CT suggested a hypodense cystic lesion. The cyst was excised in toto and was sent for histopathology. On microscopy, the appearance was suggestive of eccrine hidrocystoma. There was no recurrence or any post-operative complications at 1 and 2 months follow up. Commonly, eccrine hidrocystoma are 1-4 mm in size but, in our reported case, the cyst had the dimensions of 20x15x10 mm which was suggestive of the rare presentation of a giant eyelid hidrocystoma. In conclusion, a rare form of sweat gland cyst that can result in ptosis and epiphora is known as a giant eyelid eccrine hidrocystoma. The preferred course of treatment is surgical excision. Eccrine hidrocystomas are benign lesions that can occur singly or in groups. They exhibit distinctive histological characteristics. Alternative therapies are required because recurrence is common despite surgical excision being the most effective treatment. Multiple eccrine hidrocystomas have shown promise when treated with topical atropine.

## FIGURES



*Figure 1 Left eye upper eyelid mass as the presenting complaint.*

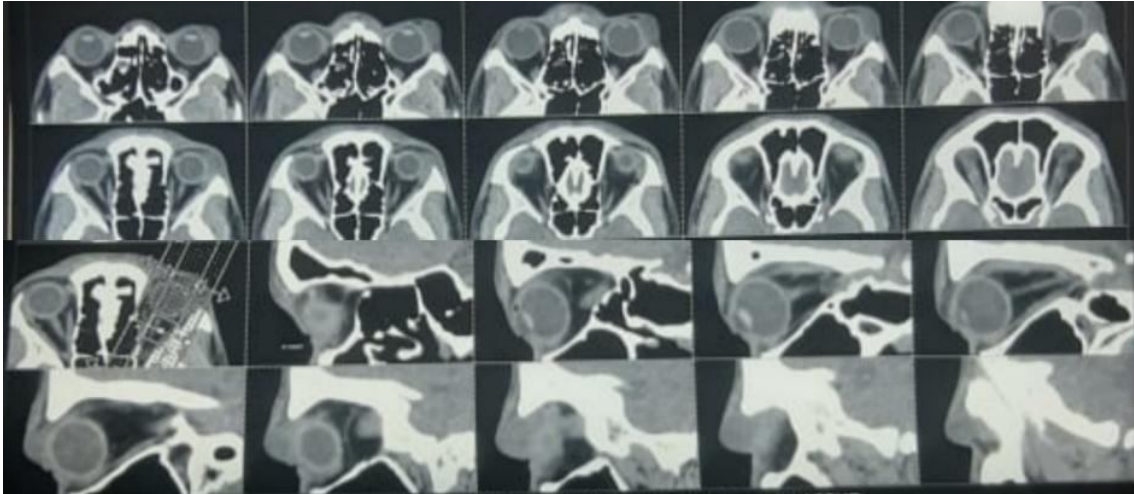


Figure 2 CT orbit showing hypodense cystic lesion.

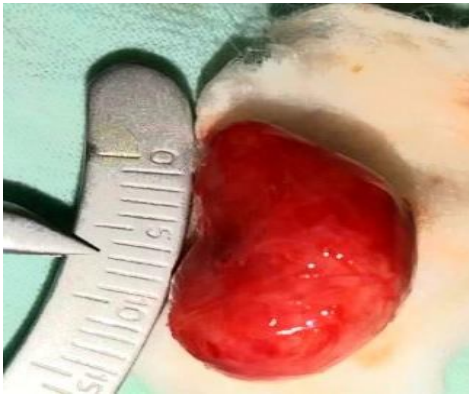
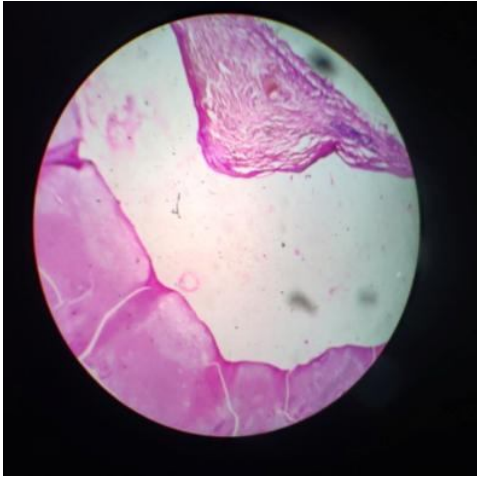
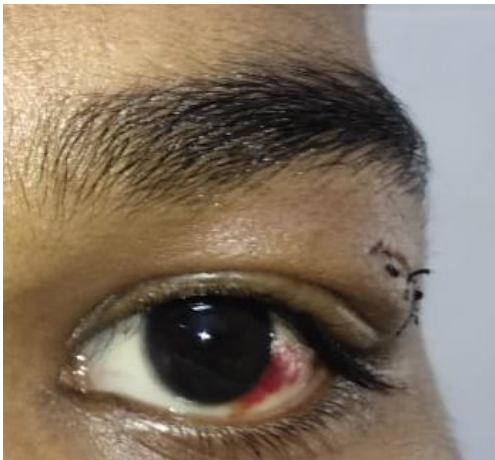


Figure 3 Excised cyst with callipers in place.



*Figure 4 Histopathological appearance of the cyst showing cystic space lined by cuboidal epithelium and filled with mucinous fluid.*



*Figure 5 Postoperative day 5 with suture in situ and temporal subconjunctival haemorrhage*

## **CONSENT**

All authors declare that 'written informed consent was obtained from the patient (or other approved parties) for publication of this case report and accompanying images. A copy of the written consent is available for review by the Editorial office/Chief Editor/Editorial Board members of this journal

## **ETHICAL APPROVAL**

All authors hereby declare that all experiments have been examined and approved by the appropriate ethics committee and have therefore been performed in accordance with the ethical standards laid down in the 1964 Declaration of Helsinki

## REFERENCES

1. Hodge BD, Sanvictores T, Brodell RT. Anatomy, skin sweat glands.
2. Alfadley A, Al Aboud K, Tulba A, Mazen Mourad M. Multiple eccrine hidrocystomas of the face. *International journal of dermatology*. 2001 Feb;40(2):125-9.
3. Smith JD, Chernosky ME. Hidrocystomas. *Archives of Dermatology*. 1973 Nov 1;108(5):676-9.
4. Robinson AR. Hidrocystoma. *J Cut Gen Urin Dis*. 1893;11:292-303.
5. Singh AD, McCloskey L, Parsons MA, Slater DN. Eccrine hidrocystoma of the eyelid. *Eye*. 2005 Jan;19(1):77-9.
6. Eslami F, Fazel F, GHASEMI BH, NADERI BA. Giant eccrine hidrocystoma of orbit.
7. Sheth HG, Raina J. Giant eccrine hidrocystoma presenting with unilateral ptosis and epiphora. *International ophthalmology*. 2008 Dec;28(6):429-31.
8. Ssi-Yan-Kai IC, Pearson AR. Recurrent giant orbital apocrine hidrocystoma. *Eye*. 2012 Jun;26(6):895.
9. Kim YD, Lee EJ, Song MH, Suhr KB, Lee JH, Park JK. Multiple eccrine hidrocystomas associated with Graves' disease. *International journal of dermatology*. 2002 May;41(5):295-7.
10. Sarabi K, Khachemoune A. Hidrocystomas-a brief review. *Medscape General Medicine*. 2006;8(3):57.
11. Pe'er J. Pathology of eyelid tumors. *Indian journal of ophthalmology*. 2016 Mar;64(3):177.
12. Amirhoushang E, Mostafa MS, Maryam A, Pardis N, Pedram N. Topical 0.03% atropine vs. 15% aluminum chloride in treating multiple eccrine hidrocystomas: A randomized single blind controlled study. *Indian journal of dermatology*. 2010 Jan;55(1):47.