

Case study

BEST's disease :case report

Abstract

Best disease, also called vitelliform macular dystrophy, is an autosomal dominant disease described by Frederick Best in 1905. It classically occurs in childhood and is characterized by macular deposits of vitelline material. We report the case of a 5-year-old female patient with no particular pathologic history. Ophthalmologic examination revealed corrected visual acuity of 10/10 for both eyes, and anterior segment examination was unremarkable. Fundus examination revealed a yellowish oval macular lesion with an irregular grayish center on the right and a yellowish macular focus on the left. Autofluorescence images showed bilateral perifoveal hyperautofluorescence with central hypo fluorescence. Macular optical coherence tomography (OCT) showed serous retinal detachment with retinal pigment epithelium (RPE) changes in both eyes and a hyperreflective subretinal deposit in the left eye. Paraclinical examinations, including electrophysiologic testing and angiography, could not be performed because of the young age. On examination of the ocular fundus of the mother and uncle, we discovered different stages of the same pathology. Considering this discovery, the age, and the bilateral nature of the disease, the diagnosis BEST was suspected and confirmed by genetic testing, which revealed a BEST1 mutation. We suggested a simple surveillance of the patient and her mother and uncle.

Keywords: Best disease, EOG, vitelliform macular dystrophy, autosomal, dominant, lipofuscin, serous detachment, atrophy, fibrosis.

Introduction

Best's disease or vitelliform macular dystrophy was first described by Friedrich Best in 1905. It is an autosomal dominantly inherited disease that classically occurs in childhood. It is a rare disease and occurs in about 1 in 10,000 people. It is characterized by macular deposits of lipofuscin-containing vitelline material in the retinal pigment epithelium, particularly in the foveal area, which is gradually reabsorbed, leaving an atrophic area of retinal pigment epithelium, often followed by subretinal fibrosis. Lesions are usually bilateral, but may be unilateral as well. We report a case of Best's disease in a 5-year-old child.

Case report

A 5-year-old white girl presented for a follow-up examination. Ophthalmologic examination revealed preserved visual acuity in both eyes (10/10), with no associated metamorphopsia. Anterior segment examination, intraocular pressure, and photomotor reflexes were normal. Fundus examination revealed a yellowish oval macular lesion with an irregular grayish center on the right and a yellowish macular focus on the left (figure 1). A subsequent autofluorescence showed bilateral perifoveal hyperautofluorescence with central hypo fluorescence. (figure 2). Optical coherence tomography of the macula showed the presence of a serous retinal detachment with altered RPE in both eyes and a hyperreflective subretinal deposit in the left eye (figure 3). Paraclinical examinations including electrophysiologic testing and angiography cannot be performed because of the young age. The age of the child

and the bilateral nature of the disease led us to suspect a diagnosis of Best disease. A family examination was performed, which revealed different stages of the same pathology in the mother and uncle. The diagnosis was confirmed by genetic testing, which revealed a mutation of the BEST 1 gene. No treatment was proposed for this patient, but simple surveillance of the patient and her mother and uncle was suggested.

Discussion

Best disease is an autosomal dominant inherited maculopathy with variable expressivity and penetrance. It usually begins between 3 and 15 years of age, with a median age of onset of 6 years [1]. Visual acuity usually remains adequate for many years, so that the disease is not recognized until much later stages. The atrophic stage usually occurs in people over 40 years of age. It is associated with a mutation in the bestrophin gene on chromosome 11 (11q131). [2]. The product of this gene is bestrophin1 protein, a transmembrane protein located mainly at the basolateral membrane of the RPE [3]. Bestrophin1 functions as a calcium-activated chloride channel and can also act as a channel for other anions, including bicarbonate [3]. In addition, it plays an important role in calcium homeostasis of the RPE [3]. Indeed, bestrophin plays a critical role in regulating the ionic milieu of the RPE and subretinal space. The ionic balance of the RPE is an important factor in the adhesion between the RPE and the retina. Altered ion flow could explain both the electrophysiologic findings and the lipofuscin accumulations. As a result, a decrease in the electrooculographic signal (EOG) is typical (Arden ratio less than 1.5). The EOG may be useful to detect asymptomatic carriers of the aforementioned mutation classically, ophthalmoscopic observation of the ocular fundus distinguishes several phenotypic developmental stages: the pre-vitelliform stage, the vitelliform stage, the pseudo-hypopyon stage, the vitelliruptive stage, and the atrophy stage. Subretinal neovascularization, which may develop in approximately 15% of cases, results in a sudden reduction in size of VA. Autofluorescence images show marked hyperautofluorescence characteristic of vitelliform material, although hypoautofluorescence predominates in advanced stages due to RPE atrophy. OCT allows identification of the site of deposition and the presence of subretinal fluid or RPE atrophy. Other examinations such as fluorescein angiography (which is not routinely performed unless macular neovascularization is suspected) and Ganzfeld and multifocal electroretinogram (ERG) may provide additional information to confirm the diagnosis of this disease. Despite the typical and striking macular changes, patients retain good vision. For this reason, a decrease in VA should raise suspicion of complications such as fibrosis, macular atrophy, or macular neovascularization. Best's disease must be differentiated from other dystrophies of the central part of the retina and choroid: Stargardt macular dystrophy, central areolar dystrophy, cone dystrophy, pseudo-inflammatory Sorsby dystrophy, North Carolina macular dystrophy, Le fundus flavimaculatus, age-related macular degeneration, central serous chorioretinitis, and retinal pigment epithelial detachment. [4]. There is no etiologic treatment for BEST disease. Patients with this disease should be monitored regularly for complications. Choroidal neovascularization (CNV) may benefit from the therapeutic contribution of anti-angiogenic agents, such as bevacizumab, which is being increasingly used. [5]. However, the long-term follow-up of these patients is unknown, and there are currently no clinical trials demonstrating their efficacy. Andrade et al. used verteporfin in photodynamic therapy (PDT) to treat subfoveal choroidal neovascularization [6]. They noted regression of CVN as well as disappearance of subretinal hemorrhage. The authors suggested that PDT may be a potential option for the treatment of CVN in vitelliform macular dystrophy of Best [6].

Conclusion

In a child with Best's disease, the parents and siblings should be examined and the diagnosis confirmed by EOG and global ERG if age permits. Molecular diagnosis allows for informed genetic counseling by identifying the responsible mutation, and patients should be monitored ophthalmologically for complications.

Declarations

Ethics approval and consent to participate

The authors declare that there is no conflict of interest that could be perceived as prejudicing the impartiality of this review.

Consent for publication

All authors consent to publication

Declaration of patient consent

The authors certify that they have obtained all appropriate patient consent forms. In the form the patient has given her consent for her images and other clinical information to be reported in the journal. The patient understand that her name and initials will not be published and due efforts will be made to conceal her identity, but anonymity cannot be guaranteed.

References

1. François J, De Rouck A, Fernandez-Sasso D (1967) Electro-oculography in vitelliform degeneration of the macula. *Arch Ophthalmol* 77: 726-733.
2. Stöhr H, Marquardt A, Rivera A, Cooper PR, Nowak NJ, et al. (1998) A gene map of the Best's vitelliform macular dystrophy region in chromosome 11q12-q13.1. *Genome Res* 8: 48-56
3. Johnson AA, Guziewicz KE, Lee CJ, Kalathur RC, Pulido JS, Marmorstein LY, Marmorstein AD, Bestrophin 1 and retinal disease. *Advances in retina and eye research*. 2017 May ;

4. Besch D, Zrenner E (2005) Best's disease. Orphanet Encyclopedia. 1-5.
5. Leu J, Schrage NF (2007) Degenring RF. Choroidal neovascularization secondary to Best's disease in a 13-year-old boy treated with intravitreal bevacizumab. Graefes Arch Clin Exp Ophthalmol 245:1723-5.
6. Andrade RE, Farah ME, Costa RA (2003) Photodynamic therapy with verteporfin for subfoveal choroidal neovascularization in best disease. Am J Ophthalmol 136: 1179- 1181.

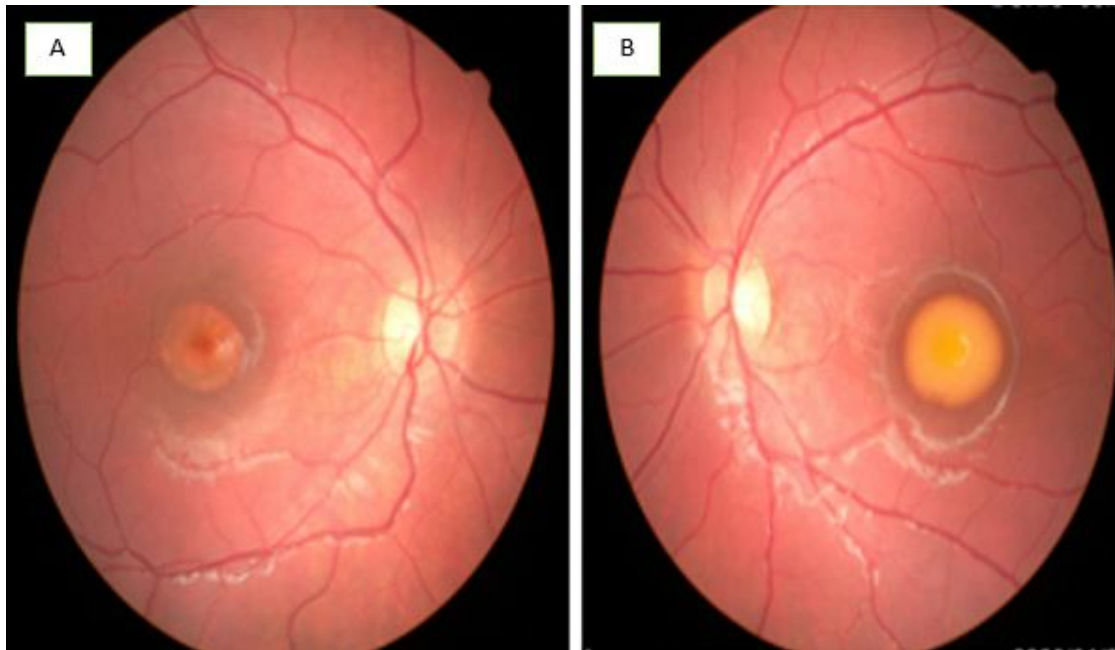


Figure 1: Retinography of both eyes with yellowish oval macular lesion A: right eye /B: left eye

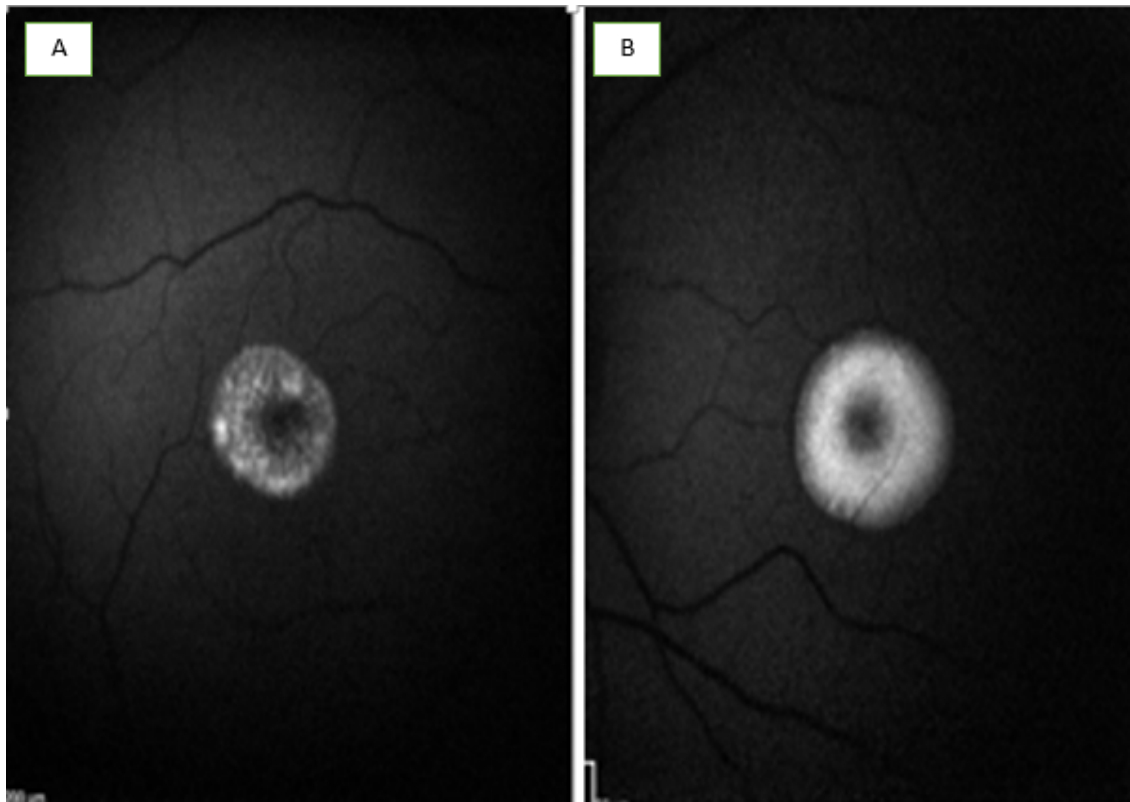


Figure 2: Autofluorescence image showing bilateral perifoveal hyperautofluorescence and central hypofluorescence. A: right eye /B: left eye

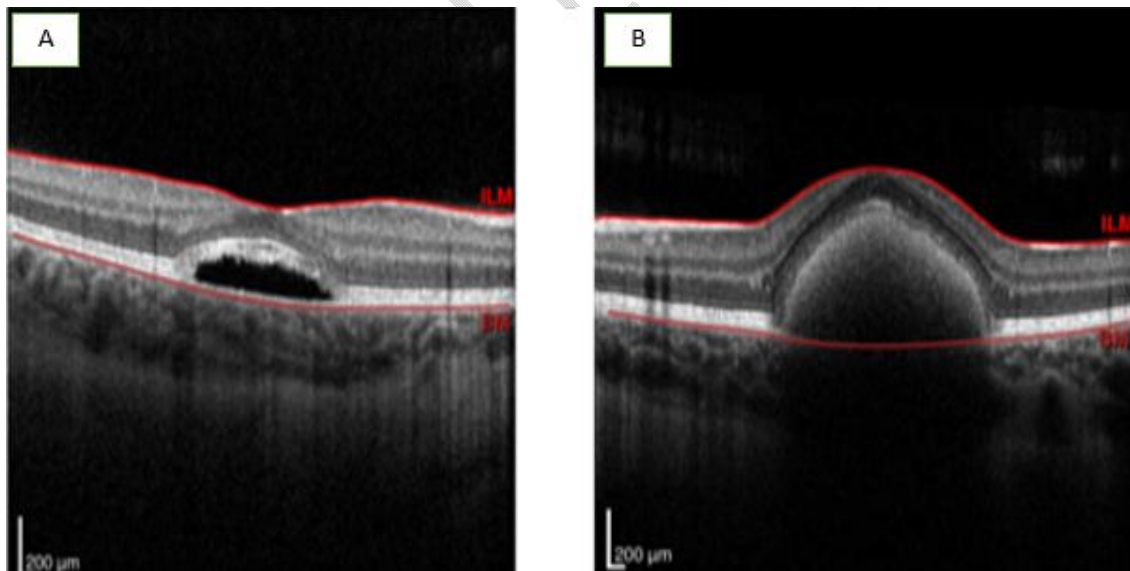


Figure 3: Macula OCT (Optical coherence tomography) showing seroretinal detachment with altered retinal pigment epithelium in the right eye (A), seroretinal detachment and hyperreflective subretinal deposits in the left eye.