

Case report

Surgical management of mesenteric cyst in in infra hepatic area:A Case Report

ABSTRACT :

Mesenteric or mesothelial peritoneal cysts (PMC) are rare and benign tumors, and their classification and etiology are still controversial. Although often asymptomatic, they are almost always treated surgically. Here, we present the case of a 61-year-old woman with intermittent hepatic colic for the past two months. Although her abdominal ultrasound revealed an infrahepatic hydatid cyst, hydatid serology was negative. A CT scan showed a mesenteric cyst, and exploratory laparoscopy revealed a mesenteric peritoneal cyst that was successfully resected. Histopathological examination confirmed its peritoneal origin.

Keywords: PMC (Peritoneal Mesenteric Cyst), Abdominal mass, Laparoscopy, Management, Case report.

INTRODUCTION :

Mesenteric cysts are rare intra-abdominal tumors, most commonly benign, with a current incidence of about 1 per 100,000 adults and 1 in 20,000 cases in children (1). Peritoneal simple mesothelial cysts, according to the Perrot classification, can be benign or malignant (2). The clinical presentation is diverse but generally asymptomatic. Sometimes they are discovered during acute complications such as obstruction or infection. In other situations, they are diagnosed accidentally during radiological examinations for non-specific symptoms (3). The most common location of these lesions is the mesentery of the small intestine (60%), followed by the mesentery of the large intestine (24%) and the retroperitoneal region (14.5%) (4). The etiology of these cysts is controversial, but some theories suggest an embryological origin. Preoperative diagnosis remains difficult due to the rarity of this pathology and the vague symptomatology. Medical imaging and histology confirm the diagnosis.

The treatment of choice is surgical excision, preferably laparoscopic, with a low recurrence rate and an excellent prognosis (5). Knowledge of these lesions is crucial due to their significant complications.

CASE REPORT ;

A 61-year-old woman with a two-month history of intermittent, moderate right upper quadrant colicky pain that radiated to the right shoulder, especially after meals, and associated with constipation. She had no history of fever, jaundice, melena, or hematemesis. The patient was treated symptomatically with analgesics and charcoal, which resulted in resolution of her constipation, but she continued to have vague right upper quadrant pain. Her medical history was unremarkable.

On physical examination, vital signs were normal, with no jaundice or cutaneous-mucous pallor. Abdominal examination revealed a positive Murphy's sign and tenderness in the right upper quadrant. The rest of the clinical examination was unremarkable.

Laboratory tests, including liver function tests (such as alanine aminotransferase (ALT), aspartate aminotransferase (AST), alkaline phosphatase (ALP), and total bilirubin), basic metabolic panel (such as sodium, potassium, chloride, bicarbonate, blood urea nitrogen (BUN), creatinine, and glucose), and tumor markers, were normal. Abdominal ultrasound revealed an infrahepatic hydatid cyst measuring 81mm x 73mm, with a well-defined hyper-echoic wall surrounding thick liquid content. Based on her clinical and radiological features, a diagnosis of hydatid cyst was made. Serology for hydatidosis was negative.

A CT scan was performed to confirm the diagnosis, which revealed a thin-walled mesenteric cystic lesion (with a few calcifications), with highly hypodense content (measured fatty density of 170 HU) and an intracystic, hypo-dense, sloping formation measuring 72mm x 71mm in the infrahepatic region (Figure 1).

After extensive discussion, surgical treatment was proposed. An exploratory laparoscopy revealed a lobulated mesenteric cyst in the mesentery of the right colonic angle, and complete enucleation of the cyst was performed without disturbing the colonic frame (Figure 2). Postoperative recovery was uneventful.

Histopathological examination showed a cystic mass measuring 7µm x 6mm x 5mm. On section, the wall was thin, the surface was smooth, and the material was yellowish. Microscopic examination revealed a cystic wall whose lining was largely abraded, resting on fibrous connective tissue remodeled by a mild-density inflammatory infiltrate with congestive vessels (Figure 3).

DISCUSSION

Peritoneal mesothelial or mesenteric cysts (PMC) are very rare benign tumors that mostly occur in young individuals and rarely in older ones (6). These cysts can occur at any part of the gastrointestinal mesentery but are predominantly localized with 60% preference in the small bowel mesentery, 24% throughout the colonic flexure, 14.5% in the retroperitoneum, and 1.5% of unknown cause (7).

The etiology of these mesenteric cysts is still uncertain, but different theories suggest that the obstruction of lymphatic vessels, either by trauma, infection, or degeneration, prevents communication

between different lymph nodes (8). According to a theory proposed by GROSS, it is the benign proliferation of ectopic lymphatic vessels in the mesentery with the accumulation of lymphatic fluid in a closed cavity created between the two mesenteric folds (9).

Peritoneal cysts have a varied clinical presentation, but most of the time they are asymptomatic in 50% of cases (10). They can be discovered during an etiological assessment carried out for another pathology. Symptoms range from mild abdominal pain (82%) and nausea and vomiting (45%) to constipation (27%), abdominal distension (61%), and palpable mass (44%) (11). However, they can reach extreme sizes, presenting with intestinal obstruction, abdominal deformity, peritonitis by cyst perforation, or compression of adjacent organs (12). Some authors suggest that these symptoms occur when the size of the cyst exceeds 5 cm (13).

The diagnosis of peritoneal cysts relies on clinical presentation and mainly on imaging such as ultrasound, computed tomography, and magnetic resonance imaging. On abdominal ultrasound, PMC appears as an anechoic mass with acoustic enhancement (14). Computed tomography and magnetic resonance imaging show the cystic nature of the lesion as well as provide information on its content and location. However, mesenteric cysts can be diagnostically challenging due to their location.

The treatment of choice is surgical excision, but it may differ depending on the symptoms. For asymptomatic cysts, no treatment is recommended. For symptomatic cysts, radical treatment by laparoscopic excision is most commonly used (15), and it has shown its efficacy in preventing some complications such as volvulus, spillage of infected content, and occlusion or adhesion (16), as other methods were associated with a high recurrence rate (17). Intestinal resection is sometimes necessary if the cyst invades the small intestine or one of the mesenteric vessels. Mesenteric cysts have an excellent prognosis with a low risk of malignant transformation, and their complete excision is curative with minimal surgical complications, mortality, and no risk of recurrence (18).

The ultimate diagnosis depends on the histopathological results. Simple mesenteric cysts on sectioning consist of a unilocular thin-walled cyst containing serous fluid, histologically consisting of cuboidal or cylindrical epithelium or flat mesothelial cells (19). Immunohistological analysis shows the positivity of mesothelial cells for factors such as ethidium monazide and total keratin, and they are negative for VIII and CD31 (20).

In summary, PMC are rare benign tumors that can occur at any part of the gastrointestinal mesentery but have a predominant location in the small bowel mesentery. Their etiology is still uncertain, but different theories suggest an obstruction of lymphatic vessels or a benign proliferation of ectopic lymphatic vessels. Mesenteric cysts have a varied clinical presentation, but most of the time, they are asymptomatic. The diagnosis relies on clinical presentation and mainly

CONCLUSION

Simple mesenteric cysts are benign tumors with vague and nonspecific symptoms, and imaging methods can cause confusion in interpretation. Surgical exploration, especially through laparoscopy, provides the final diagnosis and reduces rates of complications and morbidity associated with open surgery. Complete excision offers the best surgical option, and the final diagnosis is confirmed through histopathological examination.

INFORMED CONSENT

Written informed consent from the patient was obtained for the publication of this case report and any accompanying images. A copy of the written consent is available for review by the editor-in-chief of this journal.

REFERENCES

1. Yusuf Yavuz ,Alper Varman , Üyesi Mustafa Şentürk , Mehmet Tolga Kafadar“Mesenteric cyst in 22 cases,” *Journal of Gastrointestinal Cancer*, vol. 52, no. 3, pp. 20–23, 2020.doi: 10.1007/s12029-020-00522-9. Epub 2020 Sep 24.
2. de Perrot M., Bründler M., Tötsch M., Mentha G., Morel P. Mesenteric cysts. Toward less confusion? *Digestive Surgery*. 2000;17(4):323–328. doi: 10.1159/000018872. [PubMed] [CrossRef] [Google Scholar]
3. Kurtz RJ, Heimann TM, Beck AR, Holt J. Mesenteric and retroperitoneal cysts. *Ann Surg*. 1986; 203:109–12. [PMC free article] [PubMed] [Google Scholar]
4. A.K. Pithawa, A.S. Bansal, S.P.S. Kochar Mesenteric cyst: a rare intra-abdominal tumour *Med. J. Armed Forces India*, 70 (1) (2014 Jan), pp. 79-82
5. Theodoridis TD, Zepiridis L, Athanatos D, Tzevelekis F, Kellartzis D, Bontis JN: Laparoscopic management of mesenteric cyst: a case report. *Cases J*. 2009, 2:132. 10.1186/1757-1626-2-132
6. Theodoridis T.D., Zepiridis L., Athanatos D., Tzevelekis F., Kellartzis D., Bontis J.N. Laparoscopic management of mesenteric cyst: a case report. *Cases J*. 2009;2:132. doi:

- 10.1186/1757-1626-2-132. Published 2009 Feb 8. [PMC free article] [PubMed] [CrossRef] [Google Scholar]
7. De Perrot M, Brundler MA, Totsch M, et al. Mesenteric cysts. Towards less confusion? *Dig Surg.* 2000;17:323–8. [PubMed] [Google Scholar].
 8. Saviano M.S., Fundaro S., Gelmini R., Begossi G., Perrone S., Farinetti A. Mesentericcysticneoforations: report of two cases. *Surg. Today.* 1999;29:174–177. [PubMed] [Google Scholar]
 9. Richard R.R. Mesenteric and omental cysts. In: Grosfeld J.L., O'Neill J.A. Jr., Coran A.G., Fonkalsrud E.W., editors. *Pediatric Surgery.* 6th ed. Mosby Elsevier; Philadelphia: 2006. pp. 1399–1406. [Google Scholar]
 10. Damian M. Carragher, Javier Rangel-Moreno, and Troy D. Randall Ectopic lymphoid tissues and local immunity *Semin Immunol* 2008 Feb;20(1):26-42. doi: 10.1016/j.smim.2007.12.004.
 11. Tan JY, Tan KK, Chew SP. Mesenteric cysts: An institution experience over 14 years and review of literature. *World HJ Surg.* 2009;33:1961–5. [PubMed] [Google Scholar].
 12. Pithawa AK, Bansal AS, Kochar SP: Mesenteric cyst: a rare intra-abdominal tumor *Med J Armed Forces India.* 2014 Jan; 70(1): 79–82. doi: 10.1016/j.mjafi.2012.06.010
 13. Patel A, Lefemine V, Ramanand BS: A rare case of a peritoneal cyst arising from the falciform ligament. *Cases J.* 2009, 2: 134-10.1186/1757-1626-2-134.
 14. Stoupis C, Ros PR, Abbitt PL, Burton SS, Gauger J: Bubbles in the belly: imaging of cystic mesenteric or omental masses. *Radiographics.* 1994, 14: 729-737.
 15. Dario Bono, Francesco Tomaselli, Rinaldo Caponi, and Roberto Saracco Laparoscopic excision of a voluminous mesenteric cyst: Case report of a rare entity and review of literature *Int J Surg Case Rep.* 2020; 77(Suppl): S64–S66. doi: 10.1016/j.ijscr.2020.10.042
 16. K. Razi, O. Al-Asaad, R. Milind Case report: elective removal of a large mesenteric cyst-our approach *J. Surg. Case Rep.* (3) (2017) rjx063
 17. Sahin DA, Akbulut G, Saykol V, San O, Tokyol C, Dilek ON: Laparoscopic enucleation of mesenteric cyst: a case report. *Mt Sinai J Med.* 2006, 73: 1019-1020.
 18. H. Ousadden, H., K. Elboughaddouti, Ibnmajdoub, H., T. Harmouch, K. Mazaz, K. Ait Taleb A giant peritoneal simple mésothéliale cyst: a case report, *Journal of Medical Case Reports* volume 5, Article number: 361 (2011).
 19. Hassan M, Dobrilovic N Large gastric mesenteric cyst: case report and literature review.. *Am Surg.* 2005;71:571–573.
 20. Miljković D, Gmijović D, Radojković M, Gligorijević J, Radovanović Z: Mesenteric cysts. *Arch Oncol.* 2007, 15: 91-93. 10.2298/AOO0704091M.

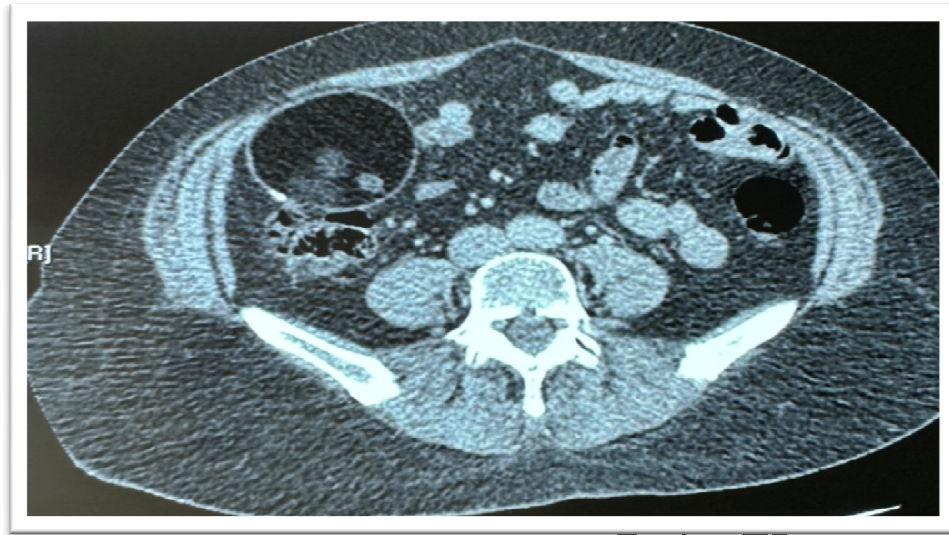

Figure 1: Abdominal CT scan showed a thin-walled mesenteric cystic lesion (with a few calcifications), with highly hypodense content (measured fatty density of 170 HU) and an intracystic, hypo-dense, sloping formation measuring 72mm x 71mm in the infrahepatic region.

UNDER PEER REVIEW

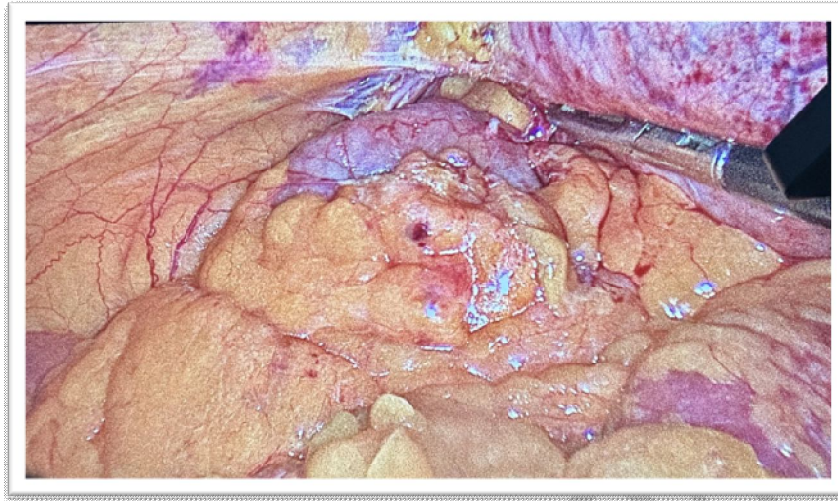

Figure 2: Intraoperative image showing a cyst arising from the mesentery at a distance from the right colonic

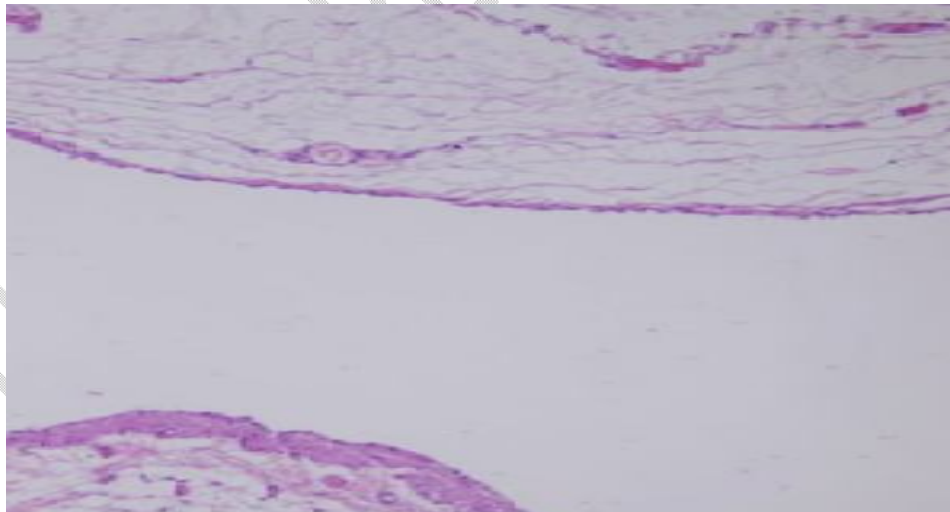


Figure 3: Histopathology of the mesenteric cystic wall; a single layer of epithelial lining surrounded by fibrous structure (H&E, $\times 100$).

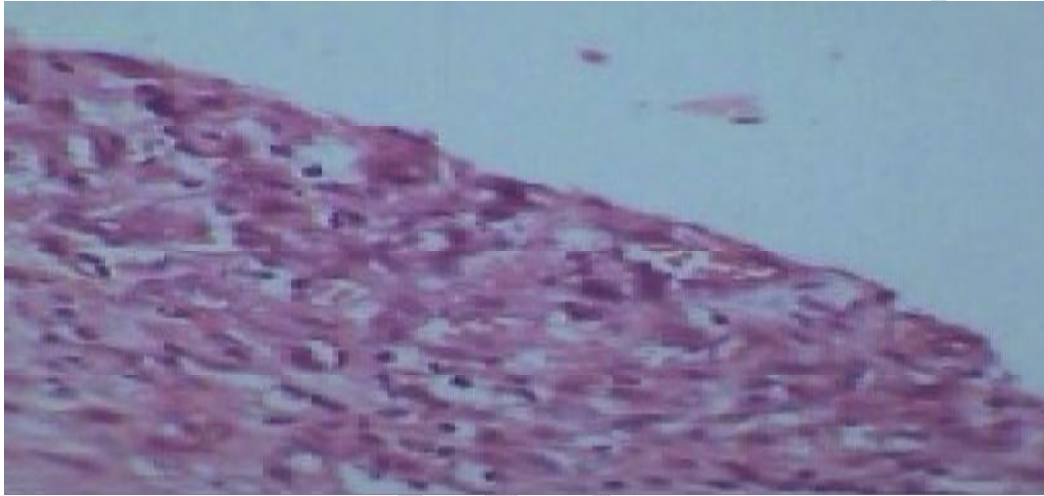


Figure 4. Mesenteric Cystin infra hepatic area