

Case study

Cystic intestinal pneumatosis revealed by stomach pain: a case report

Abstract:

Cystic intestinal pneumatosis is a rare condition characterized by the presence of gaseous cysts in the intestinal wall, which can affect the entire digestive tract, with a predilection for the small intestine and the colon. The diagnosis is evoked on the scanner, making it possible to avoid surgical intervention in the absence of complications. We report a rare observation of pneumatosis cystica colica, source of stomach (abdominal) pain whose chest X-ray (radiograph) showing (demonstrated) pneumoperitoneum requiring surgical intervention.

Keywords: cystic intestinal pneumatosis- stomach pain, (abdominal pain or pain abdomen)

Introduction:

Cystic intestinal pneumatosis is a rare entity, defined by the presence of cysts of gaseous content in the intestinal wall (1) which remains poorly understood, posing diagnostic and therapeutic problems (1,2). It can be primary or secondary associated with multiple gastrointestinal pathologies. We report the observation of a primary cystic intestinal pneumatosis revealed by a stomach pain whose chest X-ray showing pneumoperitoneum requiring surgical intervention.

Case presentation:

Patient was 41-year-old man.

He had no medical history.

He was referred to our emergency, he had stomach pain and a swollen belly.

He had no external gastrointestinal bleeding.

On examination, he was afebrile, with normal respiratory rate and normal resting heart rate.

The abdomen was sensitive on palpation.

The chest X-ray showed pneumoperitoneum.

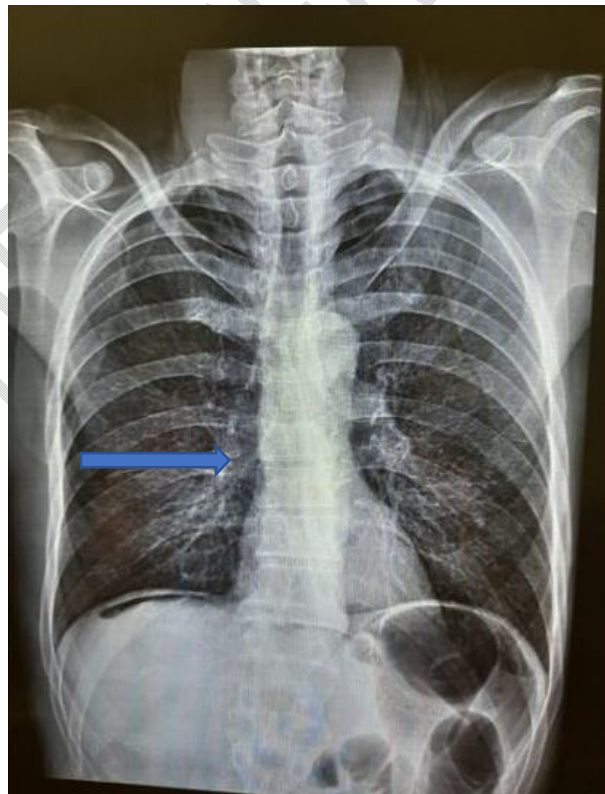

Figure 1 : The chest X-ray showing pneumoperitoneum

On the same admission day, the patient was transferred to the operating room.

He gave his approval to do surgery.

During laparotomy under general anesthesia, the exploration showed cystic pneumatosis intestinalis and there is no sign of peritonitis.

UNDER PEER REVIEW

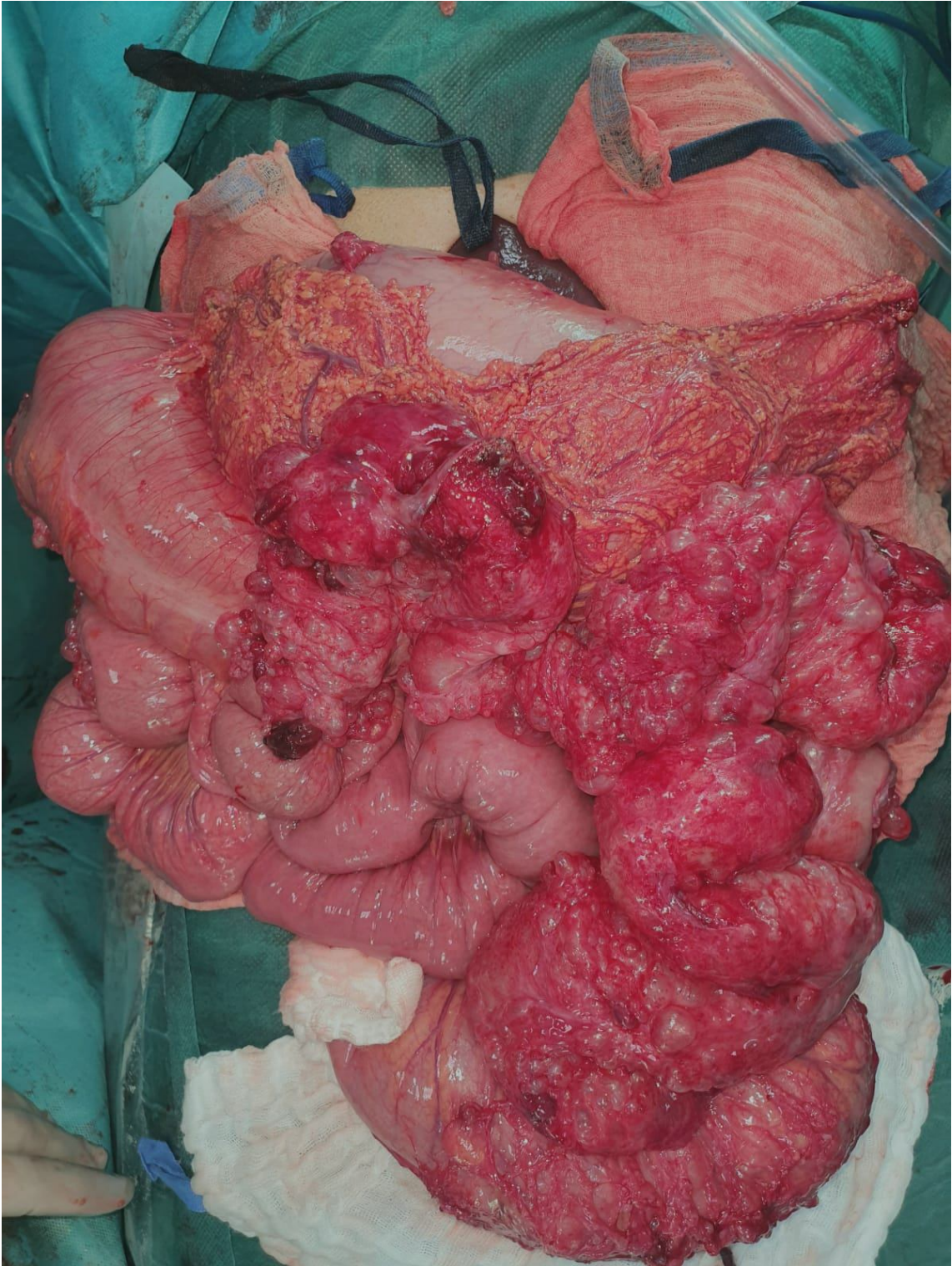


Figure 2 : cystic pneumatosis intestinalis

The abdomen was closed with all precautions and counts of surgical items.

The post-operative care was simple, he was discharged from hospital on postoperative day 5 with a medical treatment.

Discussion :

Intestinal cystic pneumatosis is a rare condition characterized by the presence of gaseous cysts in the intestinal wall, which can affect the entire digestive tract, with a predilection for the small intestine and the colon (1).

In anatomical pathology, the cystic formations are especially developed in the submucosa in particular in the colic attacks, and/or in the subserous in particular small intestine (2). Cystic intestinal pneumatosis preferentially affects men between 40 and 50 years old and is often secondary or associated with other gastrointestinal pathologies (inflammatory bowel disease, peptic ulcer, pyloric stenosis, abdominal trauma) or extra gastrointestinal (broncho-pneumopathy chronic obstructive disease, heart disease, cystic fibrosis, lupus, periarteritis nodosa), the primary forms are uncommon (3).

In our patient, given the absence of associated pathologies, we concluded that he had primary cystic pneumatosis. The mechanism of formation and maintenance of gaseous cysts is multifactorial, involving in variable parts several components: loss of integrity of the mucosa (infectious or inflammatory damage), elevation of endoluminal

pressure, changes in the bacterial flora, constitutional and/or acquired and hyperproduction of intestinal gas with disruption of their degradation mechanisms (4).

Cystic intestinal pneumatosis is usually pauci-symptomatic. It can be revealed by non-specific signs in 30% of cases: diarrhea, bloody or mucous stools, meteorism, vomiting, constipation, tenesmus.

Intestinal obstruction is a rare complication related to the number and bulky size of cysts that can narrow the intestinal lumen and lead to an occlusive syndrome (5).

Other complications related to cystic volume have been described: volvulus, intussusception, perforation, hemorrhage (6).

Computed tomography has good diagnostic accuracy. It reveals images of gas density in the digestive wall, better visible in the pulmonary window (5).

Multiplanar reconstructions make it possible to precisely study the topography, volume and extent of the cysts. The association with asymptomatic pneumoperitoneum is almost pathognomonic (1).

Ultrasound examination is non-specific, it may suspect the diagnosis by showing thinning of the intestinal wall and echoes with acoustic shadow (6,7).

Endoscopic examinations confirm submucosal cysts, which produce a characteristic noise when they are collapsed by the biopsy forceps (popping sound). There is an important diagnostic criterion to make the differential diagnosis with acute intestinal pneumatosis or

intestinal gangrene is the absence of aeration on computed tomography or ultrasound (6). The treatment is still poorly codified, it is most often a medical treatment whose goal is to reduce or eliminate the cysts by reducing the anaerobic bacteria that cause them. It calls for lifestyle and dietary measures, anti-anaerobic antibiotic therapy with metronidazole (7, 3) and hyperbaric oxygen therapy. Surgical treatment is indicated in the event of complications, in the event of symptoms resistant to medical treatment and in the event of associated surgical pathology. It consists in resecting the intestinal segment affected by laparotomy or even better by laparoscopy (7).

Conclusion :

Cystic intestinal pneumatosis is an uncommon affection, often asymptomatic and benign. Its recognition is important to avoid undertaking abusive therapeutic attitudes, that's why Computed tomography is recommended.

Consent

As per international standard or university standard, patient(s) written consent has been collected and preserved by the author(s).

Ethical Approval:

As per international standard or university standard written ethical approval has been collected and preserved by the author(s).

References

1. Goel A, Tiwari B, Kujur S, Ganguly PK. Pneumatosis cystoides intestinalis. *World J Gastroenterol*. 2011;17(44):4932–4936
2. Behnoush B, Bazmi B, Mohammadi F, Bazmi E, Dorvashi GA. Pneumatosis Intestinalis: Autopsy Finding. *Acta Medical Iranica*. 2009;47(5):415–417.
3. Serraj I, El kihal N, Mohcine R, Essaid A. Pneumatose kystique intestinale avec ascite: association exceptionnelle. *Acta Endoscopica*. 2006;36(3):357–362.
4. Rivera Vaquerizo PA, Caramuto Martins A, Lorente García MA, Blasco Colmenarejo M, Pérez Flores R. Pneumatosis cystoides intestinalis. *Rev Esp Enferm Dig*. 2006;98(12):959–961.
5. Lê P, Benazzouz A, Fritsch L. Une pneumatose kystique colique révélée par un syndrome pseudo occlusif. *Ann Chir*. 2003;128(2):117–120.
6. Braham R, Said M, Rehaïem A, Jerbi Omezzine S, Memmi F, Bouabid Z, et al. Imagery of pneumatosis cystica intestinalis. *J Chir*. 2004;14(3):201–204.
7. El Bouhaddouti H, Ousadden A, Benjelloun B, Mazaz K, Aït Taleb K. Pneumatose kystique iléale révélée par un volvulus du grêle. *Pan Afr Med J*. 2010;6:9