

# Prognostic value and clinical significance of LAMP3 (CD208) expression in oral squamous cell carcinoma: An immunohistochemical study

## ABSTRACT

**Context:** Early detection of Oral Squamous Cell Carcinoma (OSCC) can improve treatment outcomes and prognosis as OSCC development is an intricate complex mechanism with multifactorial causes. LAMP3 (Lysosome Associated Membrane Protein 3) serves as a useful marker for the prognosis and monitoring of OSCC. It is induced progressively upon the maturation of human dendritic cells. Growing evidence shows that LAMP3 is over-expressed in various human tumors and resistant to therapies suggesting LAMP3 could become a molecular marker for the prognosis of various cancers.

**Aims:** This study aimed to examine the protein level of LAMP3 expression in OSCC tissue samples and determine the relationship between LAMP3 and clinical characteristics of OSCC patients by immunohistochemical (IHC) analyses.

**Settings and Design:** Descriptive observational study.

**Methods:** This study included 35 histopathologically diagnosed cases of OSCC and 35 samples of normal oral mucosa obtained from the Department of oral and maxillofacial pathology with demographic and clinicopathological documents. LAMP3 expression was measured by IHC staining.

**Statistical analysis used:** Statistical package for the social software version 23.

**Results:** The protein levels of LAMP3 were significantly higher in OSCC tissues than in normal tissues ( $p < 0.001$ ). Also, high LAMP3 expression was notable to the degree of tumor differentiation and advanced TNM staging, and metastases staging.

**Conclusions:** The significantly greater LAMP3 expression in OSCC indicates LAMP3's role in carcinogenesis of oral mucosa suggesting LAMP3 might be a novel prognostic marker and an anticancer target to predict disease pathogenesis in OSCC patients.

**Keywords:** Clinico-pathological, Grade, Normal oral mucosa, CD208, Oral Cancer, Stage.

## 1. INTRODUCTION

“Oral squamous cell carcinoma is considered as a large subgroup of head and neck squamous cell carcinoma and engages more than 90% of malignancies in the oral cavity”,<sup>1,2</sup> “OSCC is a tobacco and alcohol-related cancer; however, it can also evolve in the absence of tobacco and alcohol consumption”.<sup>3,4</sup> “Worldwide, more than 1,918,030 new cases of cancer are diagnosed annually, of which 54,000 accounts for oral cancer”.<sup>5,6</sup> “The incidence of oral cancer is highest

in India and Southeast Asian countries. In India, 90-95% of oral cancers are squamous cell carcinoma; whereas, in high-risk countries (i.e. India, Sri Lanka, Bangladesh, and Pakistan), **Oral cancer** is the most common cancer in men and the third most common cancer in women".<sup>7</sup> Using the novel diagnostic methods related to molecular markers could provide earlier or faster OSCC patient prognosis.

"Lysosome associated membrane proteins 3 (LAMP3/CD208/DC-LAMP), represents a family of glycosylated proteins present predominantly on the membrane of lysosomes, induced progressively upon maturation of human dendritic cells (DCs)".<sup>8</sup> "LAMP3 is over-expressed in various human tumors, where it correlates with poor prognosis".<sup>9</sup> "This marker is associated with tumor metastasis"<sup>10</sup>. "High LAMP3 expression is seen in primary cancers compared to normal tissues, including cancers of the esophagus, colon, fallopian tube, ovary, uterus, breast, and liver".<sup>11</sup> "Consequently, LAMP3 expression may be a predictor of cancer patient survival".<sup>2</sup> Investigations regarding LAMP3 expression and its association with OSCC patient's clinical features and pathological characteristics are lacking in india; hence, **we aimed to examine** LAMP3 expression in OSCC tissue samples and normal oral epithelium by immunohistochemistry (IHC) analyses. Furthermore, the relationship between LAMP3 expression and OSCC patient demographic features and histological characteristics were assessed. Our results provide evidence that the LAMP3 expression might be an innovative anticancer target for OSCC therapy.

## 2. MATERIAL AND METHODS

This study was performed at the Department of Oral and Maxillofacial Pathology, Dental College and Hospital, **Nagpur, India (2017 to 2020)** and was approved by the Institutional Ethics Committee Dental College and Hospital, **Nagpur, India.**

### Study design

This was a descriptive observational study.

### Study participants and sample preparation

The study included 35 **histopathologically diagnosed cases** of OSCC (11 WDSCC, 15 MDSCC & 9 PDSCC) and 35 samples of normal oral mucosa (17 Gingiva, 4 Tongue, 4 Retromolar Region, 3 Buccal Mucosa, 3 Palate & 2 Frenum) for IHC analysis were obtained as paraffin blocks from the archives of our registry, Department of Oral Pathology & Microbiology, Dental College (2016 to 2019). The samples included were divided into two groups; Group I, Normal Oral Mucosa (NOM) and Group II, OSCC. All clinical characteristics such as gender, age, habits (tobacco and alcohol consumption), differentiation and tumor location, were obtained from the medical records of patients in Department of Oral and Maxillofacial Pathology, Dental College & Hospital.

OSCC patients who had received no treatment until the time of sampling, no preoperative radiotherapy, immunotherapy or chemotherapy, no systemic diseases and no other skin or oral diseases were included. In addition, we included all paraffin block specimens with sufficient lesion volume for testing.

## IHC Staining

We performed IHC staining to detect the protein expression of LAMP3 in 35 documented paraffin-fixed samples of OSCC, 35 samples of the normal oral mucosa, and 10 samples of the **normal** lymph node. "The whole tissue blocks were constructed to tissue microarrays (TMA) in preparation. TMAs were then deparaffinized with 100% xylene and rehydrated in graded alcohol. Antigen retrieval was performed by boiling in citrate buffer (pH 6.0) for 10 min in an autoclave, followed by quenching in 3% hydrogen peroxide to block endogenous Peroxidase activity. After washing with phosphate-buffered saline (PBS), slides were incubated with rabbit polyclonal anti-LAMP3 antibody (ab111090; 1:100 dilution) at 4°C overnight. On the next day, sections were incubated with biotinylated goat anti-rabbit secondary antibody at room temperature for 30 min. Following washing with PBS, the slides were processed using horseradish Peroxidase and dyed with 3, 3-diaminobenzidine (DAB) chromogen solution. Finally, the sections were counterstained with hematoxylin, dehydrated, and mounted with a coverslip using DPX (dibutyl phthalate polystyrene xylene)".<sup>1</sup>

Two independent pathologists evaluated the results of IHC staining in a double-blind manner to eliminate inter-observer bias. "The Immunohistochemical expression of LAMP3 was assessed in OSCC in basal and suprabasal layers of dysplastic epithelium, infiltrated islands of malignant epithelial cells within stroma by evaluation of staining intensity & percentage of positive (LAMP3) cells according to the method used by Etemad –Moghadam et al.<sup>12</sup> Briefly, we scored the Percentage of LAMP3- positive cells (A) as follows: 0% for no positive cells, 1% for 1-33 % positive cells, 2% for 34-66% positive cells, and 3% for 67-100% positive cells". "The Staining intensity of LAMP3 (B) was calculated as 0% for no staining, 1% for weak staining (in parts where positivity was observed only at a magnification of 40x), 2% for moderate staining (in cases where the staining intensity was obvious at 10x, but not at 4x) and 3% for strong staining (in fields where immunopositive cells were seen even at 4x). The Staining index was calculated of each specimen as follows-Percentage of immunopositive cells (A) multiplied by intensity score (B) i.e.  $A \times B = \text{Staining index}$ . This staining index was classified as: 0 = Zero( Absent); 1,2 = Low; 3,4 = Moderate/ Medium; 6-9 = High".<sup>13</sup>

## Statistical analysis

Data were analyzed using SPSS software version 23 as described previously.<sup>9</sup> Descriptive statistics for scale data, frequencies for categorical data, and One-way ANOVA was done for comparison. The comparison of Bryne's grading and interpretation of staining was done by using the Chi-square test.<sup>14</sup> The comparison of staining parameters distribution between OSCC and normal epithelium, within various grades of OSCC group was compared using One-way ANOVA. The data on demographic parameters like age and gender was expressed in terms of numbers and percentage for each study group. Also the mean and standard deviation were obtained for age of patients in both the groups. Frequencies were obtained for site distribution in each group. The staining status of each marker in both groups was compared using Chi-square test. Distribution of study population according to gender was by using Chi-square test. The mean age of study population comparison was done by using One-way ANOVA. P values less than 0.001 were considered statistically significant.

## 3. RESULTS

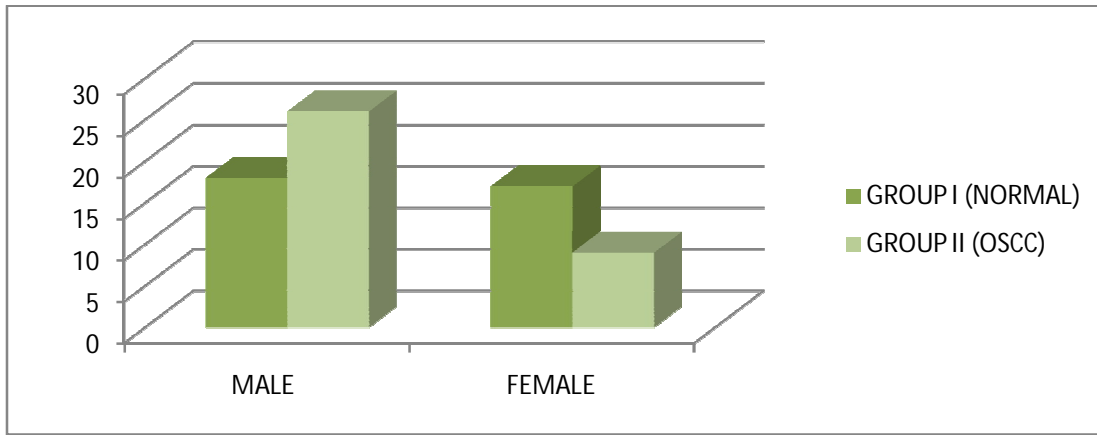
In the normal group (GROUP I) out of 35 cases, 18 (51.4%) were males and 17 (48.6%) were females. In the OSCC group (GROUP II) out of 35 cases, 26 (74.3%) were males, and 9(25.7%) were females. Predominantly male cases were part of the study group (Graph 1).

In the normal group, maximum cases belonged to the age group of  $\leq 30$  years i.e. 18 (51.4%) followed by 14 (40%) cases in the age group of 31-50 years followed by 3 (8.6%) cases in the age group of 51 – 70 years and none in the age group of  $\geq 71$  years. Whereas, in the OSCC group, maximum cases belonged to the age group of 31 – 50 years i.e. 4<sup>th</sup> to 5<sup>th</sup> decade [19 (54.5%)] followed by 10(28.6%) cases in the age group of 51 – 70 years i.e. 6<sup>th</sup> to 7<sup>th</sup> decade followed by 5(14%) cases in the age group of  $\leq 30$  years and 1(2.9%) case in the age group of  $\geq 71$  years. The mean age of patients of Group I was 33.4 years and Group II was 45.6 years (Graph 2). In OSCC group, lesions were located predominantly on alveolobuccal complex 14 (40%), followed by buccal mucosa 12 (35%), tongue 5(14%) and labial mucosa 4 (11%) (Graph 3).

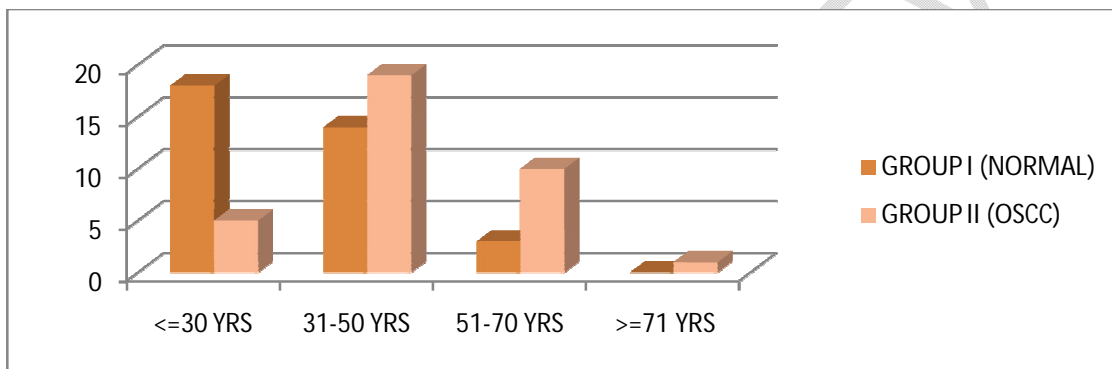
Out of 35 OSCC cases, 11(31.4%) had Well Differentiated Squamous Cell Carcinoma (WDSCC), 15(42.9%) had Moderately Differentiated Squamous Cell Carcinoma (MDSCC) and 9(25.7%) had Poorly Differentiated Squamous Cell Carcinoma (PDSCC) according to Bryne's grading (Graph 4).

The staining status in the normal group showed that all 35 (100%) cases had negative staining status and in the OSCC group, 30 (86%) cases showed positive staining status, and 5 (14%) cases showed negative staining. Brown color staining was found in the cytoplasm of basal and suprabasal layers of dysplastic epithelium, in malignant epithelial cells infiltrated in the connective tissue in the form of sheets, islands, strands, cords, and dissociated groups of cells (figure 1). The proportion of subjects with positive staining in the two groups was statistically highly significant with a p-value  $<0.001$  as obtained by using One way ANOVA test.

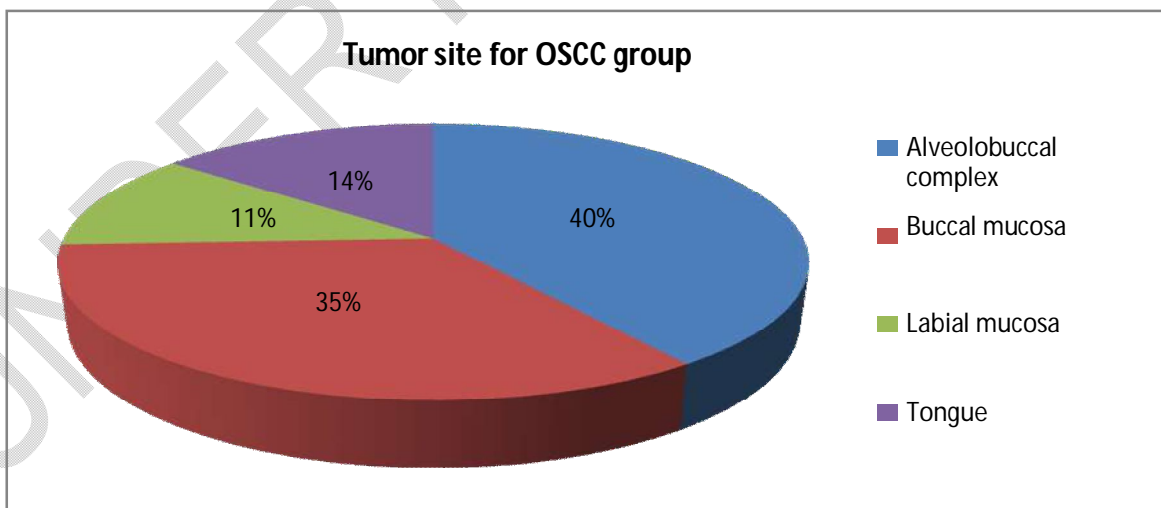
The Percentage of positive cells in the normal group showed no positive LAMP3 expression, the mean value of positive cells was zero. However, in the OSCC group, 30 cases showed positive LAMP3 expression, the mean value of positive cells was  $1.6 \pm 0.97$ . The difference between mean values of positive cells in the two groups was statistically highly significant with a p-value  $<0.001$  as obtained by using One way ANOVA test (table 1). Also, the percentage of positive cells in the normal group and OSCC subgroups showed that, of the 11 cases with WDSCC, the mean number of positive cells (LAMP3) was  $1.45 \pm 1.03$ , while in 13 cases with MDSCC, the mean number of positive cells (LAMP3) was  $1.8 \pm 1.08$  and of the 8 cases with PDSCC, the mean number of positive cells (LAMP3) was  $1.44 \pm 0.72$ . The difference between mean values of positive cells in the above groups was statistically highly significant with a p-value of  $<0.001$  as obtained using a one-way ANOVA test (table 2).



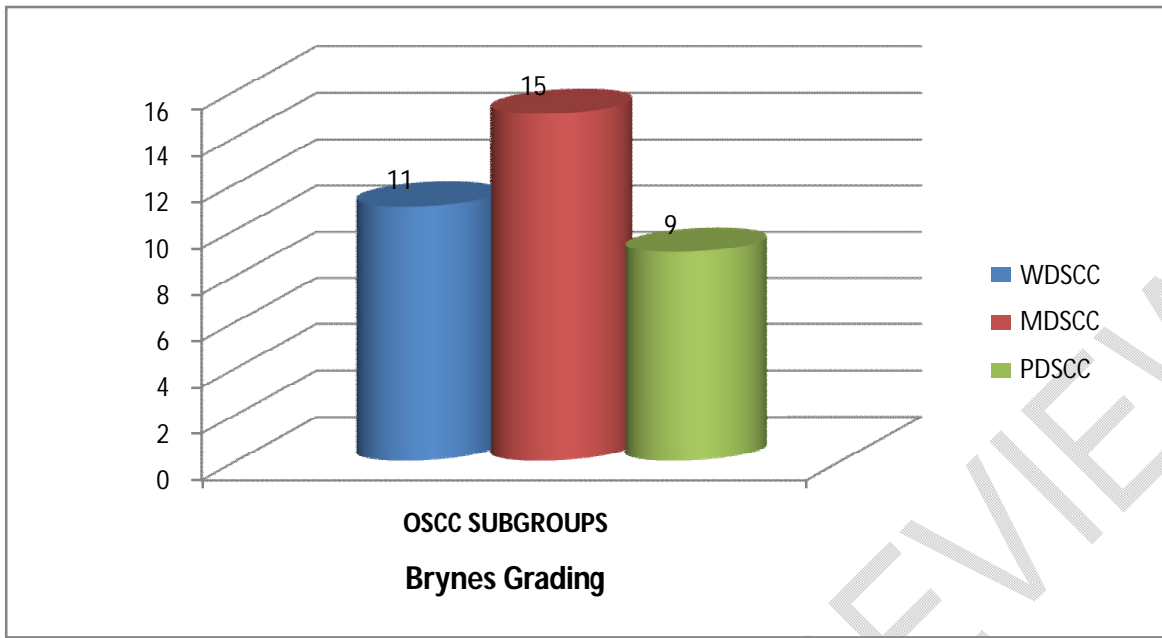
**Graph no.1: Graph representing gender-wise distribution in both the groups**



**Graph no. 2: Graph representing age-wise distribution in both the groups**



**Graph no. 3: Graph representing site-wise distribution in the OSCC group**



Graph no. 4: Graph representing the percentage of positive cells in OSCC subgroups according to Brynes grading

Table no.1: Percentage of positive cells in both the groups

| Percentage positive cells (LAMP3) | Groups [Number (%)] |               | P-value*<br>< 0.001 (HS) |
|-----------------------------------|---------------------|---------------|--------------------------|
|                                   | Normal (n = 0)      | OSCC (n = 30) |                          |
| <b>Total</b>                      | <b>35</b>           | <b>35</b>     |                          |
| Mean ± SD                         | 0                   | 1.6 ± 0.97    |                          |

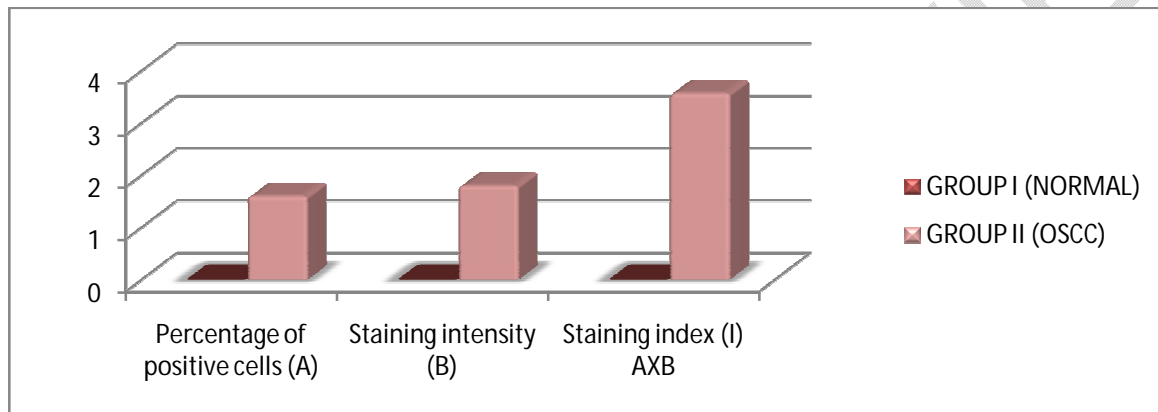
\*\*-Highly significant (p<0.001)

Table 2: Percentage of positive cells in normal and OSCC subgroups

| Percentage positive cells (LAMP3) | Groups [Number (%)] |               |                |               | P-value*<br><0.001 (HS) |
|-----------------------------------|---------------------|---------------|----------------|---------------|-------------------------|
|                                   | Normal (n = 0)      | OSCC (n = 30) |                |               |                         |
|                                   |                     | WDSCC (n = 9) | MDSCC (n = 13) | PDSCC (n = 8) |                         |
| Mean ± SD                         | 0                   | 1.45 ± 1.03   | 1.8 ± 1.08     | 1.44 ± 0.72   |                         |

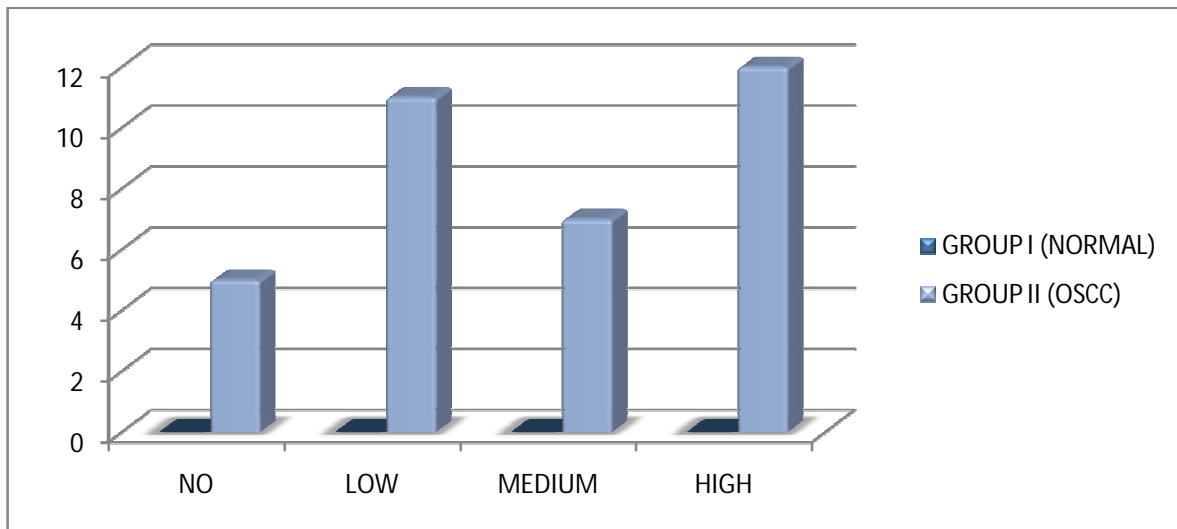
\*\*-Highly significant (p<0.001)

The Staining intensity status of 30 positive OSCC cases showed, 9 (30%) samples to had strong staining i.e high staining intensity followed by 15 (50%) had moderate staining i.e medium staining intensity and 6(20%) had weak staining i.e low staining intensity, 5 samples showed no staining or zero staining intensity with Mean  $\pm$  SD of staining intensity was  $1.8 \pm 0.994$ . As a result, mean staining intensity was much higher in OSCC group (1.8) compared to normal group and with pairwise comparison, it was found to be statistically highly significant with p-value  $<0.001$  as obtained by using One way ANOVA test (Graph 5).



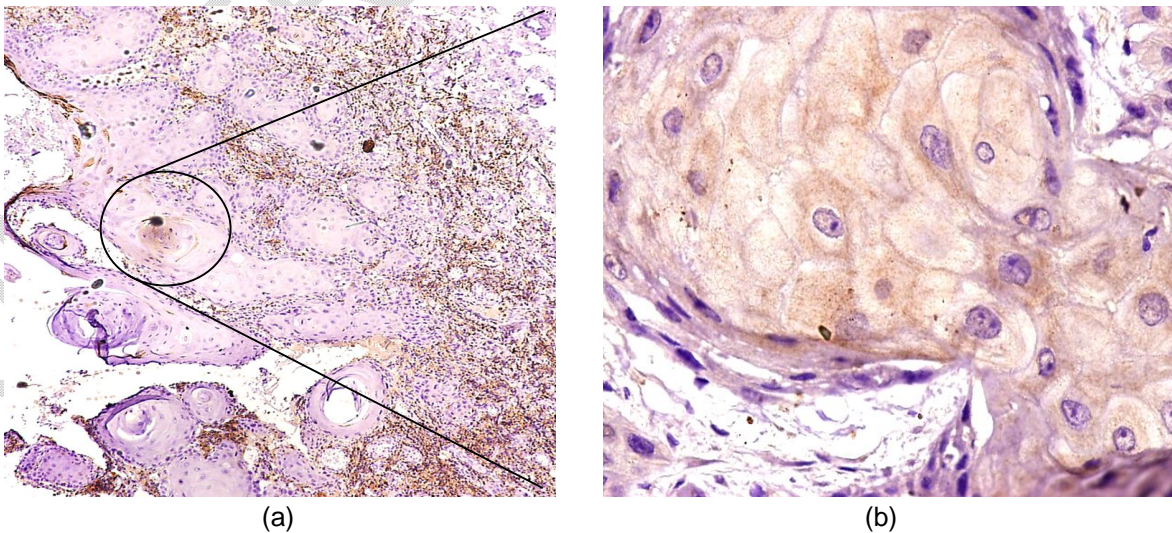
**Graph no. 5: Graph representing intergroup comparison of staining status in both groups**

The staining index status of 30 positive OSCC cases showed, 12(35%) cases had high staining index followed by 7 (20%) had medium staining index and 11(31%) had low staining index. 5(14%) showed zero staining index with Mean  $\pm$  SD of staining index was  $3.57 \pm 2.736$ . The mean staining index was much higher in the OSCC group compared to the normal and with pairwise comparison, it was found to be statistically highly significant with p-value  $<0.001$  as obtained by using One way ANOVA test. The difference between mean staining indices in the two groups was statistically highly significant with a p-value  $< 0.001$  as obtained by a one-way ANOVA test. The pairwise comparison of the mean staining index between the normal group against WDSCC, MDSCC & PDSCC ( $p < 0.001$ ) was also highly significant statistically obtained using one way ANOVA test (Graph 6) but within 3 subgroups of OSCC was statistically non-significant with p-value  $> 0.05$  obtained using chi-square test.

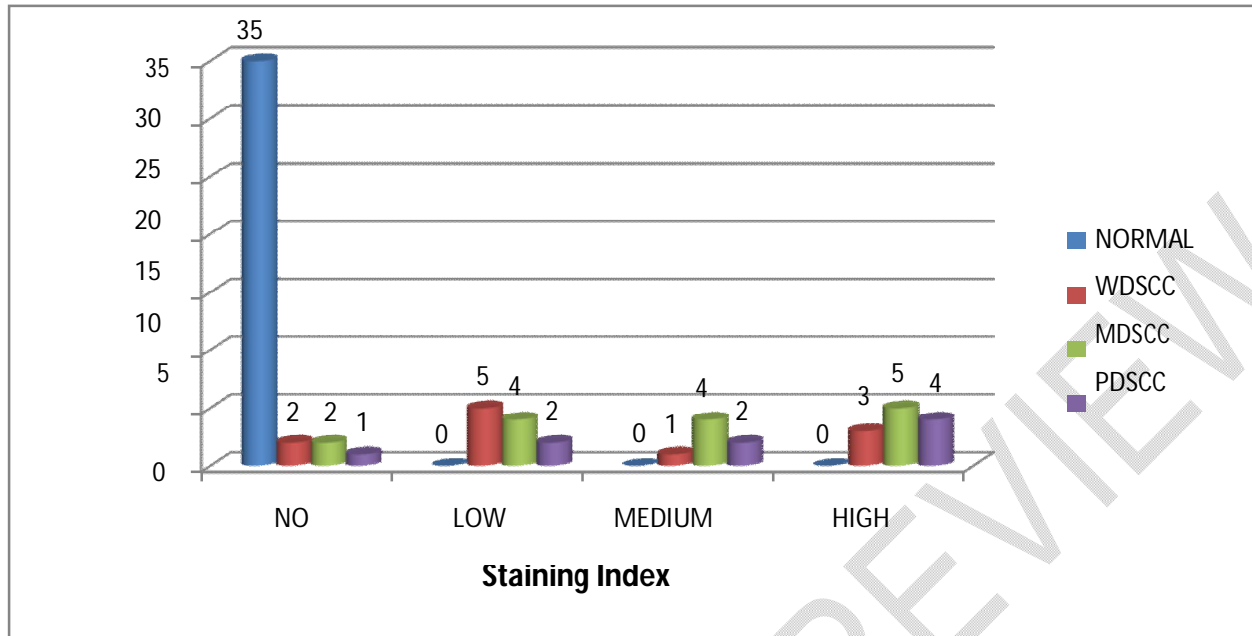


**Graph no. 6: Graph representing staining Index for LAMP3 in both the groups**

“On summarizing all the above observations and results, it could be stated that the LAMP3 protein level was significantly increased in OSCC tissues compared with normal tissues. IHC staining showed that LAMP3 was detectable primarily in the cytoplasm of cancer cells and presented as brown particles (figure 1), consistent with previous studies”.<sup>15</sup> The frequency of high LAMP3 protein expression in the cytoplasm of cancer cells was significantly higher in OSCC tissues than in the normal mucosa ( $P < 0.001$ ) (Graph 7) while no positive signals were found in the normal oral mucosa. We next examined the correlation of LAMP3 expression with the clinical features of patients with OSCC. We found that a high protein level of LAMP3 was significantly linked to the degree of differentiation, node metastasis, and advanced TNM stage, this predicts poor overall survival in OSCC patients



**Figure 1:** The protein expression of LAMP3 in OSCC was determined by IHC analysis in a tissue microarray (a,b) Strong positive cytoplasmic expression of LAMP3 in OSCC Original magnification x 10 (a), Original magnification x 40 (b)



**Graph no. 7: Staining Index (LAMP3) in pairwise comparison of normal group to OSCC subgroups**

#### 4. DISCUSSION

Carcinogenesis is a multi-step process including three main phases: initiation, promotion and progression. "The concept of multistage carcinogenesis was first proposed by Berenblum and Schubik in 1948".<sup>16,17</sup> "The role of lysosomes in homeostasis, cancer biology and macromolecular degradation has been well studied".<sup>18,19</sup> "Throughout cancer progression or cell transformation, lysosomes move to different cellular locations by release of enzymes".<sup>20</sup> LAMPs are a family of glycosylated proteins associated with the lysosome membrane and expressed at different levels in different tissues. An anticancer therapy role for LAMPs has been suggested for five members of this family including LAMP1, LAMP2, LAMP3, CD68/Macrosialin/LAMP4 and BAD-LAMP/LAMP5. It has shown that cancer aggressiveness is increased by lysosomal release of LAMPs".<sup>21, 22</sup>

Saitoh et al. reported "overexpression of LAMP3 in several human cancers such as lung, colon, esophagus, breast, ovary and correlated with node metastasis by affecting cell migration".<sup>23, 24</sup> "These observations indicate that LAMPs might promote the metastasis of malignant tumors. LAMP3 was first identified as a lung-specific gene and located on a chromosome 3q segment".<sup>25</sup> "A role for LAMP3 was characterized in some human cancers including SCC, uterine and cervical cancers".<sup>26</sup> "A previous study found a gain of 3q in 90% of tumor tissue and only 7% in severe dysplasia of invasive cervical carcinoma. In cancers, this could be a suitable candidate gene in previous investigation on altered LAMP3 expression dysplastic and tumor tissues".<sup>27, 28</sup>

This study investigated the expression of LAMP3 protein in grades 1-3 of OSCC and normal tissue. Due to limited studies and the importance of this marker in dysplasia and carcinomas, we compared normal mucosa and OSCC in this study. Our results indicate a role for LAMP3 and its increased expression in the process of oral mucosal carcinogenesis.

LAMP3 expression and patient age were inversely related in the normal group; however, no significant difference in LAMP3 expression was seen between age groups with OSCC. Similar to our result, Jun Lu et al. found “no correlation between LAMP3 expression in OSCC and patient age or gender”.<sup>1, 29</sup> Our results indicate that LAMP3 may be a relevant oncogene candidate potential prognosis factor in OSCC and due to the many similarities, possibly other human cancers as well.

## 5. CONCLUSION

This study determined the potential role of LAMP3 expression in different grades of oral cancer and comparison between the expression of LAMP3 and clinical characteristics of patients with OSCC was performed by using IHC method. In the current study, we found that higher expression of LAMP3 in oral cancer tissues samples than in normal oral tissue samples may be a novel prognostic marker and a potential anticancer target for OSCC patients.

## ETHICAL APPROVAL

The study was approved by the Institutional Ethics Committee Dental College and Hospital, Nagpur, India

## REFERENCES

- 
- <sup>1</sup> Lu J, Ma H, Lian S, Huang D, Lian M, Zhang Y, Huang J, Feng X. Clinical significance and prognostic value of the expression of LAMP3 in oral squamous cell carcinoma. *Disease markers*. 2017;2017.
  - <sup>2</sup> Shahabinejad M, Zare R, Asadi Z, Mohajertehran F. LAMP3 (CD208) Expression in Squamous Cell Carcinoma and Epithelial Dysplasia of the Oral Cavity and Clinicopathological Characteristics of Unfavorable Prognosis. *Reports of Biochemistry & Molecular Biology*. 2021 Jan;9(4):373.
  - <sup>3</sup> Caruntu A, Caruntu C. Recent Advances in Oral Squamous Cell Carcinoma. *Journal of Clinical Medicine*. 2022 Oct 29;11(21):6406.
  - <sup>4</sup> Ford PJ, Rich AM. Tobacco use and oral health. *Addiction*. 2021 Dec;116(12):3531-40.
  - <sup>5</sup> Siegel RL, Miller KD, Fuchs HE, Jemal A. Cancer statistics, 2022. *CA: a cancer journal for clinicians*. 2022 Jan;72(1):7-33.
  - <sup>6</sup> Alabi RO, Youssef O, Pirinen M, Elmusrati M, Mäkitie AA, Leivo I, Almangush A. Machine learning in oral squamous cell carcinoma: Current status, clinical concerns and prospects for future—A systematic review. *Artificial intelligence in medicine*. 2021 May 1;115:102060.
  - <sup>7</sup> Guo K, Xiao W, Chen X, Zhao Z, Lin Y, Chen G. Epidemiological trends of head and neck cancer: a population-based study. *BioMed research international*. 2021 Jul 14;2021:1-4.
  - <sup>8</sup> Coutant F, Pin JJ, Miossec P. Extensive phenotype of human inflammatory monocyte-derived dendritic cells. *Cells*. 2021

---

Jul 2;10(7):1663.

<sup>9</sup> Tang T, Yang ZY, Wang D, Yang XY, Wang J, Li L, Wen Q, Gao L, Bian XW, Yu SC. The role of lysosomes in cancer development and progression. *Cell & bioscience*. 2020 Nov 18;10(1):131.

<sup>10</sup> Zhu J, Long T, Gao L, Zhong Y, Wang P, Wang X, Li Z, Hu Z. RPL21 interacts with LAMP3 to promote colorectal cancer invasion and metastasis by regulating focal adhesion formation. *Cellular & Molecular Biology Letters*. 2023 Dec;28(1):1-21.

<sup>11</sup> Huang F, Ma G, Zhou X, Zhu X, Yu X, Ding F, Cao X, Liu Z. Depletion of LAMP3 enhances PKA-mediated VASP phosphorylation to suppress invasion and metastasis in esophageal squamous cell carcinoma. *Cancer Letters*. 2020 Jun 1;479:100-11.

<sup>12</sup> Etemad-Moghadam S, Khalili M, Tirgary F, Alaeddini M. Evaluation of myofibroblasts in oral epithelial dysplasia and squamous cell carcinoma. *Journal of Oral Pathology & Medicine*. 2009 Sep;38(8):639-43.

<sup>13</sup> L. Han, M. M. Tang, X. Xu et al., "LTBP2 is a prognostic marker in head and neck squamous cell carcinoma," *Oncotarget*, vol. 7, no. 29, pp. 45052–45059, 2016.

<sup>14</sup> Almangush A, Mäkitie AA, Triantafyllou A, de Bree R, Strojjan P, Rinaldo A, Hernandez-Prera JC, Suárez C, Kowalski LP, Ferlito A, Leivo I. Staging and grading of oral squamous cell carcinoma: An update. *Oral oncology*. 2020 Aug 1;107:104799.

<sup>15</sup> I. Treilleux, J. Y. Blay, N. Bendriss-Vermare et al., "Dendritic cell infiltration and prognosis of early-stage breast cancer," *Clinical Cancer Research*, vol. 10, no. 22, pp. 7466–7474, 2004.

<sup>16</sup> Sonnenschein C, Soto AM. Over a century of cancer research: Inconvenient truths and promising leads. *PLoS biology*. 2020 Apr 1;18(4):e3000670.

<sup>17</sup> Hanahan D. Hallmarks of cancer: new dimensions. *Cancer discovery*. 2022 Jan 1;12(1):31-46.

<sup>18</sup> Machado ER, Annunziata I, van de Vlekkert D, Grosveld GC, d'Azzo A. Lysosomes and cancer progression: A malignant liaison. *Frontiers in cell and developmental biology*. 2021 Feb 26;9:642494.

<sup>19</sup> Yim WW, Mizushima N. Lysosome biology in autophagy. *Cell discovery*. 2020 Feb 11;6(1):6.

<sup>20</sup> Yang C, Wang X. Lysosome biogenesis: Regulation and functions. *Journal of Cell Biology*. 2021 May 5;220(6):e202102001.

<sup>21</sup> Alessandrini F, Pezzè L, Ciribilli Y, editors. LAMPs: Shedding light on cancer biology. *Seminars in oncology*; 2017: Elsevier

<sup>22</sup> Burton TD, Fedele AO, Xie J, Sandeman LY, Proud CG. The gene for the lysosomal protein LAMP3 is a direct target of the transcription factor ATF4. *Journal of Biological Chemistry*. 2020 May 22;295(21):7418-30.

<sup>23</sup> Qiu X, Li J, Yang K, Jiang S, Yin Y, Bian L, Huang X, Sun Y, Zhang Z. Down-regulation of LAMP3 inhibits the proliferation and migration of HSCC.

<sup>24</sup> Wang Z, Wang X, Jin R, Liu F, Rao H, Wei L, Chen H, Feng B. LAMP3 expression in the liver is involved in T cell activation and adaptive immune regulation in hepatitis B virus infection. *Frontiers in Immunology*. 2023;14.

<sup>25</sup> Abdelaal G, Veuger S. Reversing oncogenic transformation with iron chelation. *Oncotarget*. 2021 Jan 1;12(2):106.

<sup>26</sup> Kanao H, Enomoto T, Kimura T, Fujita M, Nakashima R, Ueda Y, et al. Overexpression of LAMP3/TSC403/DC -LAMP promotes metastasis in uterine cervical cancer. *Cancer research*. 2005;65(19):8640 -5.

<sup>27</sup> Grade M, Difilippantonio MJ, Camps J. Patterns of chromosomal aberrations in solid tumors. *Chromosomal instability in Cancer cells*: Springer; 2015. p. 115 -42.

<sup>28</sup> Tanaka T, Warner BM, Michael DG, Nakamura H, Odani T, Yin H, Atsumi T, Noguchi M, Chiorini JA. LAMP3 inhibits

---

autophagy and contributes to cell death by lysosomal membrane permeabilization. *Autophagy*. 2022 Jul 3;18(7):1629-47.

<sup>29</sup> Wu H, Li J, Chen J, Yin Y, Da P, Chen Q, Zhang Z, Wang J, Wang G, Qiu X. Efficacy of radiation exposure in laryngeal squamous cell carcinoma is mediated by the LAMP3/LAMC2/tenascin-C pathway. *Experimental Biology and Medicine*. 2019 Oct;244(13):1070-80.

UNDER PEER REVIEW