

Case study

Minocycline-induced diplopia in Philadelphia chromosome-positive acute lymphoblastic leukemia (Ph+ALL): A case report.

Abstract

Background: Minocycline is frequently utilized for multiple drug-resistant (MDR) and extensively drug-resistant bacteria (XDR), but is associated with many side effects. Idiopathic intracranial hypertension is one such effect resulting from the precipitation of raised intracranial pressure (ICP), manifesting as headaches, diplopia or even vision loss. The aim of this report is to present a case of Philadelphia chromosome positive acute lymphoblastic leukemia (Ph+ALL) with XDR *Escherichia coli* (*E. coli*) treated with minocycline. This resulted in elevated ICP with associated symptoms which were initially thought to be due to central nervous system (CNS) involvement by primary disease.

Case presentation: A 14-year-old girl was given minocycline therapy for XDR *E. coli*, which was cultured from her blood, for two weeks. Patient developed complaints of nausea, vomiting, headache, blurring and doubling of vision one week into therapy. Lumbar puncture and brain imaging were performed to rule out CNS involvement with Ph+ ALL, which were reported as negative for malignancy. Minocycline was suspected to have precipitated the event and was discontinued. The patient recovered within one week after cessation of therapy.

Conclusion: Minocycline can be associated with symptomatic elevation of intracranial pressure, which can easily be mistaken for CNS involvement in patients with neoplastic disease, and can reverse upon discontinuation of the drug.

Keywords: *Diplopia, Acute Lymphoblastic Leukemia (ALL), Extensively Drug-Resistant Bacteria, Idiopathic Intracranial Hypertension, Minocycline.*

Introduction

Acute lymphoblastic leukemia (ALL) is the most common types of hematological malignancy found in children.¹The disease may involve the central nervous system (CNS), management of which presents a unique challenge in achieving and maintaining remissions. The mechanism underlying CNS involvement in ALL has, unfortunately, not been clearly ascertained by solid evidence, however, chemotherapeutic agents may have poor penetration through the blood-brain barrier, transforming the CNS into a sanctuary site for leukemic cells.^{2,3}CNS-relapses are more common in Philadelphia chromosome-positive acute lymphoblastic leukemia (Ph+ALL), and these patients have survival rates that are much lower than in patients with Ph+ALL without CNS involvement.^{1,4}

Minocycline is currently used in the treatment of multiple drug- or extensively drug-resistant (MDR or XDR) bacteria in both oncological and non-oncological patients.⁵Use of the drug has been associated with the elevation of intracranial pressure (ICP) leading to idiopathic intracranial hypertension (IIH). The mechanism proposed for this complication is thought to be a reduction in the absorption of cerebrospinal fluid (CSF) at the arachnoid villi. Such rises in ICP are mostly benign and resolve spontaneously after discontinuation of therapy without residual deficiencies, however, a few cases have been reported where vision loss secondary to papilledema was permanent, or where surgical intervention was required.⁶

In this case-report, we present a 14-year-old female with Ph+ALL who underwent induction with R-Hyper CVAD 1A (rituximab, cyclophosphamide, vincristine, adriamycin, and dexamethasone) with dasatinib following which she developed septicemia secondary to an XDR *Escherichia coli* (*E. coli*) infection. A course of minocycline was initiated as management during which she developed headaches, blurring and doubling of vision, which reversed upon discontinuation of minocycline. The aim is to provide meaningful information to clinicians in distinguishing minocycline-induced IIH from a CNS relapse in ALL.

Case presentation

Patient demographics and history

A 14-year-old female patient was admitted under the care of hematology services with a history of fever, menorrhagia, epistaxis, a right-sided abscess of the face, and acute kidney injury. The patient was diagnosed with acute B-cell lymphoblastic leukemia (B-ALL) with

peripheral blood flow cytometry showing 63% blasts, positive for CD45 (weak), CD19, CD10, TdT, CD34, CD20 (33%), CD58, CD38, CD34, surface CD22 and HLA-DR. Fluorescence in-situ hybridization (FISH) for BCR-ABL translocation was positive. She received antibiotic therapy for her abscess followed by R-Hyper CVAD 1A induction with dasatinib and was discharged on completion of chemotherapy due to financial constraints, as per hospital protocols. She was also given intrathecal chemotherapy and her baseline CSF was negative for leukemic cells. She reported to the emergency room (ER) after one week with complaints of fever and vomiting after taking acetaminophen. She was found to be neutropenic, blood cultures were sent, and empiric therapy with meropenem and vancomycin was initiated in the ER, as per institutional protocol. However, she remained febrile for 48 hours; her culture at this point showed a growth of gram-negative rods and vancomycin was discontinued. Since she was still febrile, amikacin was also initiated. The final culture result was received 8 hours later which was reported as showing a growth of XDR *E. coli* which was resistant to meropenem but sensitive to amikacin, gentamicin, minocycline and demonstrated intermediate sensitivity to colistin. Consequently, meropenem was substituted with minocycline, and amikacin was continued. She responded well and became afebrile within 48 hours. Once fit, she was discharged on amikacin and minocycline for two weeks, at which point she was to follow-up as an out-patient.

Clinical Evaluation

She reported to the out-patient department after two weeks with complaints of nausea, vomiting, headache, blurred vision, and diplopia for the past one week. With CNS involvement of Ph+ ALL being a primary differential, she underwent a Magnetic Resonance Imaging (MRI) scan of the brain (Figure 1) as well as CSF microscopy with cytological examination, which were reported as negative for both malignancy and infection. The patient's opening pressure was raised measured at 27 and she was given prophylactic intrathecal chemotherapy. Thus, IIH secondary to minocycline was considered the offending agent and a slit-lamp examination was conducted which showed bilateral papilledema (Figure 2).

Management

Minocycline was held and patient was placed on observation. She reported a complete resolution of symptoms within one week. She underwent R-Hyper CVAD 1B (Rituximab, Methotrexate and Cytarabine) with dasatinib and completed that cycle uneventfully.

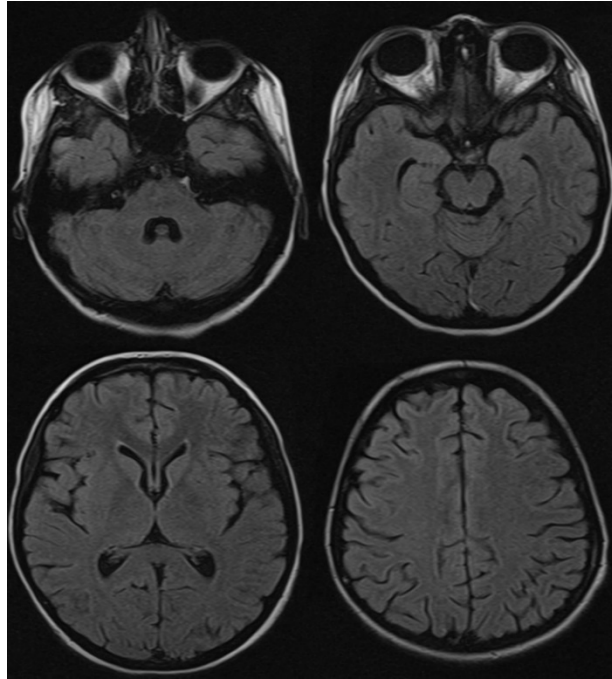


Figure 1: MRI (FLAIR)axial view of our patient’s brain at multiple levels showing no obvious pathology.

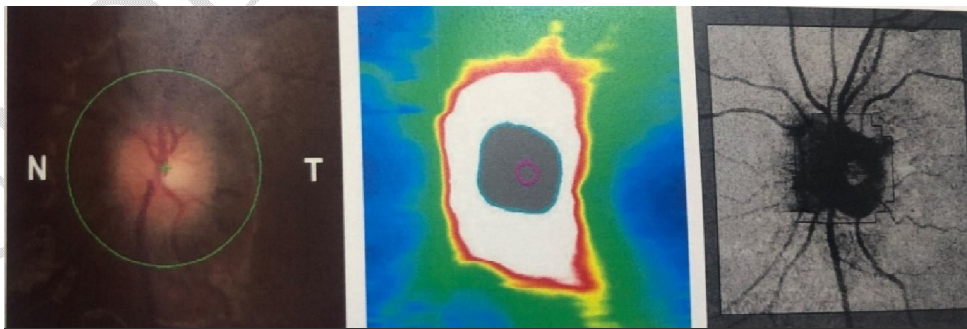


Figure 2: Papilledema seen on Right eye examination.

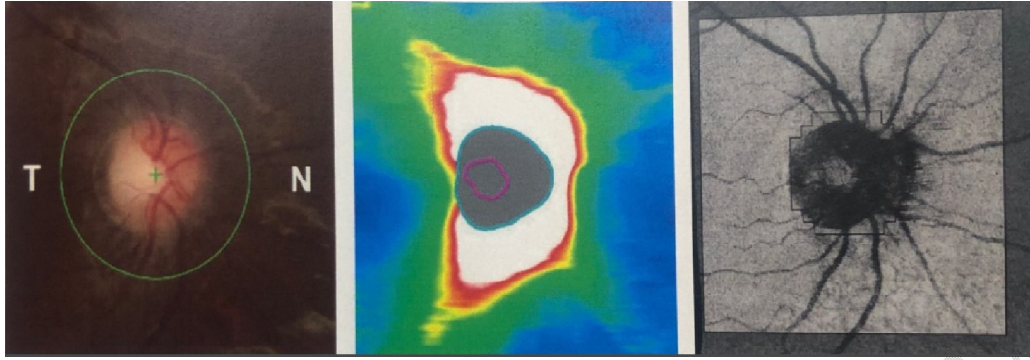


Figure 3: Papilledema seen on Left eye examination.

Discussion

Minocycline, a broad-spectrum antimicrobial, has been shown to be effective against MDR infections with gram-positive and gram-negative bacteria over the past thirty years. As with other tetracyclines, its mechanism of action is based on its ability to bind to the 30S subunit of the bacterial ribosome and prevent protein synthesis.⁷ Minocycline is a semisynthetic tetracycline antibiotic that has a high lipophilicity, giving it good CNS penetration and a half-life of 13-21 hours.⁸ Significant adverse effects include autoimmune disease (e.g., drug-related lupus and serum sickness), pseudotumor cerebri/IIH, pulmonary toxicity and skin hyperpigmentation.⁸

Reports of IIH have been published in literature previously, where minocycline was used for a variety of indications including acne, folliculitis and pelvic inflammatory disease,^{6,9,10} However, our case appears to be the first report of the occurrence of IIH in a patient suffering from acute leukemia, and adequately illustrates the conundrum resulting from the development of elevated ICP while under-treatment with minocycline for an XDR bacterium, with a primary diagnosis of a hematological malignancy: are the CNS manifestations secondary to disease involvement or due to an adverse reaction of the drug? The manner in which our patient presented led to this confusion, CNS involvement of Ph+ ALL being fairly common. The diagnosis was confirmed by keeping a high index of suspicion and performing prompt, relevant investigations with a timely consultation from the ophthalmology service.

Conclusion

This report on the occurrence of drug-induced idiopathic intracranial hypertension in a patient with neoplastic disease serves to caution the clinician in maintaining vigilance when administering minocycline, and in differentiating IIH from the spread of the neoplasm to the CNS. It is pertinent to note here that IIH can be potentially reversible upon prompt discontinuation of minocycline. Vigilant monitoring for development of symptoms suggestive of IIH during minocycline therapy should be encouraged in patients suffering from neoplastic diseases.

Consent

As per international standard or university standard, parental(s) written consent has been collected and preserved by the author(s).

Ethical Approval:

As per international standard or university standard written ethical approval has been collected and preserved by the author(s).

Disclaimer

This paper is an extended version of a preprint document of the same author.

The preprint document is available in this link: <https://www.authorea.com/users/608528/articles/638332-minocycline-induced-diplopia-in-philadelphia-chromosome-positive-acute-lymphoblastic-leukemia-ph-all-a-case-report>

[As per journal policy, preprint article can be published as a journal article, provided it is not published in any other journal]

References

1. Kakaje A, Alhalabi MM, Ghareeb A, Karam B, Mansour B, Zahra B, Hamdan O. Rates and trends of childhood acute lymphoblastic leukaemia: an epidemiology study. *Sci Rep.* 2020 Apr 21;10(1):6756. doi: 10.1038/s41598-020-63528-0.
2. Lenk L, Alsadeq A, Schewe DM. Involvement of the central nervous system in acute lymphoblastic leukemia: opinions on molecular mechanisms and clinical implications based on recent data. *Cancer Metastasis Rev.* 2020 Mar;39(1):173-187. doi: 10.1007/s10555-020-09848-z.

3. Deak D, Gorcea-Andronic N, Sas V, Teodorescu P, Constantinescu C, Iluta S, et al. A narrative review of central nervous system involvement in acute leukemias. *Ann Transl Med.* 2021 Jan;9(1):68. doi: 10.21037/atm-20-3140.
4. Gaur S, Torabi AR, Corral J. Isolated central nervous system relapse in two patients with BCR-ABL-positive acute leukemia while receiving a next-generation tyrosine kinase inhibitor. *In Vivo.* 2014 Nov-Dec;28(6):1149-53.
5. Perdikouri EIA, Arvaniti K, Lathyris D, Apostolidou Kiouti F, Siskou E, et al. Infections Due to Multidrug-Resistant Bacteria in Oncological Patients: Insights from a Five-Year Epidemiological and Clinical Analysis. *Microorganisms.* 2019 Aug 21;7(9):277. doi: 10.3390/microorganisms7090277.
6. Paramo R, Leishangthem L. Optic atrophy secondary to minocycline-induced idiopathic intracranial hypertension. *BMJ Case Rep.* 2023 Mar 28;16(3):e252731. doi: 10.1136/bcr-2022-252731.
7. Arezoo Asadi, Milad Abdi, Ebrahim Kouhsari, Pegah Panahi, Mohammad Sholeh, Nourkhoda Sadeghifard, Taghi Amirani, Alireza Ahmadi, Abbas Maleki, Mehrdad Gholami, Minocycline, focus on mechanisms of resistance, antibacterial activity, and clinical effectiveness: Back to the future, *Journal of Global Antimicrobial Resistance*, Volume 22, 2020, Pages 161-174, ISSN 2213-7165, <https://doi.org/10.1016/j.jgar.2020.01.022>. (<https://www.sciencedirect.com/science/article/pii/S2213716520300230>)
8. Nazarian S, Akhondi H. Minocycline. In: *StatPearls* [Internet]. Treasure Island (FL): StatPearls Publishing; 2023 Jan-. Available from: <https://www.ncbi.nlm.nih.gov/books/NBK554519/>.
9. Ros Forteza FJ, Pereira Marques I. Minocycline-induced intracranial hypertension in a patient with a levonorgestrel intrauterine device. *Neurologia (Engl Ed).* 2019 Oct;34(8):551-553. English, Spanish. doi: 10.1016/j.nrl.2016.11.012.
10. Angelette AL, Rando LL, Wadhwa RD, Barras AA, Delacroix BM, Talbot NC, et al. Tetracycline-, Doxycycline-, Minocycline-Induced Pseudotumor Cerebri and Esophageal Perforation. *Adv Ther.* 2023 Apr;40(4):1366-1378. doi: 10.1007/s12325-023-02435-y.