

THE ROLE OF MAGNETIC RESONANCE IMAGING IN THE DIAGNOSIS OF SPINAL DUMBELL NEUROFIBROMATOSIS: A CASE REPORT FROM A SPECIALIST HOSPITAL IN PORT HARCOURT.

ABSTRACT: Neurofibromatosis occurring in the spine also known as spinal neurofibromatosis (SNF) is a rare disease entity and they occur either unilaterally or bilaterally at the spinal roots. The low prevalence rate of the disease and scarcity of previous literatures is the main aim for this report.

Our case study is a 29-years-old lady who presented to the Radiology department for a lumbosacral spine MRI, on account of both lower limb weakness, paresthesia, unsteady gait and finally inability to walk. The symptoms have been there since she was 14 years (15 years of progressive symptoms). She also presented with multiple macules on the skin (café au lait spots). Magnetic Resonance Imaging (MRI) of the lumbosacral spine revealed bilateral spinal neurofibromas at the spinal roots of the fourth lumbar vertebra to the sacral/coccygeal vertebrae with destruction of the sacro-coccygeal bones. MRI of the brain revealed no abnormalities in the brain and optic tract. The patient fulfilled the National Institutes of Health (NIH) criteria and that of revised diagnostic criteria for Neurofibromatosis (NF1).

The patient also presented with lack of pain which could be due to impairment in sensory neurons. We describe a case of spinal neurofibromatosis diagnosed by MRI in a young lady with progressive lower limb weakness, paresthesia, sensory loss, café-au- lait spots and paraplegia.

Keywords: Spinal neurofibromatosis (SNF), Magnetic Resonance Imaging, Café-au-lait spots.

INTRODUCTION: Neurofibromatosis shows an autosomal dominant inheritance pattern and is a group of genetic neurocutaneous disorders with significant morbidity and mortality. These conditions are characterized by abnormal cell growth in the nerves throughout the body at any age^{1,2}. Despite the significant differences in clinical appearance of the affected individuals, numerous reports of variant forms of the disease^{2,3}, the NF are generally classified into three entities, NF type 1, (NF1 96% of all cases) and NF2, which are well categorized based on genetic defects in the relevant genes, tumor type and their locations, and clinical determinants of each type. A third but very rare variety called Schwannomatosis (<1% of all NF cases) also exist. The latter is as a result of distinct mutations in SMARCB1 or LZTR1 genes however, this shares a clinical appearance similar to NF2, apart from bilateral vestibular schwannomas and an older age of onset⁴⁻⁸.

NF1 well-known as Von Recklinghausen's disease, affects all races and ethnicities with a documented prevalence of 1 in 3,000 - 1 in 6,000 and a projected birth rate of 1/2,558-1/3,333. There are speculations that this could be as a result of mutations on NF1 gene localized on chromosome 17^{6,9}.

Even though autosomal dominant pattern of inheritance in both NF types suggest vertical transmission as the key source of genetic mutation, about half of the NF1 cases are representation of denovo mutations in NF2 sequence¹⁰. Neurofibromin a gene product of NF1, is a GTPase- activating protein that acts as a negative regulator of RAS/MAPK pathway¹¹. Therefore transmutations in NF1 gene is linked with reduced tumor suppressive features, RAS hyperactivation and ensuing upregulation of MTOR and ERK pathways⁶, which have been related to increased predispositions to certain tumors and /or malignancies including

astrocytomas, optic pathway glioma, GIT stromal tumors, breast cancer, rhabdomyosarcoma, pheochromocytoma and peripheral nerve sheath tumors^{12,13}. Genetic counseling should be given to families of patients with NF1, especially to their first degree relatives if they so desire, this could help in the better understanding by relatives and foster proper and selfless care to the patients by their families¹⁴.

Phenotypically the disease is characterized by multiple skin pigmentations (café-au-lait macules and lentiginous macules), melanocytic hamartomas of the iris (Lisch nodules), cutaneous, subcutaneous, internal and or plexiform neurofibromas, intellectual disability, skeletal dysplasia, short stature and optic gliomas. Dermal and peripheral neurofibromas comprise the majority of benign tumors in classical NF1¹⁵ while the occurrence of spinal neurofibromas is more restricted to 36% of patients with classical disease and in 5% of patients with spinal complications.

Studies describing SNF have been relatively few and as such an additional report describing this disease makes for a better understanding of this rare disease entity.

AIM/OBJECTIVE-To report the existence of this rare disease entity in our environment as well as further consolidate on the already existing knowledge of the invaluable use of MRI in the detection and diagnosis of spinal lesions, especially as MRI is the best imaging modality in the assessment of the spine/spinal roots and nerves due to its excellent soft tissue contrast.

CASE REPORT: Our case study is a 29-years-old lady presenting with progressive lower limb weakness, unsteady gait, impaired sensation and paraplegia. On inspection, the patient had multiple café-au-lait macules. No obvious dermal neurofibroma seen. The patient gave a history

of similar skin lesions seen on her body (café-au-lait spots) been present on her mother and maternal uncle's body respectively indicating a possible maternal origin of NF gene mutation.

Further history from the patient, shows that she had no learning difficulties as she is a higher national diploma holder. The patient started experiencing both lower limb weaknesses which started with the left side initially before extending to the right. She also had low back pain and paresthesia all these started at the age of 14 years (15 years ago). The patient and her relatives got alarmed when she could no longer walk (paraplegia) and that necessitated their seeking medical help.

On physical examination she had marked sensory and motor neuron impairment of the lower limbs.

MRI of the spine revealed the presence of slightly hyperintense to muscle soft tissue masses extending from L4 to the sacral/coccygeal vertebrae (Fig1).

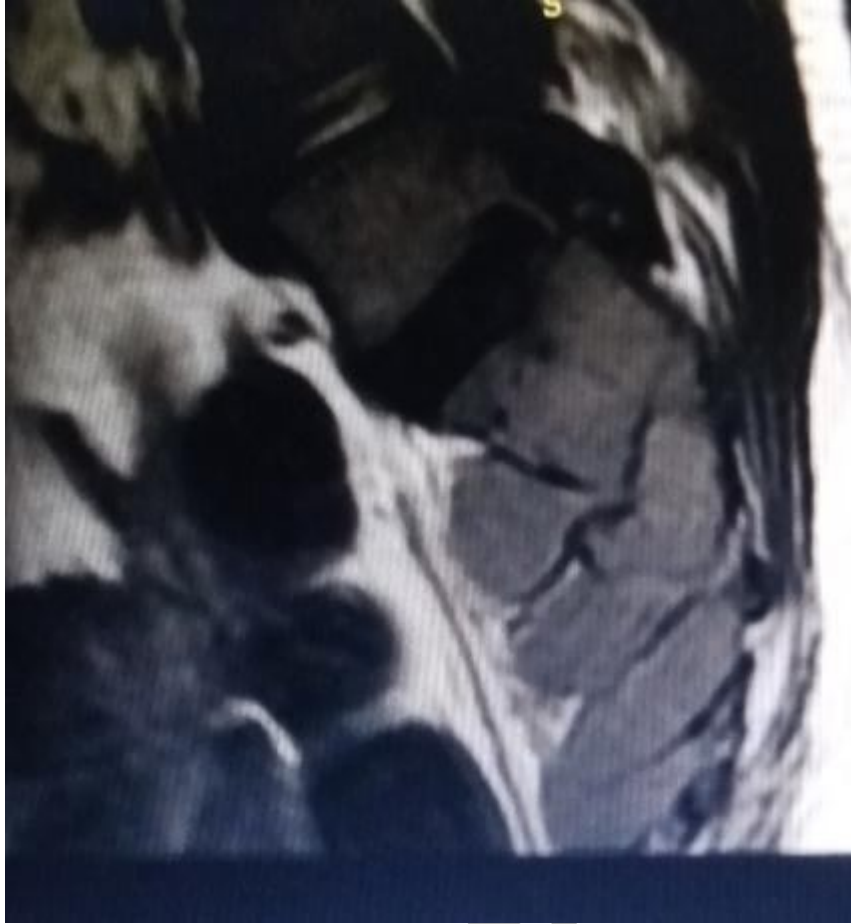

Fig 1 is a sagittal T1W sequence image of the lower lumbar to sacrococcygeal region of the spine with the lesions seen overlying it with dumb bell like shape that is slightly hyperintense to muscle.

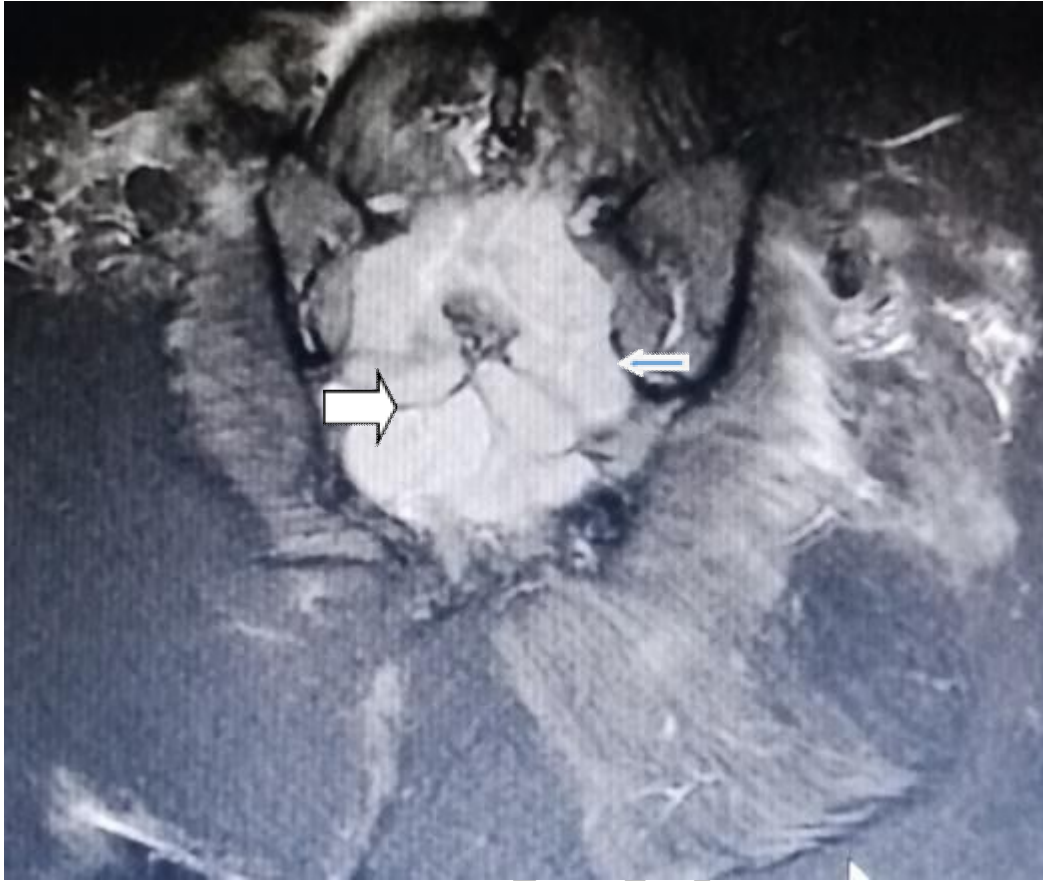


Fig 2 is a coronal STIR sequence image of the sacrococcygeal region showing the bilaterality of the dumb-bell shaped lesion (white arrow for right and slim arrow for left sides respectively), which is hyperintense to muscle.

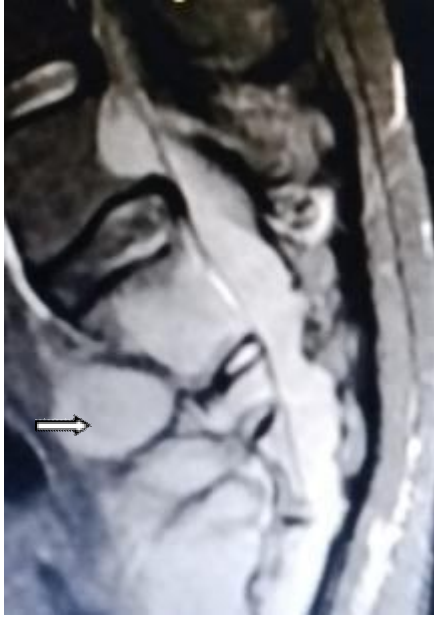

Fig 3 is a sagittal STIR sequence image showing the lesions is originating from L4 vertebral body and terminates at the coccyx and is hyperintense (arrow).

DISCUSSION: Neurofibromatosis of the spine, (SNF) could be described as a disease entity in which bilateral neurofibromas in spinal nerves and or in spinal roots are the central clinical presentation of the patients. However the classical symptoms and signs of NF1 (change in muscle tone, skeletal dysplasia etc) occur less frequently in these patients. Consequently only a minority of SNF cases satisfy completely the NF1 diagnostic criteria¹⁶. Skin fibromas are more common with NF1 than with SNF, despite extensive involvement of enlarged nerves involving the spinal nerves and roots.

Spinal Neurofibromatosis, was initially thought to be only hereditary/familial but it has been reported that genetic mutations in NF1 have been observed significantly in patients with SNF. Hence, individuals harbouring denovo genetic mutation of NF1, may develop SNF even when there is no family history of the disease.

Ahlawat S et al¹⁷ in their study described obtaining baseline MRI of the CNS to screen for asymptomatic tumors in newly diagnosed and asymptomatic individuals with NF1 as unnecessary. They further said imaging studies should be for individuals demonstrating abnormal neurologic examination, prolonged symptoms of cord compression and polyneuropathy.

While classical NF1 symptoms is less seen in SNF, this case presented with café-au-lait spots, movement disorder(paraplegia) this could probably mean that our index case is amongst the few cases of SNF, presenting with classical NF1 features. It is of note to say symptomatic SNF reportedly consists only 1.6% of all cases of NF1 cases¹⁶.

Management of spinal neurofibromatosis is multidisciplinary involving the Neurosurgeon, Neurologist, Neuroradiologist, Physiotherapist and Geneticist. Due to the severity of the symptoms, patient was counseled for surgical intervention that is multilevel lumbar Laminectomy/Foraminotomy with near –total resection of the tumour in order to preserve the nerve function.

Patient was lost to follow up due to financial constraints and poor communication as patients phone number is not reachable.

CONCLUSION: Sacrococcygeal region of the spine is an uncommon site for neurofibromatosis. Magnetic resonance imaging of the spine (MRI) is a must do for most patients presenting with lower limb weakness irrespective of their age. In view of the above we recommend that the health sector should provide an up to date Radiology department in our tertiary hospitals.

Consent

As per international standard or university standard, patient(s) written consent has been collected and preserved by the author(s).

Ethical Approval:

As per international standard or university standard written ethical approval has been collected and preserved by the author(s).

REFERENCES

- 1-Riccardi VM. Neurofibromatosis: phenotype natural history and pathogenesis. *Plastic Reconst Surg.* (1993) 91: 561.DOI: 10. 1097/00006534-199303000-00029. CrossRef Full Text I Google Scholar
- 2-Stumpf DA, Alksne JF, Annegers JF, Brown SS, Conneally PM, Housman D. Neurofibromatosis: Conference statement. *Arch Neurol.* (1998) 45: 575-8. DOI: 10. 1001/archneur. 1998. 00520290115023. PubMed Abstract I CrossRef Full Text I Google Scholar.
- 3- Viskochil D. Alternate and related forms of the neurofibromatosis. *Neurofibromin Pathog Clin Overview.* (1994) 1994: 4m45-74. Google Scholar.
- 4- Ars E, Kruyer H, Gaona A, Casquero P, Rosell J, Volpini V, et al. A clinical variant of neurofibromatosis type 1: familial spinal neurofibromatosis with a frameshift mutation in the NF1 gene. *Am J Human Genet.* (1998) 62: 834-41. DOI: 10. 1086/301803 PubMed Abstract I CrossRef Full Text I Google Scholar
- 5- Seppala MT, Sainio MA, Haltia MJJ, Kinunnen JJ, Setala KH, Jaaskelainen JE. Multiple schwannomas: Schwannomatosis or neurofibromatosis type 2? *J Neurosurg.* (1998) 89 : 36-41.DOI: 10.3171/jns. 1998. 89.1 0036. PubMed Abstract I CrossRef Full Text I Google Scholar.

6- Tamura R. Current understanding of neurofibromatosis type 1, 2, and schwannomatosis. *Int J Mol Sci.* (2021) 22:5850. DOI: 10.3390/ijms22115850. PubMed Abstract | CrossRef Full Text | Google Scholar.

7-Smith MJ, Bowers NL, Bulman M, Golkhale C, Wallace AJ, King AT, et al. Revisiting neurofibromatosis type 2 diagnostic criteria to exclude LZTR1 – related schwannomatosis. *Neurology.* (2017) 88: 87-92. DOI: 10.1212/WNL.0000000000003418. PubMed Abstract | CrossRef Full Text | Google Scholar

8- Kresak JL, Walsh M. Neurofibromatosis: a review of NF1, NF2 and schwannomatosis. *J Pediatr Genet.* (2016). 05: 098-104. DOI: 10.1055/s-0036-1579766 PubMed Abstract | CrossRef Full Text | Google Scholar

9- Ning Z, Yang Z, Chen G, Wu W, He L, Sun Y, et al. Spinal neurofibromatosis with NF1 mutation in a classic neurofibromatosis type 1 family: a case report and literature review. *Mol Genet Genomic Med.* (2020) 8: e1035. DOI: 10.1002/mgg3.1035 PubMed Abstract | CrossRef Full Text | Google Scholar

10- Trovo-Marqui AB, Tajara EH. Neurofibromin a general outlook. *Clin Genet* (2006) 70: 1-13. DOI: 10.1111/j.1399-0004.2006.00639.x PubMed Abstract | CrossRef Full Text | Google Scholar.

11- LI F, Munchhof AM, White HA, Mead LE, Krier TR, Fenoglio A, et al. Neurofibromin is a novel regulator of RAS – induced signals in primary vascular smooth muscle cells. *Human Mol Genet.* (2006) 15: 1921-30. DOI: 10.1093/hmg/ddl114 PubMed Abstract | CrossRef Full Text | Google Scholar

- 12- Legius E, Messiaen L, Wolkenstein P, Pancza P, Avery RA, Berman Y, et al. Revised diagnostic criteria for neurofibromatosis type 1 and Legius syndrome: an international consensus recommendation. *Genet Med.* (2021) 23: 1506-13. DOI: 10.1038/s41436-021-01170-5 PubMed Abstract I CrossRef Full Text I Google Scholar
- 13- Ahlawat S, Eley JO, Langmead S, Belzberg AJ, Fayad LM. Current status and recommendations for imaging in neurofibromatosis type 1, neurofibromatosis type 2 and schwannomatosis. *Skeletal Radiol.* (2020) 49:199-219. DOI: 10.1007/s00256-019-03290-1 PubMed Abstract I CrossRef Full Text I Google Scholar
- 14- Begqvist C, Servy A, Valeyrie-Allanore L, Ferkal S, Combemale P, Wolkenstein P, et al. Neurofibromatosis 1 french national guidelines based on an extensive literature review since 1966. *Orphanet J Rare Dis.* (2020) 15: 37. DOI: 10.1186/s13023-020-1310-3 PubMed Abstract I CrossRef Full Text I Google Scholar
- 15- Kallionpää RA, Uusitalo E, Leppavirta J, Poyhonen M, Peltonen S, Peltonen J. Prevalence of neurofibromatosis type 1 in the Finnish population. *Genet Med.* (20038/gim8) 20: 1082-6. DOI: 10.1038/gim.2017.215 PubMed Abstract I CrossRef Full Text I Google Scholar
- 16- Ruggieri M, Polizzi A, Spalice A, Salpietro V, Caltabiano R, D'Orazi V, et al. The natural history of spinal neurofibromatosis: a critical review of clinical and genetic features. *Clin Genet* (2015) 87: 401-10. DOI: 10.1111/cge.12498 PubMed Abstract I CrossRef Full Text I Google Scholar
- 17- Korf BR. Spinal neurofibromatosis and phenotypic heterogeneity in NF1. *Clin Genet* (2015) 87: 399-400. DOI: 10.1111/cge.12532 PubMed Abstract I CrossRef Full Text I Google Scholar

UNDER PEER REVIEW