

Case report

THE ROLE OF MAGNETIC RESONANCE IMAGING IN THE DIAGNOSIS OF SPINAL DUMBELL NEUROFIBROMATOSIS. A CASE REPORT FROM A SPECIALIST HOSPITAL IN PORT HARCOURT.

ABSTRACT: Spinal neurofibromatosis (SNF) is a rare form of neurofibromatosis in which neurofibromas exist bilaterally at the spinal roots. The low incidence rate of the disease and scarcity of previous reports calls for further studies and reports to elaborate this disease entity.

Our case study is a 29-year-old lady who presented to the Radiology department for a lumbosacral spine MRI, on account of both lower limb weakness, paresthesia, unsteady gait and finally inability to walk. The symptoms have been there since she was 14 years (15 years of progressive symptoms). She also presented with multiple café-au-lait macules on the skin. Magnetic Resonance Imaging (MRI) of the lumbosacral spine revealed bilateral spinal neurofibromas at the spinal roots of the fourth lumbar vertebra to the sacral/coccygeal vertebrae with destruction of the sacro-coccygeal bones. The patient fulfilled the **NH** criteria as well as the revised criteria for Neurofibromatosis 1 (NF1).

The patient also presented with lack of pain which could be due to impairment in sensory neurons. We describe a case of spinal neurofibromatosis diagnosed by MRI in a young lady with progressive lower limb weakness, paresthesia, sensory loss, café-au-lait spots and paraplegia.

Keywords: Spinal neurofibromatosis (SNF), Magnetic Resonance Imaging, Café-au-lait spots, **Specialist Hospital, Port Harcourt.**

INTRODUCTION: The neurofibromatosis is a group of genetic neurocutaneous disorders with an autosomal dominant inheritance pattern and significant morbidity and mortality. These conditions are characterized by deregulated cell growth in the nerves throughout the body at any age^{1,2}. Despite the significant heterogeneity in clinical presentation of the affected individuals, several reports of variants forms of the of the disease^{2,3}, the NF have been generally classified into three entities, NF type 1, (NF1 96% of all cases) and NF2, which are well characterized based on genetic defects in the relevant genes, tumor type and their locations, and clinical determinants of each type. A third but very rare variety called Schwannomatosis (<1% of all NF cases) also exist. The latter is as a result of distinct mutations in SMARCB1 or LZTR1 genes however, this shares a clinical presentation comparable to NF2, excluding bilateral vestibular schwannomas and an older age of onset⁴⁻⁸.

NF1 commonly known as Von Recklinghausen's disease, affects all races and ethnicities with a reported incidence of 1 in 3,000- 1 in 6,000 and an estimated birth incidence of 1/2,558-1/3,333, is caused by mutations in NF1 gene localized to chromosome 17^{6,9}.

Although autosomal dominant pattern of inheritance in both NF types suggest vertical transmission as the primary source of genetic mutation, about half of the NF1 cases are representation of denovo mutations in NF2 sequence¹⁰. The gene product of NF1, neurofibromin, is a GTPase- activating protein that acts as a negative regulator of RAS/MAPK pathway¹¹. Therefore mutations in NF1 gene result in diminished tumor suppressive properties, RAS hyperactivation and subsequent upregulation of MTOR and ERK pathways⁶, which have been linked to increased predispositions to certain tumors and /or malignancies including astrocytomas, optic pathway glioma, GIT stromal tumors, breast cancer, rhabdomyosarcoma, phaeochromocytoma and peripheral nerve sheath tumors^{12,13}. Genetic counselling should be

offered to families of patients with NF1, especially to their first degree relatives if they so desire, this could help in the better understanding by relatives and foster proper and selfless care to the patients by their families¹⁴.

The disease phenotype is characterized by multiple skin pigmentations (café-au-lait macules and lentiginous macules), melanocytic hamartomas of the iris (Lisch nodules), cutaneous, subcutaneous, internal and or plexiform neurofibromas, intellectual disability, skeletal dysplasia, short stature and optic gliomas. Dermal and peripheral neurofibromas comprise the majority of benign tumors in classical NF1¹⁵ while the occurrence of spinal neurofibromas is more restricted to 36% of patients with classical disease and in 5% of patients with spinal complications.

Studies describing SNF have been relatively few and as such additional reports describing this distinct disease would allow a better understanding of this rare clinical entity.

AIM/OBJECTIVE-To report the existence of this rare clinical entity in our environment as well as further consolidate on the already existing knowledge of the invaluable use of MRI in the detection and diagnosis of spinal lesions, especially as MRI is the best imaging modality in the assessment of the spine/spinal roots and nerves due to its excellent soft tissue contrast.

In this study we describe a patient with SNF, presenting with involvement of the L2-S4 vertebrae spinal roots, neurocutaneous symptoms, lower limb weakness and paraplegia.

CASE REPORT:The patient described is a 29year-old lady presenting with progressive lower limb weakness, unsteady gait, impaired sensation and paraplegia. Upon inspection, the patient had multiple café-au-lait macules. No obvious dermal neurofibroma seen. She reported a history

of café-au-lait spots on her mother and maternal uncle indicating a maternal origin of NF gene mutation.

According to the patient she did not experience learning difficulties as she is a higher national diploma holder. The patient started experiencing both lower limb weaknesses which started with the left side initially before extending to the right. She also had low back pain and paresthesia all these started at the age of 14years (15years ago). The patient and her relatives got alarmed when she could no longer walk (paraplegia) and that necessitated their seeking medical help.

On physical examination she had marked sensory and motor neuron impairment of the lower limbs.

MRI of the spine revealed the presence of slightly hyperintense to muscle soft tissue masses extending from L4 to the sacral/coccygeal vertebrae (Fig1). .

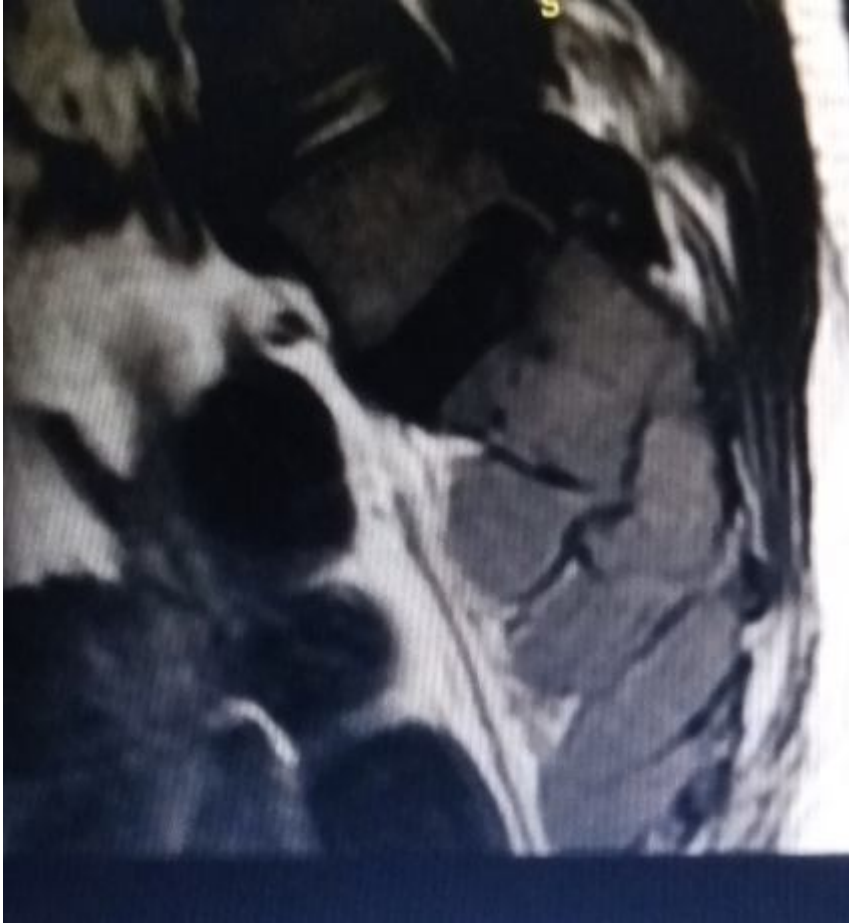

Fig 1 is a sagittal T1W sequence image of the lower lumbar to sacrococcygeal region of the spine with the lesions seen overlying it with dumb bell like shape that is slightly hyperintense to muscle.

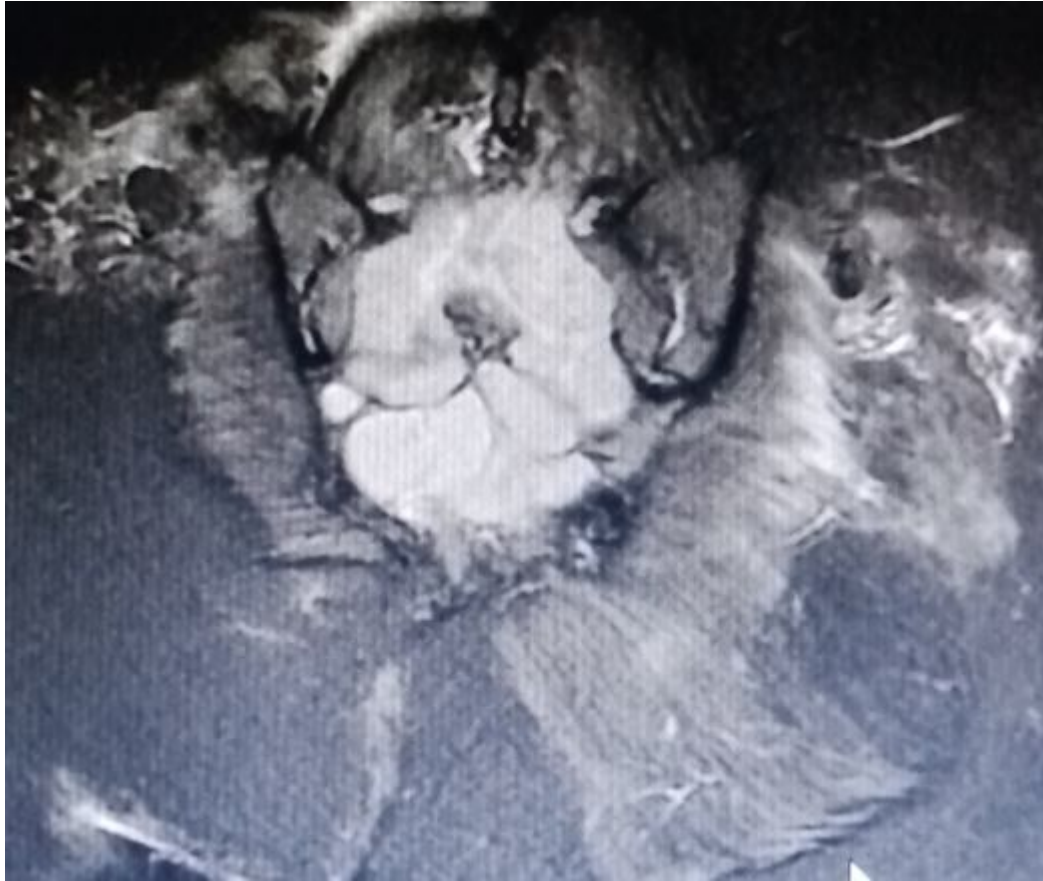


Fig 2 is a coronal STIR sequence image of the sacrococcygeal region showing the bilaterality of the dumb-bell shaped lesion, which is hyperintense to muscle.

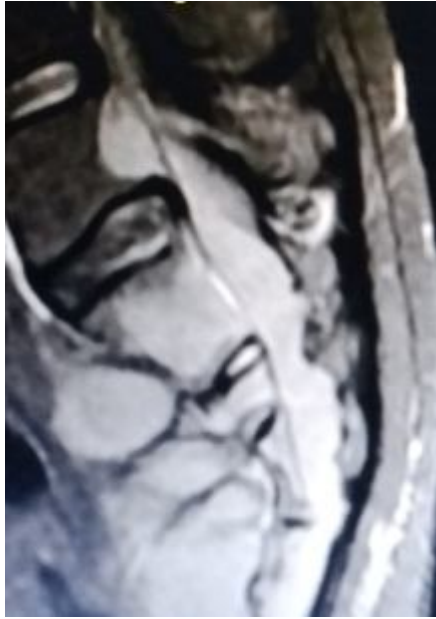

Fig 3 is a sagittal STIR sequence image showing the lesions is originating from L4 vertebral body and terminates at the coccyx and is hyperintense.

DISCUSSION:Spinal neurofibromatosis (SNF) could be described as a clinical entity in which bilateral neurofibromas in spinal nerves and or spinal roots are the main clinical presentation of the patients however they present with less frequent manifestations of other NF1 features likechange in muscle tone, skeletal dysplasia etc. Infact only a minority of SNF cases satisfy completely the NF1 diagnostic criteria¹⁶. Dermal fibromas are more common in NF1 than in SNF, despite extensive involvement of enlarged peripheral nerves involving the spinal nerves and roots.

SNF, was initially referred to as hereditary/familial spinal neurofibromatosis but it has been observed that genetic mutations in NF1 have been observed significantly in patients with SNF. Consequently, individuals habouringdenovo genetic mutation of NFI, may develop SNF even when there is no family history of the disease.

According to Ahlawat S et al¹⁷ obtaining baseline MRI of the CNS to screen for asymptomatic tumors in newly diagnosed and asymptomatic individuals with NF1 is not currently recommended. Imaging studies they said should be for individuals demonstrating abnormal neurologic examination, prolonged symptoms of cord compression and polyneuropathy.

While classical NF1 symptoms is less seen in SNF, this case presented with café-au-lait spots, movement disorder(paraplegia). It is of note to say symptomatic SNF reportedly consists only 1.6% of all cases of NF1 cases¹⁶.

CONCLUSION: Sacrococcygeal region of the spine is an uncommon site for neurofibromatosis. Magnetic resonance imaging of the spine (MRI) is a must do for most patients presenting with lower limb weakness irrespective of their age. In view of the above we recommend that the health sector should provide an up to date Radiology department in our tertiary hospital.

CONSENT: Verbal/written consent was obtained.

REFERENCES

- 1-Riccardi VM. Neurofibromatosis: phenotype natural history and pathogenesis. *Plastic Reconst Surg.* (1993) 91: 561.DOI: 10. 1097/00006534-199303000-00029. CrossRef Full Text I Google Scholar
- 2-Stumpf DA, Alksne JF, Annegers JF, Brown SS, Conneally PM, Housman D. Neurofibromatosis: Conference statement. *Arch Neurol.* (1998) 45: 575-8. DOI: 10. 1001/archneur. 1998. 00520290115023. PubMed Abstract I CrossRef Full Text I Google Scholar.

- 3- Viskochil D. Alternate and related forms of the neurofibromatosis. Neurofibromin Pathog Clin Overview. (1994) 1994: 4m45-74. Google Scholar.
- 4- Ars E, Kruyer H, Gaona A, Casquero P, Rosell J, Volpini V, et al. A clinical variant of neurofibromatosis type 1: familial spinal neurofibromatosis with a frameshift mutation in the NF1 gene. Am J Human Genet. (1998) 62: 834-41. DOI: 10. 1086/301803 PubMed Abstract I CrossRefFull Text I Google Scholar
- 5- Seppala MT, Sainio MA, Haltia MJJ, Kinunnen JJ, Setala KH, Jaaskelainen JE. Multiple schwannomas: Schwannomatosis or neurofibromatosis type 2? J Neurosurg. (1998) 89 : 36-41.DOI: 10.3171/jns. 1998. 89.1 0036. PubMed Abstract I CrossRef Full Text I Google Scholar.
- 6- Tamura R. Current understanding of neurofibromatosis type 1, 2, and schwannomatosis. Int J Mol Sci. (2021) 22:5850. DOI: 10. 3390/ijms22115850.Pubmed Abstract I CrossRef Full Text I Google Scholar.
- 7-Smith MJ, Bowers NL, Bulman M, Golkhale C, Wallace AJ, King AT, et al. Revisiting neurofibromatosis type 2 diagnostic criteria to exclude LZTR1 – related schwannomatosis. Neurology. (2017) 88: 87-92. DOI: 10.1212/WNL. 0000000000003418. PubMed Abstract I CrossRef Full Text I Google Scholar
- 8- Kresak JL, Walsh M. Neurofibromatosis: a review of NF1, NF2 and schwannomatosis. J Pediatr Genet. (2016). 05: 098-104.DOI: 10.1055/s-0036-1579766 PubMed Abstract I CrossRef Full TextI I Google Scholar
- 9- Ning Z, Yang Z, Chen G, Wu W, He L, Sun Y, et al. Spinal neurofibromatosis with NF1 mutation in a classic neurofibromatosis type 1 family: a case report and literature review. Mol

Genet Genomic Med. (2020) 8: e1035. DOI: 10. 1002/mgg3 1035 PubMed Abstract I CrossRef Full Text I Google Scholar

10- Trovo-Marqui AB, Tajara EH. Neurofibromin a general outlook. Clin Genet (2006) 70: 1-13. DOI: 10. 1111/j. 1399-0004 2006.00639. x PubMed Abstract I CrossRef Full Text I Google Scholar.

11- LI F, Munchhof AM, White HA, Mead LE, Krier TR, Fenoglio A, et al. Neurofibromin is a novel regulator of RAS – induced signals in primary vascular smooth muscle cells. Human Mol Genet. (2006) 15: 1921-30. DOI: 10. 1093/hmg/ddI114 PubMed Abstract I CrossRef Full Text I Google Scholar

12- Legius E, Messiaen L, Wolkenstein P, Pancza P, Avery RA, Berman Y, et al. Revised diagnostic criteria for neurofibromatosis tyoe 1 and Legius syndrome: an international consensus recommendation. Genet Med. (2021) 23: 1506-13. DOI: 10. 1038/s41436-021-01170-5 PubMed Abstract I CrossRef Full Text I Google Scholar

13- Ahlawat S, eley JO, Langmead S, Belzberg AJ, Fayad LM. Current status and recommendations for imaging in neurofibromatosis type 1, neurofibromatosis type 2 and schwannomatosis. Skeletal Radiol. (2020) 49:199-219. DOI: 10. 1007/ s00256-019-03290-1 PubMed Abstract I CrossRef Full Text I Google Scholar

14- Begqvist C, Servy A, Valeyrie- Allanore L, Ferkal S, Combemale P, Wolkenstein literature P, et al. Neurofibromatosis 1 french national guidelines based on an extensive literature review since 1966. Orphanet J Rare Dis. (2020) 15: 37. DOI: 10. 1186/s13023-020-1310-3 PubMed Abstract I CrossRef Full Text I Google Scholar

15- Kallionpaa RA, Uusitalo E, Leppavirta J, Poyhonen M, Peltonen S, Peltonen J. Prevalence of neurofibromatosis type 1 in the Finnish population. *Genet Med.* (20038/gim8) 20: 1082-6.DOI:

10. 1038/gim.2017.215 PubMed Abstract | CrossRef Full Text | Google Scholar

16- Ruggieri M, Polizzi A, Spalice A, Salpietro V, Caltabiano R, D' Orazi V, et al. The natural history of spinal neurofibromatosis: a critical review of clinical and genetic features. *Clin Genet*

(2015) 87: 401-10. DOI:10, 1111/cge. 12498 PubMed Abstract | CrossRef Full Text | Google Scholar

17- Korf BR. Spinal neurofibromatosis and phenotypic heterogeneity in NF1. *Clin Genet* (2015)

87: 399-400. DOI: 10, 1111/cge 12532 PubMed Abstract | CrossRef Full Text | Google Scholar