

Case study

Stable Atrial Flutter in a Cocaine User: A Case Report and Literature Review

ABSTRACT

Cocaine is one of the commonest illicit drugs used and one of the most frequent causes of drug related deaths. Cardiovascular system effects due to cocaine manifests as a variety of structural heart issues along with arrhythmias. Atrial flutter is a common cause of morbidity in the United States population. Even though research has been sparse on the topic of cocaine use and atrial flutter, they have been shown to be linked. We present here a unique case of stable chronic atrial flutter in a middle-aged woman with a history of chronic cocaine use and heart failure with an ejection fraction of 15-20%.

Keywords: Atrial flutter, Cocaine, Heart Failure, Heart Failure With Reduced Ejection Fraction, Stable Atrial Flutter, Cardiology.

1. INTRODUCTION

Based on the 2020 data from the National Survey on Drug Use and Health, cocaine is the most commonly used substance after alcohol and cannabis. Data is more staggering than we think, as alcohol use and cannabis along with other illicit drug use often coexist with cocaine. Substance abuse is a hidden pandemic in the United States and around the world. Based on the 2020 data from the National Center for Drug Abuse Statistics, approximately 50% of Americans aged 12 years and older reported that they have used illicit drugs once and cocaine is the second most commonly used substance after cannabis [1].

5.5 million persons in the United States were first time users of cocaine in 2018, 1 in 5 drug overdose deaths were cocaine-related in 2017, and the rate of cocaine-related overdose deaths alone increased from 1.4% to 4.5% in 2012-2018. Moreover, June 2020 data from the Centers for Disease Control and Prevention showed that 13% of Americans reported starting or increasing substance use as a way of coping with stress or emotions related to the Coronavirus-19 pandemic [2]. Therefore, having a good understanding of cocaine and its effects is more important than ever in clinical practice.

2. CASE PRESENTATION

Our patient is a 54 year old female with a past medical history of heart failure with reduced ejection fraction of 15-20%, chronic atrial flutter, cocaine abuse, hypertension and asthma, who presented to the emergency department with shortness of breath and abdominal distention. She reported a progressive increase in swelling of her limbs and abdomen for the last few weeks as well as worsening shortness of breath for the last few days. She had multiple admissions with similar complaints in different hospitals. Four months prior to the current admission, the patient underwent direct current cardioversion for her atrial flutter in a different hospital which briefly had restored sinus rhythm and was discharged on amiodarone and apixaban.

Physical examination on admission showed tachycardia averaging at 120 beats per minute, tachypnea, bilateral lung wheezing, abdominal distention and bilateral leg edema up to the thigh. Labs on admission can be found in the table below (Table 1). Urine toxicology was positive for cocaine; the patient admitted using crack cocaine twice a week for the past twenty years but could not specify the amount of cocaine used each time. The patient also admitted to smoking a half a pack of cigarettes a week since age 20 and drinking a half a cup of whiskey on the weekends. Electrocardiogram on

admission showed atrial flutter with a heart rate of 128 beats per minute (Figure 1). Chest X-ray on admission showed massive cardiomegaly (Figure 2).

Table 1. Patient's Laboratory Findings on Admission

Laboratory Test	Normal Range	Results
White Blood Cells	4,500 - 11,000 cells/ μ L	8.8 cells/ μ L
Hemoglobin	11.0 - 15.0 g/dL	13.8 g/dL
Hematocrit	35 - 46%	44.0%
Mean Corpuscular Volume	80 - 100 fL	86.5 fL
Platelets	130,000 - 400,000 PLT/ μ L	446 PLT/ μ L
Aspartate Aminotransferase	5 - 34 U/L	77 U/L
Alanine Transaminase	10 - 55 U/L	22 U/L
Total Bilirubin	0.2 - 1.2 mg/dL	1.6 mg/dL
Blood Urea Nitrogen	9.8 - 20.1 mg/dL	29.1 mg/dL
Creatinine	0.57 - 3.1.11 mg/dL	1.57 mg/dL
Estimated Glomerular Filtration Rate	\geq 90.0 mL/min/1.73m ²	39.0 mL/min/1.73m ²
Potassium	3.5 - 5.1 mmol/L	4.7 mmol/L
Phosphorus	2.3 - 4.7 mg/dL	4.1 mg/dL
Magnesium	1.6 - 2.6 mg/dL	2.5 mg/dL
Brain Natriuretic Peptide	10.0 - 100.0 pg/mL	1821 pg/mL
High Sensitivity Troponin	0.0 - 17.0 ng/L	4.2 ng/L
Prothrombin time	9.8 - 13.4 sec	19.4 sec
International Normalized Ratio	0.85 - 1.15 ratio	1.60 ratio
Partial Thromboplastin Time	24.9 - 35.9 sec	38.9 sec
Thyroid Stimulating Hormone	0.465 - 4.680 μ IU/ml	5.27 μ IU/ml
Free Thyroxine	0.78 - 2.19 ng/dL	2.24 ng/dL

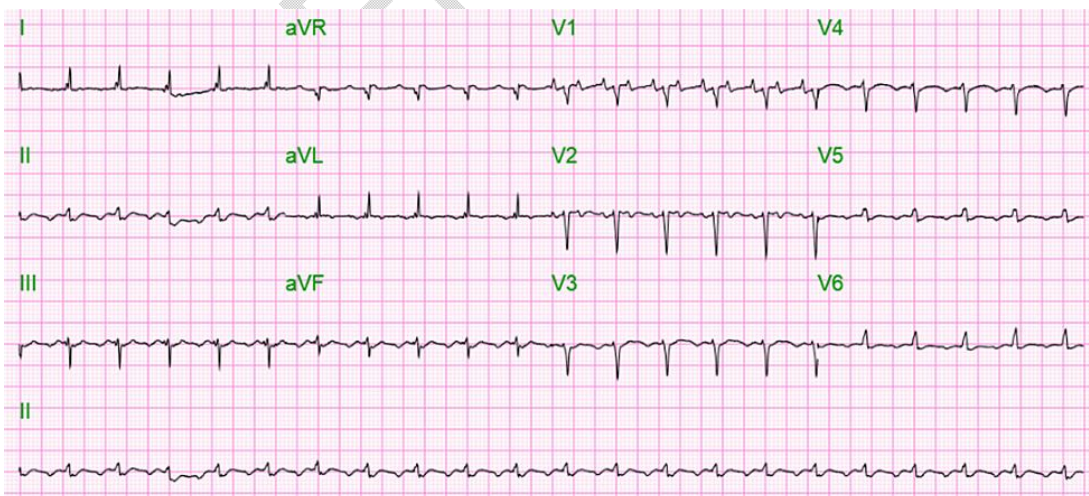


Fig. 1. Electrocardiogram on admission showing atrial flutter with 2:1 conduction with a rapid ventricular rate of 128 beats per minute.

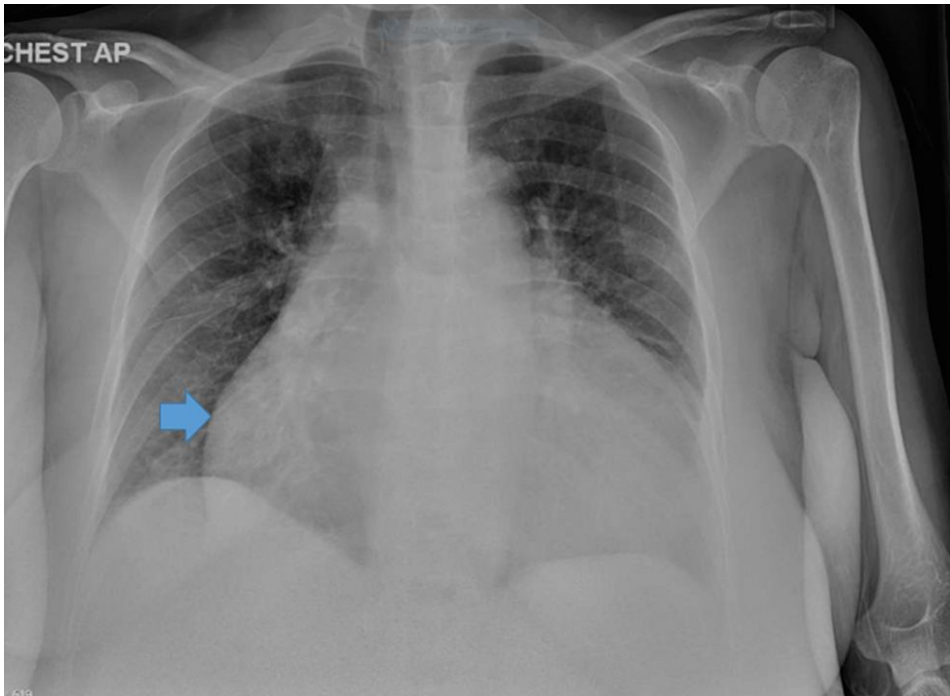


Fig. 2. Chest X-ray on admission showing massive cardiomegaly.

Computed tomography scan of the abdomen and pelvis done on admission for the patient's abdominal distention showed large ascites, inhomogeneous liver enhancement, cardiomegaly with reflux of contrast into the hepatic veins suggesting tricuspid valve insufficiency, and anasarca. Echocardiogram showed left ventricular dilatation with severe systolic dysfunction, ejection fraction of 15-20%, grade 3 diastolic dysfunction, a dilated and hypokinetic right ventricle, paradoxical septal motion, markedly elevated pulmonary pressure, bi-atrial dilatation, moderate mitral regurgitation, severe tricuspid regurgitation, a small pericardial effusion and a large pleural effusion.

The patient was admitted for congestive heart failure exacerbation and uncontrolled atrial flutter. She was initially treated with intravenous furosemide, intravenous diltiazem and intravenous/oral metoprolol tartrate in the emergency room. Her heart rate remained uncontrolled at around 140 beats per minute and so she was started on intravenous amiodarone drip and was admitted to the coronary care unit; intravenous amiodarone was eventually bridged to oral amiodarone and oral metoprolol succinate. Apixaban was also continued for her atrial flutter. Paracentesis was also done and she was continued on intravenous lasix. While her symptoms showed improvement after a week of treatment and her heart rate was controlled, repeat electrocardiogram showed persistent atrial flutter (Figure 3); the decision not to perform repeat cardioversion for the patient was made, as the patient was deemed unlikely to remain in sinus rhythm given her bi-atrial dilation and given her history of not remaining in sinus rhythm after her prior cardioversion. The patient was ultimately discharged on a cardiac LifeVest to follow up outpatient for implantable cardioverter defibrillator placement.

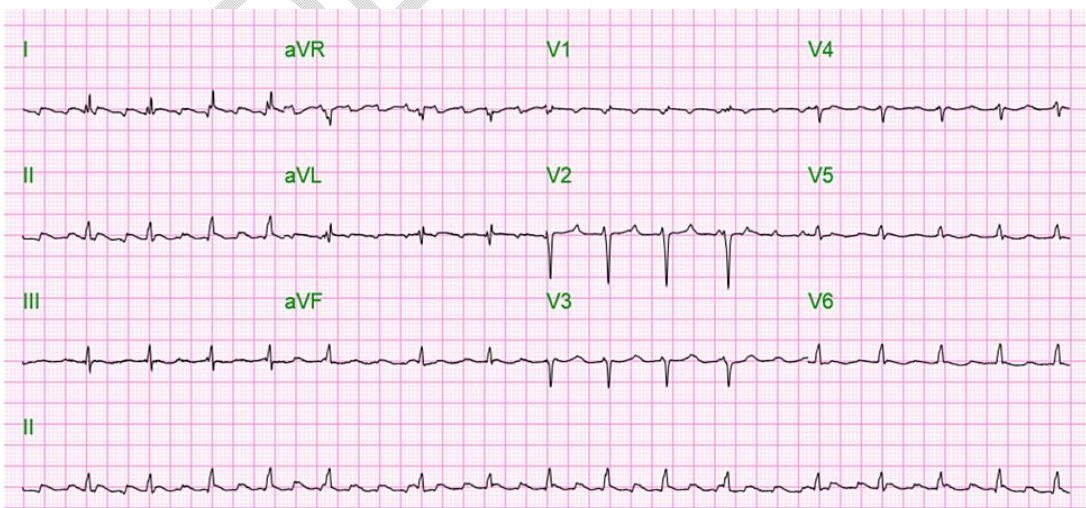


Fig. 3. Electrocardiogram showing atrial flutter with a controlled ventricular rate of 97 beats per minute.

3. RESULTS AND DISCUSSION

Atrial flutter is a type of supraventricular arrhythmia characterized by regular atrial depolarizations of 300 beats per min with a fixed or variable ventricular rate. Typical (or classic) atrial flutter is when the rhythm involves the single reentrant circuit around the cavotricuspid areas, and atypical atrial flutter is when the rhythm follows a different circuit. Common symptoms of atrial flutter are palpitations, shortness of breath, or dizziness. It is also important to understand that atrial flutter is associated with increased risk of atrial thrombus formation with systemic embolization, especially to the cerebral circulation [3].

Causes of cardiac arrhythmias include thyrotoxicosis, pulmonary embolism, obesity, sleep apnea, pericarditis, pulmonary hypertension, and stimulant drug (e.g. cocaine or amphetamine) use [3, 4, 5]. Previous studies have also revealed that the combination of alcohol and cocaine have synergistic effects on heart rate and can lead to up to 30% increased blood cocaine levels along with the formation of the cardiotoxic metabolite cocaethylene [6].

Established risk factors for the development of atrial flutter include smoking, increased PR interval, myocardial infarction, and heart failure [7]. Atrial flutter has overlapping etiology with atrial fibrillation and is infrequent in the structurally normal heart. While the association between cocaine use and other cardiac arrhythmias like atrial fibrillation and ventricular fibrillation is already well established, use of cocaine and its specific association with atrial flutter specifically is very infrequently encountered in clinical scenarios [8]. One study found that intravenous administration of cocaine in dogs resulted in atrial flutter [9]. Another case report described atrial flutter that occurred in a preterm infant that was exposed to cocaine in utero [10].

Our patient smoked a half a pack of cigarettes a week since age 20, drank half a cup of whiskey on the weekends, and was a regular user of cocaine with the last use being a few days before admission. Other risk factors associated with atrial flutter in our patient were obesity (her body mass index was 31) and congestive heart failure.

Cocaine acts primarily by blocking the presynaptic reuptake of norepinephrine/dopamine, by producing norepinephrine/dopamine at the postsynaptic receptors and by acting as a potent sympathomimetic. Cocaine is also believed to increase neurotransmitter release from central and peripheral stores [11]. Arrhythmogenic effects of cocaine have been attributed to the blockade of sodium and potassium channels, catecholamine excess, myocardial infarctions and myocarditis. Rare sinus bradycardia has been described as a result of chronic cocaine use, possibly due to cocaine-induced desensitization of beta-adrenergic receptors [12].

Cocaine related effects and cardiac arrhythmias depend on the route, frequency, and amount of use. Duration of action varies from one hour for intravenous use and up to three hours for mucosal use, so effects including arrhythmias could also be transient and could resolve when cocaine is metabolized [13].

Supraventricular and ventricular cardiac arrhythmias have been reported with cocaine use; ventricular arrhythmias are usually triggered by supraventricular arrhythmias. Autonomic imbalance along with the abnormal cardiac automaticity associated with the high adrenergic state precipitated by cocaine are believed to trigger arrhythmia [14, 15]. Cocaine induced ischemia is believed to cause reentrant tachycardia through electrical inhomogeneity [8]. Cocaine related death is usually attributed to cardiac ischemia and ventricular fibrillation. Up to 10% of cocaine related deaths showed no specific findings on autopsy, so undiagnosed arrhythmia and myocardial infarction is believed to be the cause [16].

4. CONCLUSION

Here we present a case of stable atrial flutter in a patient with chronic cocaine use as well as a literature review of the topic. It is important to look out for atrial flutter in patients' who use cocaine and initiate prompt treatment to reduce morbidity and mortality, as arrhythmias are a major cause of cocaine related deaths.

CONSENT AND ETHICAL APPROVAL

As per international standard or university standard guidelines, patients consent and ethical approval has been collected and preserved by the authors.

REFERENCES

1. National Center for Drug Abuse Statistics. [Substance abuse and addiction statistics](https://drugabusestatistics.org). Accessed: November 11, 2022: <https://drugabusestatistics.org>.
2. Czeisler MÉ , Lane RI, Petrosky E, et al.: [Mental health, substance use, and suicidal ideation during the COVID-19 pandemic — United States, June 24-30](#). MMWR Morb Mortal Wkly Rep. 2020, 69:1049-1057. [10.15585/mmwr.mm6932a1](https://doi.org/10.15585/mmwr.mm6932a1)
3. Rodriguez Ziccardi M, Goyal A, Maani CV.: [Atrial flutter](#). StatPearls (ed): StatPearls Publishing, Treasure Island, Florida; 2022.
4. Granada J, Uribe W, Chyou PH, et al.: [Incidence and predictors of atrial flutter in the general population](#). J Am Coll Cardiol. 2000, 36:2242-2246. [10.1016/s0735-1097\(00\)00982-7](https://doi.org/10.1016/s0735-1097(00)00982-7)
5. Garson A Jr, Bink-Boelkens M, Hesslein PS, Hordof AJ, Keane JF, Neches WH, Porter CJ: [Atrial flutter in the young: a collaborative study of 380 cases](#). Am Coll Cardiol. 1985, 6:871-878. [10.1016/s0735-1097\(85\)80497-6](https://doi.org/10.1016/s0735-1097(85)80497-6)
6. Billman GE, Lappi MD: [Effects of cocaine on cardiac vagal tone before and during coronary artery occlusion: cocaine exacerbates the autonomic response to myocardial ischemia](#). J Cardiovasc Pharmacol. 1993, 22:869-876. [10.1097/00005344-199312000-00015](https://doi.org/10.1097/00005344-199312000-00015)
7. Rahman F, Wang N, Yin X, et al.: [Atrial flutter: Clinical risk factors and adverse outcomes in the Framingham Heart Study](#). Heart Rhythm. 2016, 13:233-40. [10.1016/j.hrthm.2015.07.031](https://doi.org/10.1016/j.hrthm.2015.07.031)
8. Wood DM, Dargan PI, Hoffman RS: [Management of cocaine-induced cardiac arrhythmias due to cardiac ion channel dysfunction](#). Clin Toxicol (Phila). 2009, 47:14-23. [10.1080/15563650802339373](https://doi.org/10.1080/15563650802339373)
9. Mehta A, Jain AC, Mehta MC: [Electrocardiographic effects of intravenous cocaine: an experimental study in a canine model](#). J Cardiovasc Pharmacol. 2003, 41:25-30. [10.1097/00005344-200301000-00004](https://doi.org/10.1097/00005344-200301000-00004)
10. Gad A, Morelli P, Decristofaro J: [Perinatal isolated atrial flutter associated with maternal cocaine and opiate use in a late preterm infant](#). J Matern Fetal Neonatal Med. 2010, 23:1062-5. [10.3109/14767050903300993](https://doi.org/10.3109/14767050903300993)
11. Hoffman RS: [Treatment of patients with cocaine-induced arrhythmias: bringing the bench to the bedside](#). Br J Clin Pharmacol. 2010, 69:448-57. [10.1111/j.1365-2125.2010.03632.x](https://doi.org/10.1111/j.1365-2125.2010.03632.x)
12. Ouali S, Guerhazi O, Guerhazi F, et al.: [Drug abuse-induced cardiac arrhythmias: mechanisms and management](#). Cardiac Arrhythmias. Umashankar Lakshmanadoss (ed): InTechOpen, United Kingdom; 2018. 1:177-190. [10.5772/intechopen.76022](https://doi.org/10.5772/intechopen.76022)
13. Perez-Reyes M, Di Guiseppi S, Ondrusek G, Jeffcoat AR, Cook CE : [Free-base cocaine smoking](#). Clin Pharmacol Ther. 1982, 32:459-465. [10.1038/clpt.1982.189](https://doi.org/10.1038/clpt.1982.189)
14. Kloner RA, Hale S, Alker K, Rezkalla S : [The effects of acute and chronic cocaine use on the heart](#). Circulation. 1992, 85:407-419. [10.1161/01.CIR.85.2.407](https://doi.org/10.1161/01.CIR.85.2.407)
15. Mouhaffel AH, Madu EC, Satmary WA, Fraker TD Jr: [Cardiovascular complications of cocaine](#). Chest. 1995, 107:1426-1434. [10.1378/chest.107.5.1426](https://doi.org/10.1378/chest.107.5.1426)
16. Tisdale JE, Chung MK, Campbell KB, Hammadah M, Joglar JA, Leclerc J, Rajagopalan B: [Drug-induced arrhythmias: A scientific statement from the American Heart Association](#). Circulation. 2020, 142:214-233. [10.1161/CIR.0000000000000905](https://doi.org/10.1161/CIR.0000000000000905)