

Case study

Bilateral Bouchut tuberculoma complicating multifocal tuberculosis : a case report.

Abstract:

Introduction: Tuberculosis is a serious infection and remains a major cause of worldwide mortality and morbidity. Declared by the World Health Organization (WHO) an "urgent global health problem" in 1993. In Morocco, there are about 25,000 new cases / year. Extra-pulmonary localizations represent 35% of all damage, of which 1 to 2% are ocular damage.

Purpose: The purpose of this clinical case is to underline the value of the ophthalmological examination, retinography as well as angiography in the orientation of the diagnosis of tuberculosis.

Case report: We report the case of a 29-year-old patient, immunocompetent, with no notion of tuberculosis contagion, hospitalized for a week in the pulmonology department for management of multifocal tuberculosis associating a microscopy-negative and culture positive pulmonary tuberculosis and multifocal tuberculous spondylodiscitis (cervical and lumbar). A progressive and bilateral decrease in his visual acuity was reported one week after his hospitalization, prompting an ophthalmological consultation which objectified through fundus examination, retinography and fluorescein angiography the presence of bilateral Bouchut's tuberculoma. The patient is put on antitubercular treatment for a period of nine months associated with corticosteroid therapy and vitamin therapy.

Conclusion: In Morocco, tuberculosis continues to surprise as well by its extension affecting the debilitated subject and the immunocompetent subject, as by its various presentations including the ocular involvement that must be sought by a careful and systematic ophthalmological examination. Bouchut's tuberculoma can be a valuable aid in the diagnosis of multifocal tuberculosis by a simple examination of the fundus.

Keywords: Bouchut's tuberculoma, multifocal tuberculosis, fundus examination, retinography, fluorescein angiography, antitubercular treatment.

Abbreviations:

TB: tuberculosis.

Mt: Mycobacterium tuberculosis.

KB: Koch's bacillus.

Bt: Bouchut's tuberculoma.

IOT: intraocular tuberculosis.

ATT: antitubercular treatment.

INTRODUCTION:

Tuberculosis is a serious infection caused by *Mycobacterium tuberculosis* (Mt) and remains a major cause of worldwide mortality and morbidity [1-2].

It is endemic in developing countries. Declared by the World Health Organization (WHO) an "urgent global health problem" in 1993.

In Morocco, there are approximately 25,000 new cases per year [1 - 2]. Extra-pulmonary localizations represent 35% of all damage, of which 1 to 2% are ocular damage [3 - 4].

Tuberculosis-related ophthalmological disorders are diverse, including Bouchut's tuberculoma (Bt) [5].

The purpose of this clinical case is to underline the value of the ophthalmological examination, retinography as well as angiography in the orientation of the diagnosis of tuberculosis.

CASE REPORT:

We report the case of a 29-year-old patient, with no notion of tuberculosis infection, hospitalized for a week in the pulmonology department for treatment of multifocal tuberculosis. The anamnesis found for 3 weeks (before his hospitalization) a dragging bronchial syndrome without any notion of tuberculosis contagion, cervico-lumbar rachialgia, all evolving in a febrile context (38°C), with night sweats, asthenia, and an alteration of the general condition (weight loss estimated at 5 kilograms). A gradual and bilateral decrease in his visual acuity, more marked in his left eye, was reported one week after his hospitalization, prompting an ophthalmological consultation.

The ophthalmological examination shows: visual acuity of 7/10 Parinaud 2 (P2) in the right eye and 6/10 P2 in the left eye, corrected to 9/10 P2 for both eyes; The photomotor reflex is present and normal in both eyes; The anterior segment and the intraocular pressure are normal for both eyes.

Examination of the right eye fundus reveals a yellowish protruding, subretinal, inferior temporal paramacular formation with blurred contours (evoking a Bouchut's tuberculoma), measuring a papillary diameter, with chorioretinal folds, small flame hemorrhage, and a blurring of the papillary edges (**Figure 1: A**). Examination of the left eye fundus reveals a yellowish protruding, subretinal, superior temporal paramacular formation with blurred contours, measuring 2 papillary diameters, chorioretinal folds, and a blurring of the papillary edges (**Figure 1: B**).

Retinal fluorescein angiography reveals in areas corresponding to the location of the tuberculoma, hypofluorescence in the early stages with centrifugal hyperfluorescence becoming diffuse in the late stages associated with later papillary retention (**Figure 2**).

General examination found fever at 37.5°C, painful cervico-lumbar stiffness.

Biologically, the sedimentation rate is 30 mm in the first hour. The intradermal tuberculin reaction is phlyctenular and the QuantiFERON®-TB Gold test is positive. The search for KB by tubing was negative during direct examination on 3 occasions with a positive culture = pulmonary tuberculosis with negative microscopy and positive culture (PTM-C+). HIV and syphilis serologies are both negative.

On the radiological level: the chest X-ray shows a parenchymal lesion of the right upper pulmonary lobe (**Figure 3**). An emergency craniocerebral computed tomography scan is normal. Spinal magnetic resonance imaging (MRI) suggests multifocal (cervical and lumbar) spondylodiscitis (**Figure 4**), the scan-guided biopsy

of which revealed an epithelioid and gigantocellular granuloma with caseous necrosis.

The lumbar puncture is impracticable following the lumbar localization of the spondylodiscitis.

Faced with the epidemiological, clinical, bacteriological, radiological and histological aspect very suggestive of disseminated tuberculosis with intraocular localization, a treatment based on 4 antibacillary agents is administered to the patient : rifampicin "R" (10 mg/Kg/day), isoniazid "H" (5 mg/Kg/day), Pyrazinamide "Z" (20 mg/Kg/day) and Ethambutol "E" (15 mg/kg/day), combined with corticosteroid therapy (1 mg/Kg/day) and vitamin therapy B6 (250mg/week). No local treatment was prescribed. The expected duration of treatment is: 2 months of RHZE and 7 months of RH.

DISCUSSION:

Tuberculosis is a major cause of morbidity and mortality in developing countries. The prevalence of tuberculosis worldwide is estimated at around 10 million new cases per year. In Morocco there are about 25 thousand new cases / year [1 - 2]. Extra-pulmonary localizations represent 35% of all damage, of which 1 to 2% are ocular damage [3 - 4].

The ophthalmological damage linked to tuberculosis is diverse: all the structures of the eye can be affected (provided there is no pathognomonic damage), however, there are clinical forms strongly suggestive of ocular tuberculosis [5]:

- Granulomatous anterior uveitis.
- Serpiginous multifocal pseudo-choroiditis.
- Tuberculoma of Bouchut.
- Retinal vasculitis.
- Eales.

Bouchut's tuberculoma is present in 30% of proven cases of pulmonary tuberculosis and can even provide vital information, leading to the diagnosis of unrecognized miliary tuberculosis [6].

Indeed, this choroidal tuberculoma was recognized for the first time by Gueneau de Mussyen in 1830 [7] and proved by Coehnein in 1867, causing experimental intraocular tuberculosis (IOT) by injection of an inoculum of Koch's bacillus in pigs. Intraocular foci are most often secondary to another localization, especially pulmonary and/or meningeal.

Physiopathologically, Bouchut's tuberculoma is linked to hematogenous dissemination of Mt (= secondary ocular tuberculosis). The bacteria directly reach the inside of the eye. At this level, a classic granulomatous reaction will develop, with the formation of caseous giant cell granulomas. Necrosis of the retina and adjacent retinal pigment epithelium may occur. A recent study has also shown the presence of mycobacteria within the retinal pigment epithelium, suggesting that these cells could serve as a reservoir for the pathogen [8]. This direct mechanism differs from the hypersensitivity reaction against mycobacterial antigens (indirect mechanism) found in certain clinical forms of tuberculous uveitis, such as vasculitis [9, 10].

The fortuitous discovery of these Bouchut tuberculomas is not uncommon, occurring in 13 to 18% of cases depending on the series. In a prospective series of 100 patients with tuberculosis, 18 patients had ocular involvement, including 17 with choroidal involvement [11]. For a long time, it was written that choroidal Bt were found only in patients with pulmonary tuberculosis and/or meningitis at the terminal stage, or even at autopsy [7].

Several authors describe choroidal tubercles diagnosed very early in children suffering from miliary tuberculosis and Chung [12] emphasizes that this lesion may be the first manifestation of disseminated tuberculosis, making it possible to make an early diagnosis and thus start treatment without wait for bacteriological or histological confirmation.

In fact, the difficulty of bacteriological diagnosis of tuberculosis whatever its location and at the intraocular level in particular is today an unavoidable reality [13].

Confirmation of ocular tuberculosis is based on the detection of Mt in ocular tissues or fluids. This detection can be done by bacteriological or pathological examination or by "Polymerase Chain Reaction" or PCR.

However, the diagnosis is most often presumptive, based on a range of arguments: Epidemiological arguments; Clinical arguments; Radiological arguments; Elimination of differential diagnoses; Results of the intradermal tuberculin reaction and the Quantiféron® TB gold test; Response to initiated anti-tuberculosis treatment "trial treatment".

The bacteriological and histological diagnosis of an IOT is not a common practice despite the extraordinary progress made in this area. Indeed, the demonstration of Mt from the examination of tissues or intraocular fluid is difficult to achieve and not very fruitful given the low concentration of the germ in the aqueous humor or the vitreous [6]. But, it is currently possible thanks to the technique of the "Polymerase Chain Reaction" or PCR which would allow a rapid and specific identification of the germ [14].

Barondes [15] suggests chorioretinal endo-biopsy, which seems to be an interesting method but needs to be supported by other studies. In fact, most often the histological diagnosis is made on an enucleation specimen [16].

The QuantiFERON® -TB test detects the production of gamma-interferon due to the stimulation of T lymphocytes sensitized by Mt-specific antigens. Its sensitivity is between 70 and 89% and its specificity between 96 and 98% [17 – 18]. This test is more specific than the intradermal tuberculin reaction in low-endemic countries where vaccination remains mandatory [18]. The QuantiFERON®-TB Gold Plus test is considered positive above the threshold of 0.35 IU/mL, but the frequency of false positives (during sarcoidosis, Behçet's disease or idiopathic retinal vasculitis for example) would remain significant for thresholds below 2 IU/mL [19]. A threshold of 2 IU/mL would therefore have a sensitivity of 84% and a specificity of 87% [19].

Our case underlines the value of the ophthalmological examination in the orientation of the diagnosis of TB disease in general, and ocular TB in particular. Bouchut's tuberculoma can be a valuable aid in the diagnosis of systemic tuberculosis by a simple examination of the fundus. Considering the possibility of asymptomatic clinical forms, the clinician should remember to request fundus examination in any patient with pulmonary or extra-pulmonary tuberculosis, in order to detect IOT in time and avoid sequelae.

There is no consensus on the treatment of ocular tuberculosis. Therapeutic regimens as well as the duration of treatment vary according to the studies. The majority of teams opt for quadruple therapy (rifampicin "R" (10 mg/kg/day), isoniazid "H" (5 mg/kg/day), pyrazinamide "Z" (20 mg/kg/day) and ethambutol "E" (15 mg/kg/day)) for a period of 2 months followed by dual therapy (isoniazid and rifampicin). The total duration of treatment varies according to the studies between 6 months and 17 months [20].

The combination of systemic corticosteroid therapy with ATT is recommended in cases of Bouchut's tuberculoma [5]. It is necessary to control ocular inflammation

and prevent tissue destruction. The recommended dosage of prednisone, in combination with ATT, is 60 mg/day [21] or even 1.5 mg/kg/day [22] (a 30% increase in dosage is necessary due to the inducing effect of rifampicin) before a gradual decrease and then a stopover 3 months [9]. A response on the ocular inflammation is expected within 4 to 6 weeks, whereas Bouchut's tuberculoma heals in 3 months [9]. ATT is not trivial (cutaneous, hematological and hepatic side effects) and requires joint follow-up in internal medicine to assess compliance and tolerance. The duration of the post ATT follow-up is also debated. A minimum of six months is required [23 – 24]. For some, a longer follow-up is recommended up to 9 months [25] or even 18 months [22].

Subject to well-conducted and prolonged treatment, the clinical course of IOT is generally favorable. The sequelae are linked to late diagnosis and treatment.

CONCLUSION:

In Morocco, tuberculosis continues to surprise as well by its extension affecting the debilitated subject and the immunocompetent subject, as by its various presentations including the ocular involvement that must be sought by a careful and systematic ophthalmological examination.

Unfortunately, its diagnosis remains a challenge in most cases due to the polymorphism of ocular signs. The diagnosis is based on epidemiological, clinical, biological, radiological and therapeutic arguments. Bouchut's tuberculoma can be a valuable aid in the diagnosis of multifocal tuberculosis by a simple examination of the fundus.

When a tuberculous origin is suspected, every effort should be made to try to highlight the Mt, a trial treatment is worth considering if in doubt.

FIGURES :

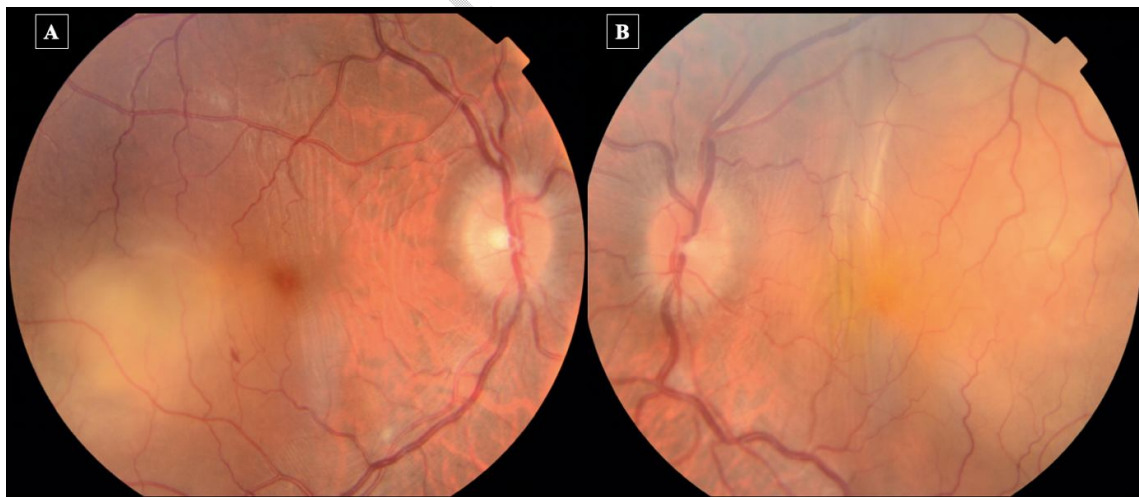

Figure 1: Color fundus photograph showing:

A: in the right eye, a yellowish protruding, subretinal, inferior temporal paramacular formation with blurred contours (evoking a Bouchut's tuberculoma), measuring a papillary diameter, with chorioretinal folds, small flame hemorrhage, and a blurring of the papillary edges.

B: in the left eye, a yellowish protruding, subretinal, superior temporal paramacular formation with blurred contours, measuring 2 papillary diameters, chorioretinal folds, and a blurring of the papillary edges.

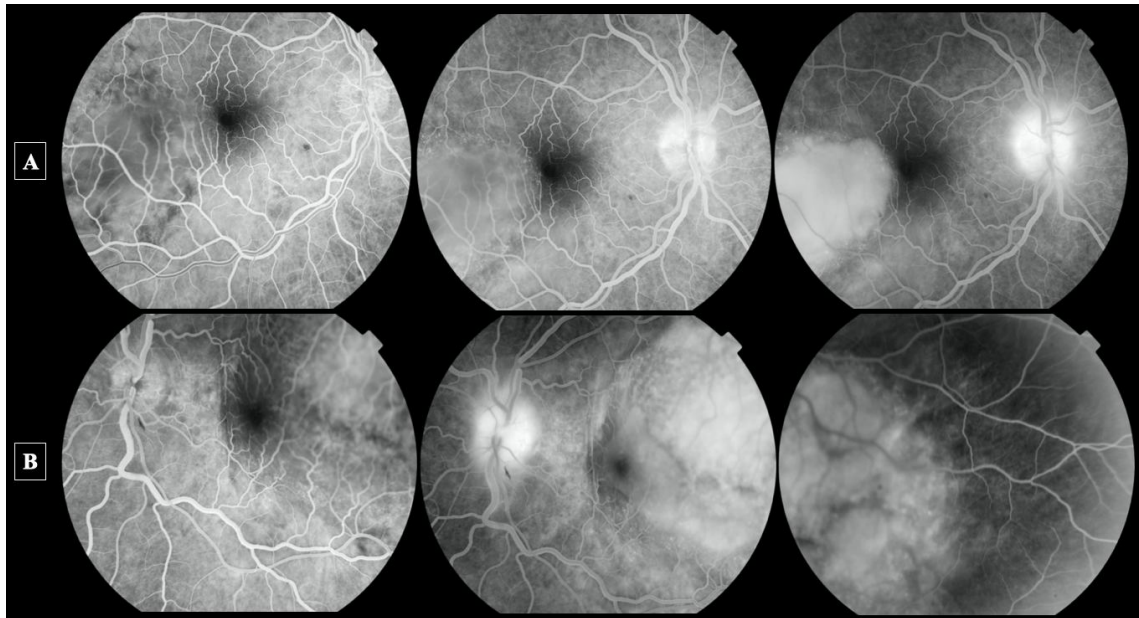


Figure 2 (A = right eye; B = left eye): Photo of retinal fluorescein angiography reveals in areas corresponding to the location of Bouchut's tuberculoma, hypofluorescence in early times with centrifugal hyperfluorescence becoming diffuse in late times associated with later papillary retention.

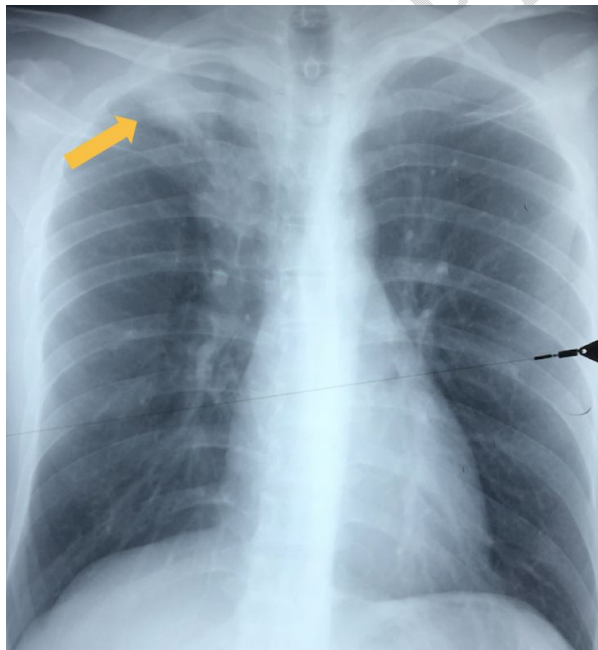


Figure 3: Chest X-ray showing a parenchymal lesion of the right upper pulmonary lobe.

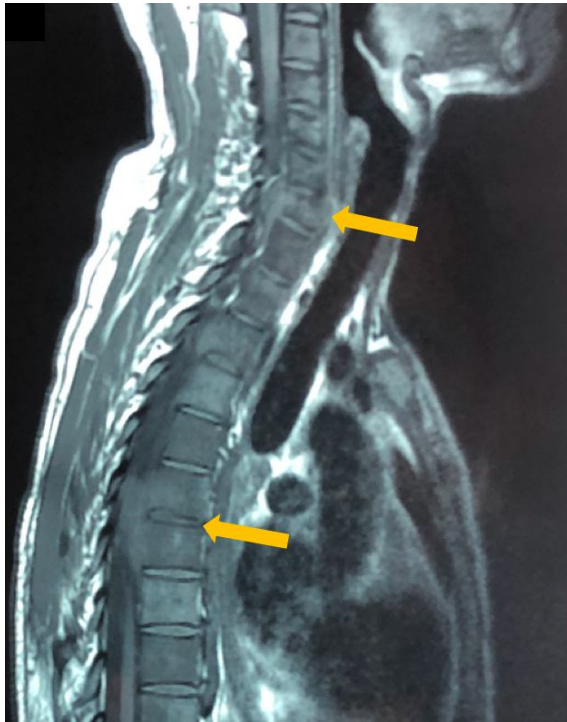

Figure 4: Spinal magnetic resonance imaging (MRI) suggesting a multifocal (cervical and lumbar) spondylodiscitis.

REFERENCES:

- [1] Laktaoui A, A Naoumi, K Reda, M Kriet, A Elouarsani, A Khayati, A Elharradi, A Rouimi, A Douhal, J Mounahc, A Houmadi. Macular tuberculosis and optic neuritis: rare association during tuberculous meningoencephalitis. *J Fr Ophthalmol*. 2009 Nov;32(9):673–8. [PubMed] [Google Scholar]
- [2] Karim A, Laghmari M, Boutimzine N, Lamarti A, Ibrahimy W, Essakali N, et al. Pseudotumoral choroidal granuloma revealing tuberculosis: report of a case. *J Fr Ophthalmol*. 2003 Jun; 26(6):614–7. [PubMed] [Google Scholar]
- [3] Benchekroun S, El Mansouri Y, Rachid R, El Belhadji M, Laouissi N, Zaghoul K, et al. Pseudotumoral choroidal granuloma in miliary tuberculosis. *J Fr Ophthalmol*. 1999 Aug-Sep;22(7):771–5.[PubMed] [Google Scholar]
- [4] El Bakkali M, Halhal M, Chefchaoui M, Belmekki M, Abdellah H, Berraho A. Tuberculous uveitis. *J Fr Ophthalmol*. 2001 Apr; 24(4): 396-9. PubMed | Google Scholar.
- [5] S. Trad, D. Saadoun, M.H. Errera, S. Abad, P. Bielefel, C. Terrada, D. Sène, B. Bodaghi, P. Sève. Ocular tuberculosis. *The Journal of Internal Medicine* 39 (2018) 755–764 761762.
- [6] Helm CJ, Holland GN. Ocular tuberculosis. *Surv Ophthalmol* 1993; 38: 229-51.
- [7] Cangemi FE, Frudman AH, Josephberg R. Tuberculoma of choroid. *Ophthalmology* 1980; 87: 252-6.
- [8] Ernst JD, Trevejo-Nunez G, Banaiee N. Genomics and the evolution, pathogenesis, and diagnosis of tuberculosis. *J Clin Invest* 2007, 117: 1738-1745.

- [9] Gupta V, Gupta A, Rao NR. Intraocular tuberculosis update. *Surv Ophthalmol* 2007; 52: 561-587.
- [10] Gupta A, Gupta V, Arora S et al. PCR-positive tubercular retinal vasculitis. Clinical characteristics and management. *Retina* 2001, 21: 435-444.
- [11] Bouza E, Merino P, Muñoz P, Sanchez-Carrillo C, Yáñez J, Cortés C. Ocular tuberculosis: A prospective study in a general hospital. *Medicine (Baltimore)*. 1997 Jan;76(1):53–61. [PubMed] [Google Scholar]
- [12] Chung YM, Shiang Yeh T, Shwn Jiuan Sheu S. Macular subretinal neovascularization in choroidal tuberculosis. *Ann Ophthalmol* 1989; 21: 225-9.
- [13] Biswas J, Madhavan HN, Gopal L, Sengamedu S. Intraocular tuberculosis. Clinicopathologic study of five cases. *Retina* 1995; 15:461-8.
- [14] Recilla-Gispert C, Ortega-Lamoceu G, Arehlanes-Garcia L, Herrera Barnes T. Chorioretinitis secondary to *Mycobacterium tuberculosis* in acquired immune deficiency syndrome. *Retina* 1997; 17:437-9.
- [15] Barondes MJ, Sponsels WE, Stevens TS, Plotnik RD. Tuberculous choroiditis diagnosed by chorioretinal endobiosis. *Am J Ophthalmol* 1991; 91:460-1.
- [16] S. Benchekroun, Y. El Mansouri, R. Rachid, M. El Belhadji, N. Laouissi, K. Zaghoul, A. Amraoui. Pseudotumoral choroidal granuloma in miliary tuberculosis. *French Journal of Ophthalmology* 1999;22:771. Doi: JFO-07-1999-22-7-0181-5512-101019-ART10.
- [17] Lino A, Lalande V, Guetta A, Lebeau B, Heron E, Chouaid C. Diagnosis of tuberculous uveitis: interest of gamma interferon tests. *Rev Mal Respir* 2011; 28: 317–21.
- [18] Khochtali S, Gargouri S, Abroug N, Ksiasa I, Attia S, Sellami D, et al. The spectrum of presumed tubercular uveitis in Tunisia. *North Africa. Int Ophthalmol* 2015; 35: 663–71.
- [19] Gineys R, Bodaghi B, Carcelain G, Cassoux N, Boutin LTH, Amoura Z, et al. QuantiFERON-TB gold cut-off value: implications for the management of tuberculosis-related ocular inflammation. *Am J Ophthalmol* 2011; 152: 433–40.
- [20] Koubaa M, et al. Ocular tuberculosis: a series of 14 cases. *Rev Med Internal* (2017), <https://doi.org/10.1016/j.revmed.2018.02.014>.
- [21] Agrawal R, Gupta B, Gonzalez-Lopez JJ, Rahman F, Phatak S, Triantafyllopoulou I, et al. The role of anti-tubercular therapy in patients with presumed ocular tuberculosis. *Ocul Immunol Inflamm* 2015; 23:40–6.
- [22] Gupta V, Bansal R, Gupta A. Continuous progression of tubercular serpiginous-like choroiditis after initiating antituberculosis treatment. *Am J Ophthalmol* 2011; 152: 857–63.
- [23] Agrawal R, Gupta B, Gonzalez-Lopez JJ, Rahman F, Phatak S, Triantafyllopoulou I, et al. The role of anti-tubercular therapy in patients with presumed ocular tuberculosis. *Ocul Immunol Inflamm* 2015; 23:40–6.
- [24] Agrawal R, Gonzalez-Lopez JJ, Nobre-Cardoso J, Gupta B, Grant R, Addison PK, et al. Predictive factors for treatment failure in patients with presumed ocular tuberculosis in an area of low endemic prevalence. *Br J Ophthalmol* 2016; 100: 348–55.
- [25] Cordero-Coma M, Calleja S, Torres HE, del Barrio I, Franco M, Yilmaz T, et al. The value of an immune response to *Mycobacterium tuberculosis* in patients with chronic posterior uveitis revisited: utility of the new IGRAs. *Eye (London)* 2010; 24:36–43.