

Simultaneous Stent Placement at the Common Carotid Artery and Ipsilateral Internal Carotid in a Critically Compromised Bilateral Carotid Circulation: A Rare Case Report

ABSTRACT

Takayasu arteritis does contribute to numbers in some specific geographic areas, while atherosclerosis is the most common cause of carotid artery disease. Carotid artery circulation may become complicated by conditions of severe forms. Bilateral or unilateral internal carotid artery stenosis might present. The therapy of patients with this disease pattern can be difficult since simultaneous lesions of the common carotid artery and the ipsilateral internal carotid bifurcation are uncommon. Effective treatments include invasive treatments including carotid artery stenting and carotid endarterectomy as well as antiplatelets, statins, and anticoagulation. In the present case, patient had the history of transient ischemic attack and in the magnetic resonance imaging, the right internal carotid artery was blocked while the left common and internal carotid arteries had significant stenosis. Successful balloon dilatation and stenting of the patient's ipsilateral common and internal carotid arteries were performed.

Keywords: Balloon dilatation; stenting; transient ischemic attack.

1. INTRODUCTION

Atherosclerosis is the most frequent cause of carotid artery disease. However, Takayasu arteritis do contribute to numbers in some specific geographic areas of the globe. Stroke or TIA (Transient ischemic attack) is the most common clinical presentation of the disease. There are several risk factors for atherosclerotic carotid artery stenosis [1]. Some of these are factors are modifiable and compound other factors smoking or using tobacco products, obesity, sedentary lifestyle, high blood pressure (hypertension), high cholesterol, diabetes, age [2].

Diagnosis and evaluation usually requires a good history and clinical examination. The neurological presentation can range from TIA, (transient ischemic attack) to full blown stroke causing dense hemiparesis or hemiplegia [3]. On examination, carotid bruits can be appreciated on direct auscultation over carotid. Investigation mainly involved carotid doppler, CT angiogram

(CTA), Cerebral angiogram and MR angiogram (MRA) [4].

Various degree of severity can complicate carotid artery circulation. The presentation can be unilateral or bilateral internal carotid artery stenosis. Combined or tandem lesions of the common carotid artery and the ipsilateral Internal carotid bifurcation are uncommon and the management of patients with this disease pattern can be challenging. Treatment strategies include antiplatelets, statins, anticoagulation along with invasive procedures like carotid artery stenting (CAS) and carotid endarterectomy [1,5].

We present a case of patient with past history of stroke 10 years back with left hemiparesis followed by recent history of recurrent TIA. MRA done showed occluded right internal carotid artery and critical stenosis of left common and internal carotid artery. Patient underwent successful balloon dilatation followed by stenting of ipsilateral common and internal carotid arteries.

2. PRESENTATION OF CASE

2.1 Patient History

A 66-year-old male patient was admitted with recurrent episodes of TIA. There is history of stroke with left sided hemiparesis 10 years back. The patient's history explained that he was suffering hypertension for the last 15 years on regular medications. On examination his vitals were stable. Furthermore, systemic examination revealed grade 4/5 motor power in left upper and lower limbs. Sensory functions, Speech and higher neurological functions were normal. His ECG done showed normal sinus rhythm with left atrial enlargement and left ventricular hypertrophy. 2D echo-cardiogram test showed mild Left ventricular hypertrophy with normal systolic function. Carotid doppler done showed critical stenosis of left internal carotid artery with no flow across right internal carotid artery (Fig. 1). The flow velocity across internal carotid artery was very high suggestive of critical stenosis (Fig. 2) MR angiogram reveals non visualization of

right Internal carotid artery from its origin. Also there was severe stenosis at the proximal part of left common carotid artery. Short segment stenosis of more than 90 percent was seen in the proximal left internal carotid artery (Fig. 3). After properly taking informed consent patient was taken for Cerebral angiogram.

2.2 Procedure Detail

Right femoral access was taken for cerebral angiogram. 6F sheath was used through SELDINGER technique and H1 catheter was used for selective angiogram of bilateral carotid arteries. Findings of MRA was confirmed. There was total occlusion of right ICA. There was critical 90% stenosis of left CCA at the origin. Distal part of Left CCA also had disease extending into the Left ICA. The left ICA has ostioproximal lesion of 80% stenosis. PTA with stenting of left CCA followed by ipsilateral ICA was planned. The 6F femoral sheath was exchanged with 8 F guiding catheter over 035 Amplatz super stiff wire.

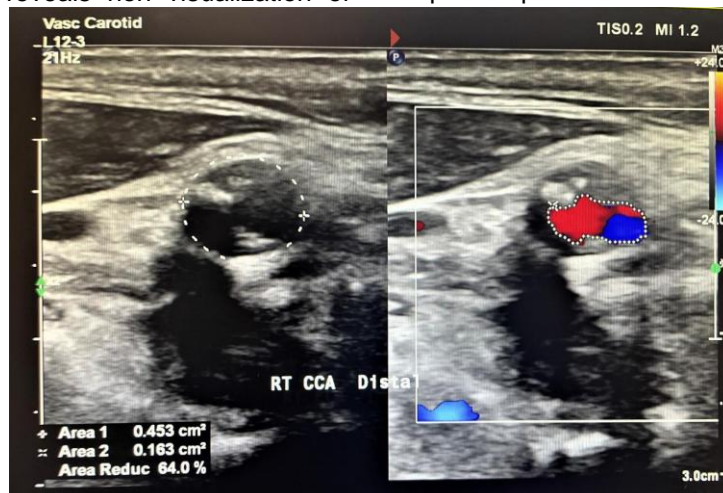


Fig. 1. Comparison of right and left Internal carotid artery in carotid Doppler Note that there is no colour flow across right ICA

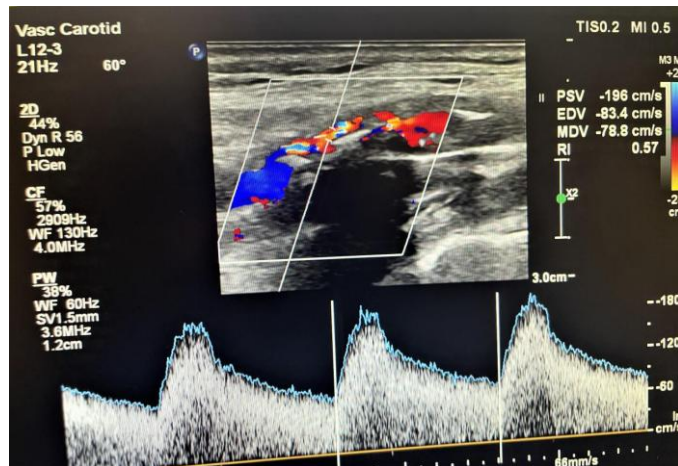


Fig. 2. High velocity across right ICA suggesting critical stenosis

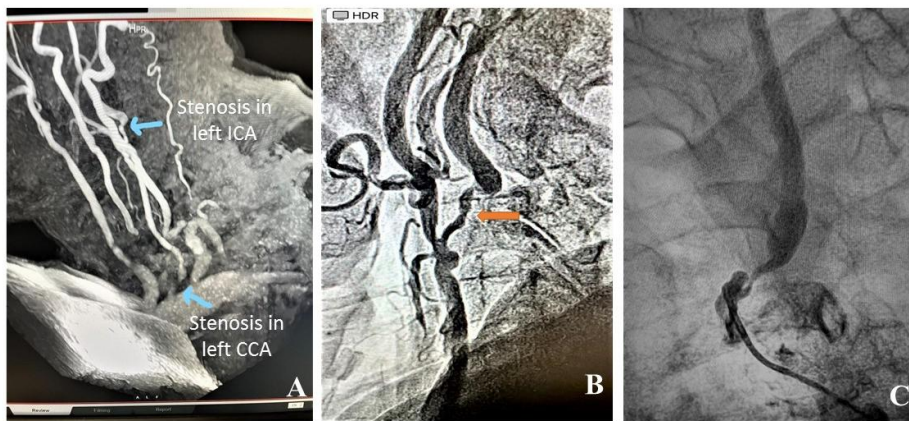


Fig. 3. Diagnosis of Critical stenosis: (A) MRA showing critical stenosis of Left CCA & ICA; (B) Cerebral angiogram showing critical left common carotid artery stenosis; (C) Cerebral Angiogram showing Left ICA critical stenosis

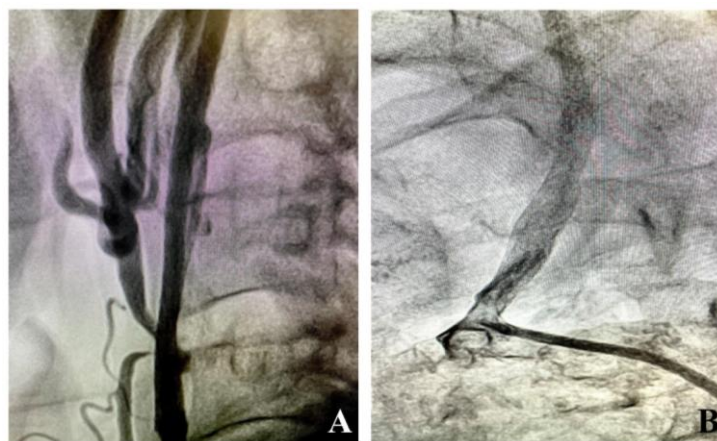


Fig. 4. Post procedure angiogram: (A) Post stenting Left ICA shows well expanded stent with good flow; (B) Post common carotid stenting angiogram showing well expanded stent in proximal CCA

With O14 fielder FC wire the CCA lesion was crossed and keeping the distal end of wire in Left ECA artery, the lesion was dilated with 3x15mm Non-compliant coronary balloon. This was followed by peripheral balloon VIATRAC 6x20mm. The fielder wire was exchanged with TRAXCESS 014 wire for extra support. The common carotid lesion was then stented with ACULINK self-expanding stent 8x40mm. Post stenting the CCA stent looked well expanded. With good flow across it. The tight lesion in left ICA worked as distal protection device while performing procedure on left CCA. Now, the left ICA was wire and dilated with 3.5X15 mm non-compliant coronary balloon. This was followed by deployment of SPIDER FX 6mm distal protection device approximately 4cm distal to lesion into ICA. Another self-expanding stent XACT 8-6X40 mm was deployed from left CCA to left ICA. Finally, the distal protection device was recaptured and check angiogram showed excellent result with well flowing left CCA, ICA and distal vessels. Patient received Nimodipine intra-carotid infusion at the rate of 15mcg/kg per hour during procedure to prevent arterial spasm. Procedure went uneventful and patient remained hemodynamically stable during and post procedure. Sheath removed in ICU after 6 hours and patient was mobilized next day and was discharge.

3. DISCUSSION

Cervical carotid artery disease is associated to one-third of all strokes. This patient population is at risk for the usual coronary and systemic atherosclerosis risk factors, such as age, male sex, family history, smoking, hypertension, hyperlipidemia, sedentary lifestyle, and high dietary fat [1]. The carotid bifurcation plaque usually causes embolization, however stenosis may also contribute to hemodynamic impairment in cervical carotid stroke. The risks of embolization and hemodynamic compromise increase with increasing carotid artery stenosis. CAS is an option for selected patients for symptomatic (≥50 percent) or asymptomatic high grade (≥80 percent) internal carotid artery stenosis. In cases of symptomatic carotid blockage (50-99%), numerous comorbidities, tracheostomy, patients who have had past neck radiation, or dissection, carotid artery stenting (CAS) is preferred. Patients with chronic complete blockage of the targeted carotid artery are not advised to undergo carotid revascularization [1].

Isolated or unilateral internal carotid artery stenting is well accepted procedure and is done worldwide. Also, simultaneous bilateral internal carotid artery has been done though not very frequently [5-7]. We did a case of critically compromised carotid circulation where right internal carotid artery was 100 percent occluded along with severe stenosis of left common and internal carotid arteries. Simultaneous stent placement at the Common Carotid Artery and ipsilateral Internal carotid in a critically compromised bilateral carotid circulation is rarely described in literature. While during dilatation and stent placements in common carotid artery, critical stenosis in left ICA prevented distal embolization. This was followed by routine deployment and retrieval of distal protection device while performing left internal carotid artery stenting.

Challenges while performing the dual ipsilateral stenting of both Left CCA and ICA were few requiring special hardware selection. Taking bulky stents across previously deployed common carotid artery stent required exchanging the 014 wire with O35 amplatz superstiff wire (parked in left ECA). Deep engagement of 8F catheter while slowly manipulating of the angle the left CCA forms with the arch of aorta helped in tracking the stent. Once 8F sheath is placed well deep into the left CCA. The stiff wire was replaced with 014 wire, which was negotiated into left ICA. This was followed by routine stenting of Left ICA under the protection of distal protection device.

4. CONCLUSION

Simultaneous Stent Placement at the Common Carotid Artery and Ipsilateral Internal Carotid is rarely performed in past. Good understanding of anatomy and hardware use in cathlab is important for successful completion of this difficult procedure. Peri or post procedural stroke due to distal embolization is the commonest complication, which can be avoided by careful manipulating and selecting hardware, therapeutic anti-coagulation & antiplatelets, use of adequate distal protection device and finally good monitoring of patient for expected complications.

CONSENT

As per international standard or university standard, patient(s) written consent has been collected and preserved by the author(s).

ETHICAL APPROVAL

As per international standard or university standard written ethical approval has been collected and preserved by the author(s).

COMPETING INTERESTS

Authors have declared that no competing interests exist.

REFERENCES

1. Qaja E, Tadi P, Kariyanna PT. Carotid artery stenosis. StatPearls [Internet]: StatPearls Publishing; 2022.
 2. Roth GA, Mensah GA, Johnson CO, Addolorato G, Ammirati E, Baddour LM, et al. Global burden of cardiovascular diseases and risk factors, 1990–2019: update from the GBD 2019 study. *Journal of the American College of Cardiology*. 2020;76(25): 2982-3021.
 3. Tadi P, Lui F. Acute stroke. Stat Pearls [Internet]: Stat Pearls Publishing; 2022.
 4. Saxena A, Ng EYK, Lim ST. Imaging modalities to diagnose carotid artery stenosis: progress and prospect. *Biomedical Engineering Online*. 2019;18: 1-23.
 5. Usachev DY, Lukshin V, Shmigel'skiy A, Akhmedov A. An anastomosis between the internal carotid and vertebral arteries in the treatment of a patient with bilateral carotid arteries occlusions. *Vopr Neurokhir*. 2016;80:72-7.
 6. Oshita J, Sakamoto S, Okazaki T, Ishii D, Kurisu K. Safety of simultaneous bilateral carotid artery stenting for bilateral carotid artery stenosis. *Interventional Neuroradiology*. 2020;26(1): 19-25.
 7. Abe T, Tokuda Y. Bilateral carotid arteries occlusion. *Case Reports*. 2013;2013: bcr2012008048.
-