

## Case study

### Liver's herniation through Lumbar incisional hernia : two cases report

#### **ABSTRACT :**

Lumbar incisional hernia is a complication affecting the continuity of the abdominal wall, accounting for approximately 3.5% of all cases, in most situations, it occurs in open nephrectomy or aortic aneurysm repair incisions. **A rarely reported entity, that can lead to discomfort, aesthetic disorder or intestinal obstruction, but the extremely rare is lumbar liver herniation. (to be rephrased)**

We present two cases of liver's herniation through lumbar incisional hernia with history of lumbar surgery; in the first patient it was for renal lithiasis, while the second **it** (omit) was for adrenalectomy. **Role of** CT scan is the modality of choice for the identification of the hernial content and the evaluation of the parietal defect in order to choose the appropriate therapeutic management. Currently, there is no clear recommendation on the best strategy for surgical treatment.

**Keywords :** liver herniation, incisional lumbar hernia, surgical repair

#### **INTRODUCTION :**

Lumbar hernia is an infrequent incisional, post-traumatic, congenital, or primary defect of the abdominal wall; they occur in the broad anatomic area bounded inferiorly by the iliac crest, superiorly by the 12th rib, laterally by the external oblique muscle, and medially by the erector spinae. Incisional herniation of the liver, usually occurs 2-3 years after previous retroperitoneal surgery, causing weakness of the abdominal wall musculature **(why there is no reference)**. We present two cases of liver's herniation through lumbar incisional hernia and discuss the surgical approach for its management.

#### **CASE REPORT :**

##### **Case 1 :**

**She is** (no need) a 68-year-old white woman with a significant medical history of right renal lithiasis for which she was operated by right lumbar surgery 5 years ago, end-stage renal failure for one year under hemodialysis, **And** she was noted to have a right lumbar incisional hernia that was repaired with a polypropylene mesh 3 months ago. Soon after that, the patient had a recurrent bulge in her right lumbar area. She was referred to us for her recurrent lumbar incisional hernia. On examination, a transverse incision scar **of**

the right flank was noted with a very large bulge badly limited, that appeared to partially retract when the patient was lying in the left lateral decubitus position, impulsive to coughing.

A CT scan was performed and showed a giant hernia, with a collar measuring 11 cm spread over 12 cm, of the right flank through the intercostal muscles of the last two intercostal spaces and the oblique muscles of the abdomen, to almost the entire right liver, the ascending colon as well as the small bowel loops.

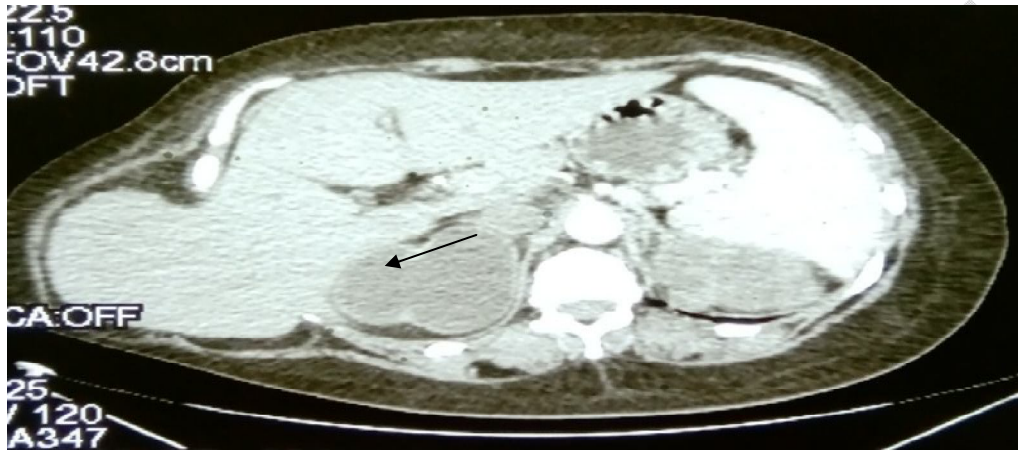


Figure 1 : CT scan showed a giant lumbar hernia of right liver (arrow)

The standard liver biochemical tests were normal. The cardiologist was consulted preoperatively and obtained an echocardiogram showing an ejection fraction of 60%.

Surgery was scheduled, and an open midline incision approach was used to identify a large parietal defect of the right lumbar area containing the enlarged right liver, right colon, and small bowel loops.

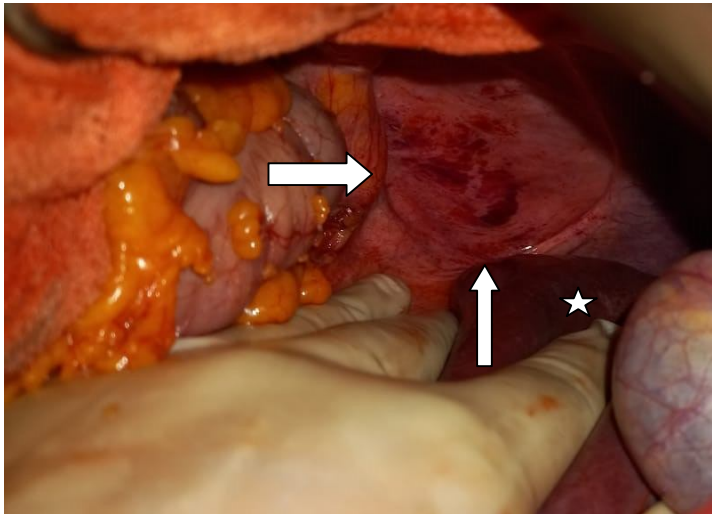


Figure 2 : large parietal defect of the right lumbar area (arrows)with right liver reduced (star)

The incisional hernia was repaired with the placement of an intraperitoneal PTFE (expanded polytetrafluoroethylene--Goretex Dual Mesh) measuring 15\*20 cm, which was fixed to the edges of the muscle with simple resorbable sutures, while trying to avoid tears and tension. The patient progressed well postoperatively and then was discharged from our hospital 2 days after surgery in good general condition.

3 (three) months later the patient was seen again in consultation, reporting a better improvement.

### Case 2 :

An 59-year-old woman underwent a routine follow-up examination at our hospital. she had undergone a right adrenalectomy via a retroperitoneal approach through a flank incision which histological finding of a benign adrenal adenoma. **significant medical history of ventricular extrasystole undertreatment. (rephrase)**

**Physical examination a large swelling** on her right flank was noted overlying by a lumbotomy scar, clearly accentuated when the patient coughed, reducible with no distinct fascial defect could be palpated.

A CT scan was performed and showed a right lateral abdominal wall defect, with a collar measuring 11cm extended over 9cm, through the transverse and internal oblique muscles, with hepatic and colonic contents, covered by the external oblique muscle which remains (ed) continuous. The standard liver biochemical tests were normal.

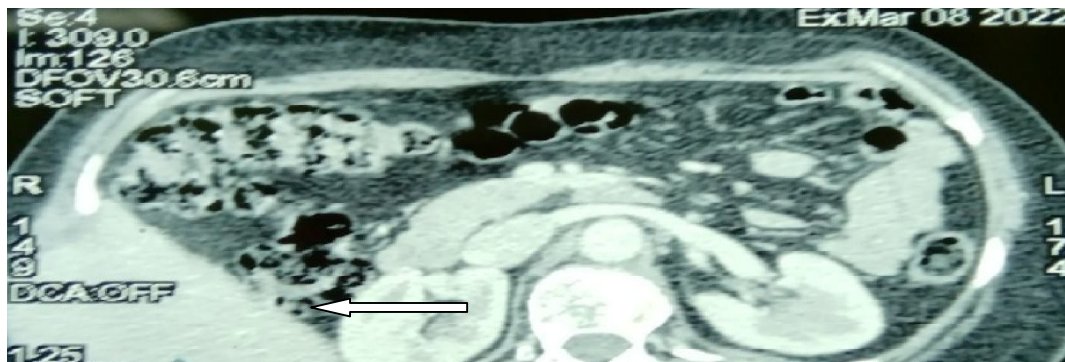


Figure 3 : CT scan showed a right lateral abdominal wall defect with hepatic content (arrow)

Surgery was scheduled, and an open midline incision approach was used to identify hepatoparietal adhesions released, with right lateral abdominal wall defect. The incisional hernia was repaired with the placement of an intraperitoneal PTFE (expanded polytetrafluoroethylene--Goretex Dual Mesh) measuring 15\*15 cm without tension.

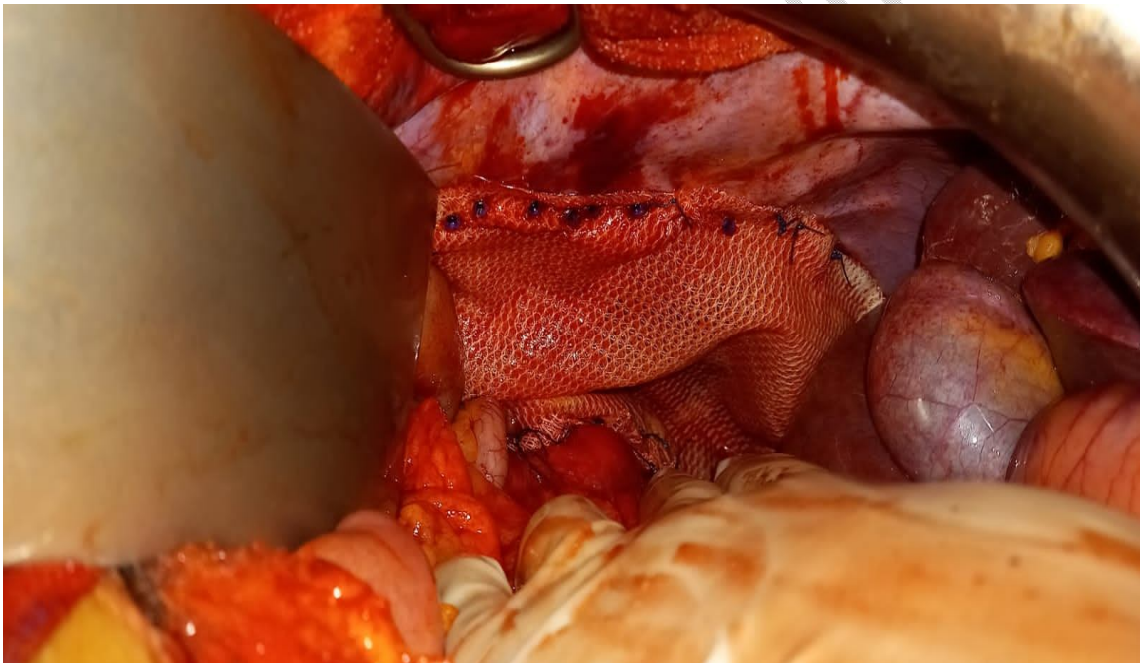


Figure 4 : the placement of an intraperitoneal PTFE

In view of the good post-operative evolution, the patient was declared discharged 2 days after surgery. 2 months later the patient underwent a routine follow-up examination, with better improvement.

## DISCUSSION :

Lumbar incisional hernia is a delayed complication of abdominal surgery and is defined as an acquired herniation of abdominal contents through a disrupted lumbar abdominal wall, often diffuse with defects which are generally difficult to appreciate (1). Of all acquired lumbar hernias, lumbar incisional hernias (LIH) account for 31% of etiologies (2).

After lumbotomy, the prevalence of LIH ranges from 10 to 35.3%, and decreases to 7% when an elective retroperitoneal approach is chosen (3). Because of its relative small prevalence, the surgical management of LIH is a challenge (4).

All case reports of hepatic hernias show a history of a prior major surgical procedure in the upper abdomen, such as our case.

Salemis et al. Presented a case of right lumbar incision hernia with herniation of the right lobe of the liver (5). Losanoff et al. Presented a case of recurrent intercostal herniation of the liver (6).

CT scan is the investigative modality of choice. It can provide detailed information on the extent of the lumbar defect and the presence of herniated abdominal viscera.

CT scan can also differentiate a hernia from muscle atrophy for which surgery is not recommended (7).

Until now, the approaches to repairing LIH described in the literatures have been varied, using a simple suture of the defect, with or without muscle plasty or plication of the normal fascia, or by a laparoscopic approach with different repair procedures (8).

Multiple repair techniques have been proposed. Reconstruction usually involves extensive dissection from the 12th rib to the iliac crest, followed by local flap mobilization, plication of normal fascia, or mesh placement. Others have advocated extensive retroperitoneal dissection with extraperitoneal placement of a large polypropylene sheet (8-9).

No procedure has been proven to have a clear advantage over the others, in light of the relative scarcity of these cases (9).

Our technique uses the same well described methods for laparoscopic lumbar incisional hernia repair using the dual mesh. However, due to the extent of the defect and the large volume of the enlarged right liver, which can impede the procedure, we chose the open approach and this gave good results.

## CONCLUSION :

Lumbar incisional hernias are rare and still difficult to manage. Computed tomography is the diagnostic method of choice and is recommended for any flank swelling on a history of lumbotomy, in order to differentiate a hernia from muscle atrophy without a fascial defect. Surgical management modalities are still poorly codified, with no precise recommendations, and this is probably due to the relative rarity of the cases

## REFERENCES

1. Abrahamson J. Mechanisms of hernia formation. In: Bendavid R, et al, eds. Abdominal Wall Hernias. New York: Springer; 2001:133-138.
2. Soto Delgado M, García Ureña MA, Velasco García M, Pedrero Márquez G (2002) Lumbar eventration as complication of the lumbotomy in the flank: review of our series. Actas Urol Esp 26:345-350
3. Moreno-Egea A (2007) Controversies in the current management of lumbar hernias. Arch Surg 142:82

4. Renard, Y., De Mestier, L., Cagniet, A., Demichel, N., Marchand, C., Meffert, J. L., ... & Palot, J. P. (2017). Open retromuscular large mesh reconstruction of lumbar incisional hernias including the atrophic muscular area. *Hernia*, 21(3), 341-349.
5. Salemis NS, Nisotakis K, Gourgiotis A, Tsohataridis E: Segmental liver incarceration through a recurrent incisional lumbar hernia. *Hepatobiliary Pancreat Dis Int* 2007; 6:442-444.
6. Losanoff JE, Richman BW, Jones JW: Recurrent intercostal herniation of the liver. *Ann Thorac Surg* 2004; 77:699-701.
7. Biswas S: Keddington J. Soft right chest wall swellings simulating lipoma following motor vehicle accident: transdiaphragmatic intercostal hernia. A case report and review of literature. *Hernia* 2008, 12:539-543.
8. Lichenstein IL. Repair of large diffuse lumbar hernias by an extraperitoneal binder technique. *Am J Surg*. 1986;151(4):501- 504.
9. Salameh, J. R., & Salloum, E. J. (2004). Lumbar incisional hernias: diagnostic and management dilemma. *JSL: Journal of the Society of Laparoscopic Surgeons*, 8(4), 391.