

# Synthetic Antimalarial Maculopathy: A case series

## Abstract :

Synthetic antimalarials (SAM) are drugs originally used for the prevention and treatment of malaria but, because of anti-inflammatory and immuno-modulatory activities, they have been since used to treat many other pathologies. Many side effects have been attributed to them, in particular ocular toxicity represented essentially by retinopathy or chloroquine maculopathy. This maculopathy is reversible if diagnosed at an early stage, hence the importance of early detection in patients on long-term SAM.

Our study consists of a retrospective study about fifteen patients followed for various pathologies and under long-term SAM. The study highlighted the modalities of monitoring patients, the need of the long term ophthalmological follow-up in order to detect a beginning retinal toxicity and reduce the dosage or even discontinue treatment depending on the risk-benefit ratio and possible therapeutic alternatives. An initial ophthalmologic clinical and paraclinical review must be performed before initiating treatment.

**Keywords :** maculopathy, synthetic antimalarials, monitoring, inflammatory diseases.

## Introduction

Synthetic antimalarials (SAM) are drugs originally used for the prevention and treatment of malaria. They demonstrated their effectiveness in certain rheumatological or dermatological pathologies such as rheumatoid arthritis (RA) and lupus.

Certainly, despite their great effectiveness, many side effects have been attributed to them, in particular ocular toxicity represented essentially by retinopathy or chloroquine maculopathy. This maculopathy is reversible if diagnosed at an early stage, hence the importance of early detection in patients on long-term SAM.

This imposes the need to establish a method of regular clinical and paraclinical monitoring.

Our study consists of a retrospective study about fifteen patients followed for various pathologies and under long-term SAM collected at the ophthalmology department A at the Specialty Hospital of Rabat over a period of 8 years.

## Case presentation

This is a retrospective study about 15 cases (5 men and 10 women), i.e. 30 eyes, collected in the Ophthalmology A department, at the Specialties Hospital in Rabat, over a period of 8 years from 2012 to 2019.

The patients were between 47 and 76 years old with an average age of 60 years. 8 were followed for Rheumatoid Arthritis (RA), 4 for Systemic Lupus Erythematosus (SLE) and 3 for various rheumatic pathologies, under long-term SAM (for at least 5 years): 3 under chloroquine CQ (Nivaquine®), 8 under hydroxychloroquine HCQ (Plaquénil®) and 4 patients took at course of treatment the two molecules.

Patients underwent a full ophthalmological examination. OCT-SD was performed for 8 patients, mfERG for 5 patients and angiography for 3 patients. For each patient, it was necessary to contact the attending physician in order to find the medication history of the person. For each notification, we collected data relating to: the subject (sex, age at the time of diagnosis, ATCD or associated defects), the antimalarial drug (SAM used, treatment indication, daily dose, cumulative dose, and duration of the treatment), the adverse effect (type of damage, time to onset, evolution) and the examinations carried out during the diagnosis.

Our study was about 15 patients, with a predominance of the female sex: 66.66% of women against 33.33% of men. Because of the high proportion pathologies that are predominantly female.

The average age of the subjects at the time of diagnosis was 60 years (extreme 47-76). Retinal lesions were diagnosed at around sixty years, which complicates the diagnosis of retinopathy. Indeed, ocular pathologies, such as cataracts or age-related macular degeneration AMD, are frequently associated at these ages.

The distribution according to pathology is as follows: eight patients had rheumatoid arthritis, which represents 53% of patients, 4 followed for lupus, two for inflammatory rheumatism and one patient for dermatomyositis. The study shows a clear predominance of two pathologies: rheumatoid arthritis and lupus.

Among these fifteen cases of retinal toxicity, 53% of the patients were treated with hydroxychloroquine (Plaquénil), 20% received chloroquine (Nivaquine), 26% were on chloroquine, and their prescribers replaced it with hydroxychloroquine. This distribution diverges with data from the literature where hydroxychloroquine was described as significantly less toxic than chloroquine. However, if these data are compared to the total prescriptions of hydroxychloroquine and chloroquine, chloroquine is prescribed significantly less.

The daily dosage is an important parameter used as a control rhythm criterion by considering it as the main risk factor in the occurrence of macular involvement. The average daily dose is 6.66 mg/kg/d for HCQ and 3.33 mg/kg/d for CQ. All the patients in our study were above the maximum dose not to be exceeded to reduce the risk of ocular complications by 6.5 mg/kg/d for HCQ and 3 mg/kg/d for CQ.

The cumulative dose is an essential element. Of course, it still depends indirectly on the daily dosage and the duration of the treatment. The duration of treatment varies from 5 to 12 years; two patients were under SAM for 5 years, the 13 other patients exceeded it. The cumulative dose varies from 219 to 438 g for CQ with an average of 358.91 g and from 438 to 1314 g for HCQ with an average of 839.5 g. It is admitted that a cumulative dose of 1000 grams of HCQ or 460 grams of CQ increases the risk of retinopathy (See below in discussion section)

There was a decrease in progressive visual acuity in five patients, seven patients were referred for ophthalmological control, and two patients were recruited for bilateral cataracts in whom the maculopathy was discovered incidentally. Data from the clinical examination reveal weak or even collapsed visual acuity in six patients and nine patients presented with difficulty reading (near vision). No corneal involvement was noted. A bilateral cataract was discovered in four patients, and two patients were already operated on for cataract.

Fundus examinations were normal in five cases, showed loss of foveolar reflex in three cases, alteration of the retinal pigment epithelium in five cases, and advanced maculopathy in two patients. Thus, half of the cases (50%) were diagnosed at the preclinical stage. Demonstration of these early perifoveolar abnormalities makes it possible to discontinue or even reduce the dosage (in agreement with the prescribing physician), and thus avoid progression to irreversible macular toxic damage. (Figure 1)

The visual field was normal in three cases, and revealed a paracentral scotoma in nine cases. One patient did not benefit from it due to lack of cooperation and was impossible to perform in two patients because the VA had collapsed. In our study, the examination of the visual field made it possible to evoke the diagnosis of retinopathy in 9 patients, which represents 60% of cases (Figure 2). Among the 15 cases, the OCT was abnormal for 4 cases (Figure3). The mfERG was considered uninterpretable in 2 patients (loss of fixation greater than 20%, interruption of the examination, background noise greater than 5 microvolts). It was positive in one case of IC or obvious maculopathy (Figure 4) and in 3 cases of IPC or maculopathy. Angiography makes it possible to visualize the attack on the level of the macula by areas of hypo fluorescence surrounded by areas of hyper fluorescence, characteristics of the image in "bull's eye". In our study, angiography was performed in 3 patients confirming the diagnosis of SAM's retinopathy.

The therapeutic decision was to stop the treatment in 6 patients, to reduce the dose for 6 patients, to make a therapeutic window for a single case and to replace the more toxic CQ by HCQ in 2 patients. The evolution was marked by the absence of aggravation of the lesions in 4 patients, an improvement in 5 patients, aggravation of the lesions in 2 patients, and 4 patients were lost to follow-up. Thus, our therapeutic decision was beneficial for 60% of patients.

## Discussion

SAM maculopathy is the most severe of the iatrogenic retinal toxicities. Its frequency in 2003 in France was estimated at 4.3% [1]. It is generally known that the use of CQ has a higher risk of retinopathy than with HCQ; this risk is estimated at 7.4%. [2].

The incidence of chloroquine retinopathy depends on several risk factors: maximal daily dose (5mg/kg of HCQ) [3], cumulative dose (>1000g) [4], duration of treatment (>5Years) [5], renal failure [6], genetic predisposition [7] and the use of tamoxifen [8]

The measurement of distance and near visual acuity after correction makes it possible to specify the degree of macular involvement. Careful and careful funduscopy examination of the central and peripheral retina and vasculature is important to detect maculopathy early [9]. There are typically two stages of development in retinopathy: the "preclinical" stage of intoxication, defined by asymptomatic foveolar involvement for the patient, associated with minimal parafoveal alterations on complementary examinations, without foveolar involvement and the "clinical" stage, defined by an alteration of the complementary examinations, causing irreversible visual functional symptoms (scotoma, visual blurring or loss of visual acuity) [10]. Early maculopathy or IPC consists of pigmentary formation of the macula and loss of the reflex of the fovea and obvious retinopathy or IC consists of hyperpigmentation of the macula, which is surrounded at the beginning by a clear zone of depigmentation then by a second ring of pigment, giving the appearance of a "bull's eye". [9]

The other similar retinopathies to the SAM toxicity are age-related macular degeneration (AMD), combined rod and cone dystrophy, classic cone dystrophy. Ceroid-lipofuscinosis of neurons, Stargardt's disease, fenestrated macular dystrophy and fundus Flavimaculatus [9].

Fluorescein angiography shows fluorescence in the macular area, may show macular lesions and identify changes in the retinal pigment epithelium and bull's eye maculopathy [2]. The central visual field examination is the most important examination for the early diagnosis. It reveals relative paracentral scotomas, which may be the first sign of macular toxicity in an asymptomatic patient. At a more advanced stage, an annular scotoma then a total central scotoma might be observed [11]. In multifocal ERG, it is the pericentral region that is initially affected, with a centrifugal progression first, then it generalizes; the results of mfERG in the most severe cases are immeasurable [12]. Typical paracentral amplitude depression was often present with a normal retinal appearance in all patients and sometimes with a normal VF

examination. This loss of amplitude may be associated with prolongations of latency of the central mfERG, when this association is present; it is very specific and characteristic of chloroquine toxicity [13]. With OCT, Chen and Al described three criteria of positivity, which are: an early alteration of the line of junction of the internal and external segments of the perifoveolar photoreceptors (ellipsoid zone); thinning of the perifoveolar outer nuclear layer with a flying saucer image, or intermediate stage; and at a later stage, foveolar atrophy [14]. According to the AAO, monitoring and screening for SAM toxicity is as follows: The baseline screening includes a fundus examination within first year of use, and, if a maculopathy is present, we can proceed to a central VF and SD OCT. The annual screening begins after 5 years of use or sooner in the presence of major risk factors [15]. The purpose of ophthalmological monitoring of long-term use of SAM is to highlight early changes in order to reduce the dosage or even discontinue treatment [9].

## Conclusion

Ophthalmological monitoring of patients on long-term MA must be regular, and adapted to each patient according to their level of risk. It remains the best way to avoid the installation of irreversible and blinding maculopathy.

### What is known about this topic

- An initial ophthalmologic clinical and paraclinical review must be performed before initiating treatment
- Ophthalmological monitoring of patients on long-term MA must be regular
- Retinal toxicity requires dosage reduction or even discontinue treatment depending on the risk-benefit ratio

### Study significance

- Ophthalmological monitoring of patients on long-term MA must be regular, and adapted to each patient according to their level of risk
- The full clinical and paraclinical assessment needed to a close follow-up
- Highlight early changes at the asymptotic stage in order to reduce the dosage or even discontinue treatment

## References

1. Neubauer AS, Samari-Kermani K, Schaller U, Welge-Lübetaen U, Rudolph G, Berninger T. Detecting chloroquine retinopathy: electro-oculogram versus colour vision. *Br J Ophthalmol* 2003; 87: 902-8.
2. JCS Yam, AKH Kwok. Ocular toxicity of hydroxychloroquine. *Hong Kong Med J*, vol 12; n°4; August 2006: 294-304.
3. Michael F. Marmor, MD, Ulrich Kellner, MD, Timothy Y.Y. Lai, MD, FRCOphth, Ronald B. Melles, MD, William F. Mieler, MD. Recommendations on Screening for Chloroquine and

Hydroxychloroquine Retinopathy (2016 Revision). *Ophthalmology* 2016; 123:1386-1394 for the American Academy of Ophthalmology.

4. S. Jaumouillé , D. Espargillière, F. Mouriaux, B. Mortemousque. Clinical evaluation of the new screening procedures for hydroxychloroquine retinopathy, according to the American Academy of Ophthalmology guidelines. Prospective study of 184 patients. *j.jfo*. 2015. 01.005
5. M. Labetoulle. Antipaludéens de synthèse : les conseils de l'American Academy of Ophthalmology. *J. Fr. Ophtalmo*, vol 26 ; n°3 ; 2003 : 319-21.
6. Browning DJ. Impact of the revised american academy of ophthalmology guidelines regarding hydroxychloroquine screening on actual practice. *Am J Ophthalmol* 2013; 155, 418.e1-28.e1.
7. Lee Y, Vinayagamoorthy N, Han K, et al. Association of polymorphisms of cytochrome P450 2D6 with blood hydroxychloroquine levels in patients with systemic lupus erythematosus. *Arthritis Rheumatol* 2016; 68: 184-90.
8. Melles RB, Marmor MF. The risk of toxic retinopathy in patients on long-term hydroxychloroquine therapy. *JAMA Ophthalmol* 2014; 132:1453–60.
9. Vanheesbeke A. Médicaments rétinotoxiques, rétine et épithélium pigmentaire: le point sur les APS. *Bull. Soc. Belge. Ophthalmol*; 304: 47-58. 2007.
10. Marmor MF, Carr RE, Easterbrook M, Farjo AA, Mieler WF, American Academy of Ophthalmology. Recommendations on screening for chloroquine and hydroxychloroquine retinopathy: a report by the American Academy of Ophthalmology. *Ophthalmology* 2002; 109:1377-82.
11. Hart WM, JR, Burde RM, Johnston GP. Static perimetry in Chloroquine retinopathy. Perifoveal patterns of visual field depression. *Arch Ophthalmol* 1984; 102: 377-80.
12. Penrose, Philip J, Tzekov, Radouil T, MD, PhD, Sutter, Erich E, PhD, Arthur. D, MD. Multifocal electroretinography evaluation for early detection of retinal dysfunction in patients taking Hydroxychloroquine. *Retina*, 2003; vol 23; 4: 503-12. 109
13. So SC, Hedges TR, Schuman JS, Quireza ML. Evaluation of Hydroxychloroquine retinopathy with mf electroretinography. *Ophthalmic Surg Lasers imaging*, 2003; 34: 251-8.
14. Chen E, Brown DM, Benz MS, Fish RH, Wong TP, Kim RY, et al. Spectral domain optical coherence tomography as an effective screening test for hydroxychloroquine retinopathy (the “flying saucer” sign). *Clin Ophthalmol* 2010; 4:1151-8.
15. Aduriz-Lorenzo PM, Aduriz-Llaneza P, Araiz-Iribarren J, Khamashta MA. Current opinion on hydroxychloroquine-related retinal toxicity screening: where do we stand now? *Lupus*. 2020 Jun;29(7):671-675. doi: 10.1177/0961203320919499. Epub 2020 Apr 21. PMID: 32316844.

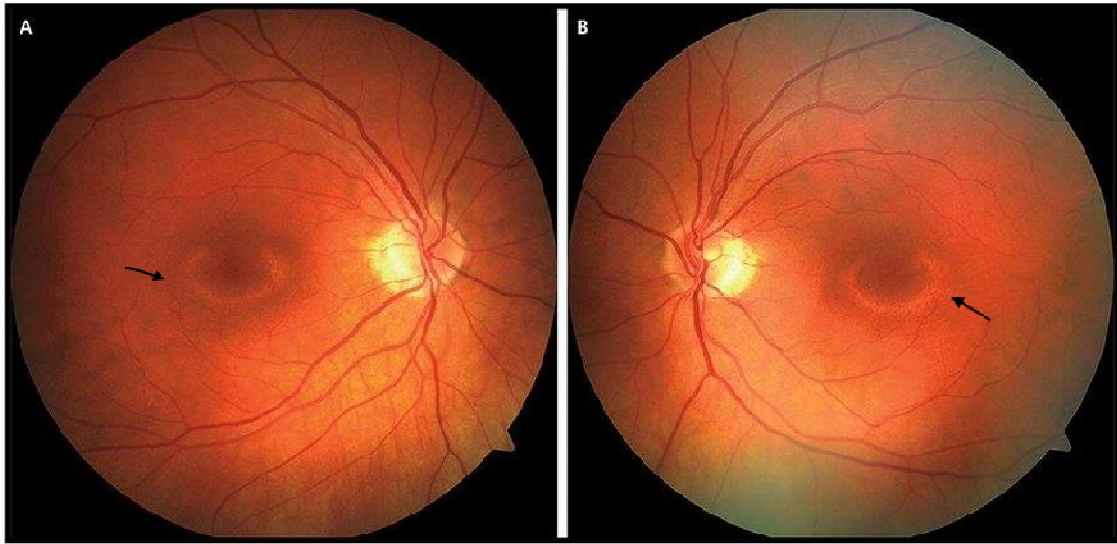


Figure 1: Fundus photo showing a paracentral annular depigmentation: bull's eye maculopathy (black arrows)

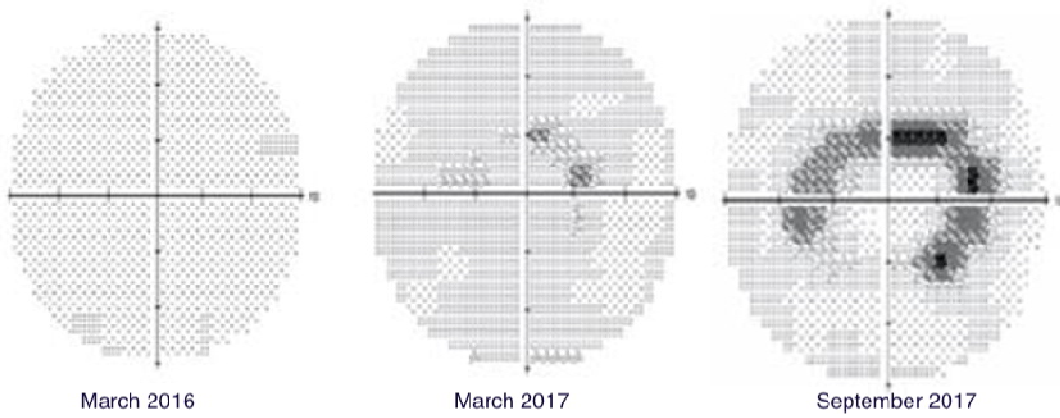


Figure 2: Humphrey visual field (10:2): evolution of paracentral scotomas in a patient under SAM

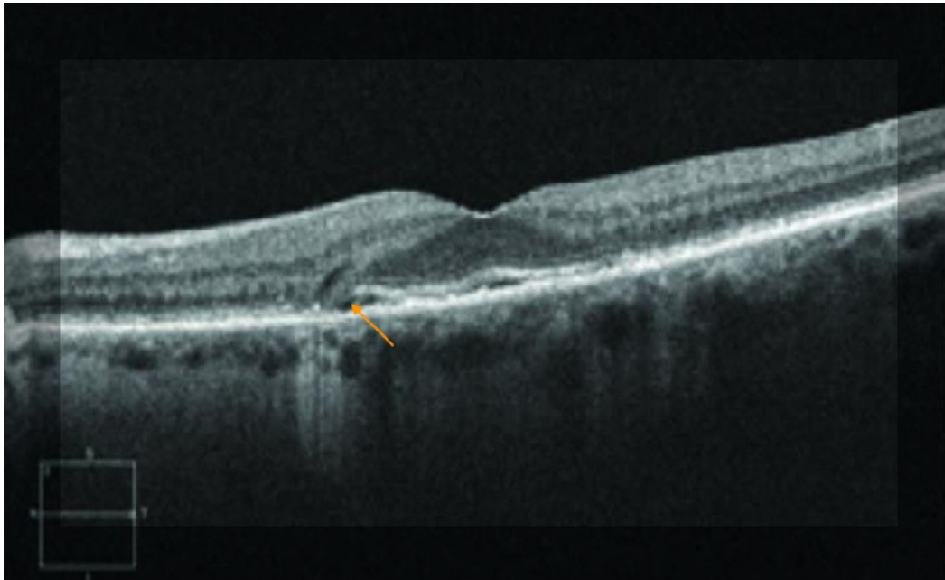


Figure 3: Macular thinning in addition to a break in the integrity line of the photoreceptors or ellipsoid line. (orange arrow)

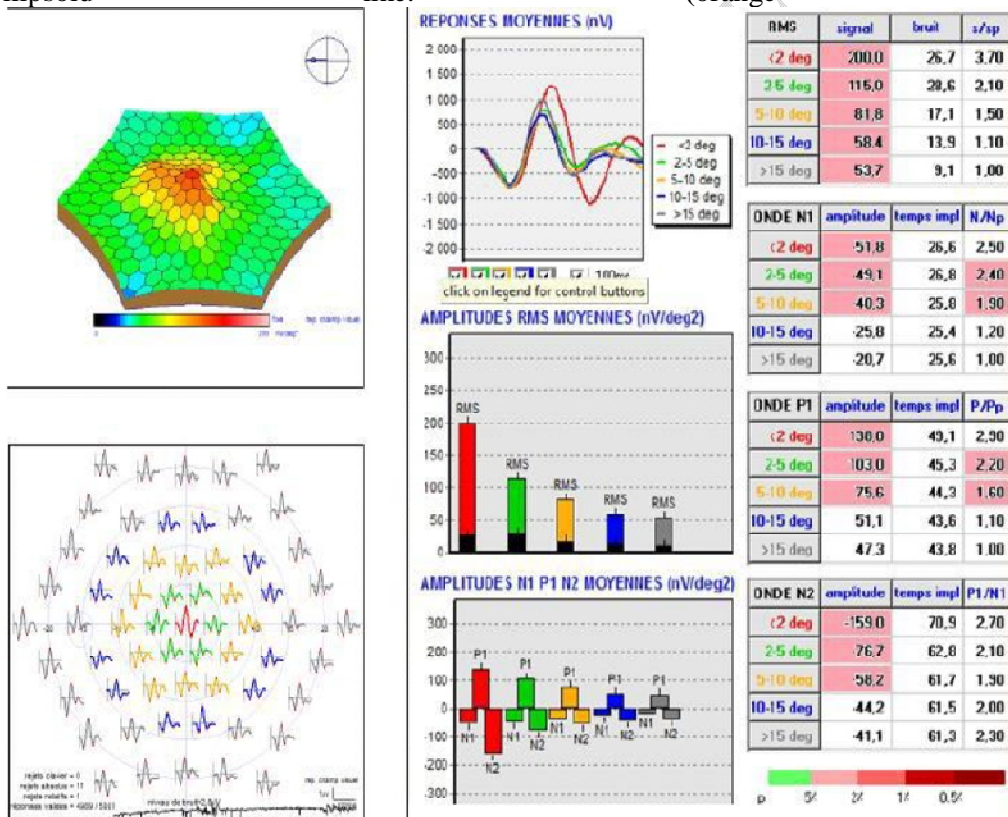


Figure 4 : Multifocal ERG of a patient treated with HCQ, the amplitude of N1P1 is reduced. The P1/N1 amplitude ratio (similar to the ratio B/A in classic ERG) remains normal.