

## Case study

### Sigmoidorectal intussusception associated with duodenal GIST

**ABSTRACT:** Sigmoido-rectal intussusception is rare and the lead point can be in most of the time a malignant lesions like adenocarcinoma. An 86-year-old patient was admitted to the emergency room for rectal bleeding associated with mucous diarrhea. Computed tomography revealed sigmoid-rectal invagination associated with a jejunal stromal tumor. The patient underwent a colon-rectal resection carrying a colon-rectal invagination and a colostomy was performed. Biopsies were taken of a mass in the 4th duodenum, an epiploic nodule, a mesenteric nodule, and a liver nodule.

**KEYWORDS:** Sigmoido-rectal intussusception, colorectal cancer, sigmoid adenocarcinoma, duodenal GIST.

#### INTRODUCTION:

Intestinal intussusception is rare in adults, accounting for approximately 1% of all intestinal obstructions<sup>1</sup>. Symptoms in adults are most often chronic or non-specific such as nausea, vomiting, digestive hemorrhage, transit disorders, and abdominal distension. However, computed tomography is the most sensitive diagnostic modality<sup>2</sup>. This article presents a case of a patient with sigmoido-rectal intussusception associated with adenocarcinoma and a duodenal GIST.

#### CASE PRESENTATION:

An 86-year-old patient, who had undergone a prostatectomy for prostate cancer and having as a comorbidity, diabetes, well controlled on insulin, was admitted to the emergency room for rectal bleeding associated with mucous diarrhea. These symptoms had been present for 20 days in a context of a deteriorating general condition.

On admission, the patient was conscious, hemodynamically and respiratory stable, with discolored conjunctivae. Abdominal examination revealed a midline laparotomy scar below the umbilicus, with a distended, tympanic, painful abdomen and the presence of a palpable mass on the left flank, measuring 7 cm on the long axis, fixed to the deep plane. On digital rectal examination did not reveal a palpable mass. The thoraco-abdomino-pelvic scanner revealed an irregular rounded tissue mass taking contrast in the periphery with central necrosis measuring 8 cm in diameter. Jejunal stromal tumor in Figure 1, Sigmoido-rectal invagination in Figure 2.

The patient underwent a colo-rectal resection carrying a colo-rectal invagination with colostomy in double gun barrel. Biopsies were taken from a mass in the 4th duodenum, an epiploic, a mesenteric and a liver nodule. During exploration: presence of a medium-abundance serous effusion (sampled), presence of sigmoidorectal intussusception with colonic distension at 7 cm with no sign of pain "Figure 3", presence of a mass of 12 cm of long axis at the anti-mesenteric edge of the 4th duodenum suggesting a GIST (biopsy done) and presence of nodule of carcinomatosis at the entire peritoneal cavity (biopsy of a nodule done) "Figure 4" with the liver being filled with metastases (biopsy also performed).

On pathological examination:

- Biopsies of the mesenteric, omental nodule, and liver deposits showed morphological and immunohistochemical aspects consistent with a secondary localization of a gastrointestinal stromal tumor (GIST) at high risk of recurrence.
- Biopsy of the duodenojejunal junction mass: Morphological and immunohistochemical aspect of a gastrointestinal stromal tumor (GIST).
- Colorectal intussusception resection: Moderately differentiated and invasive NOS type adenocarcinoma on top of a tubule-villous adenoma

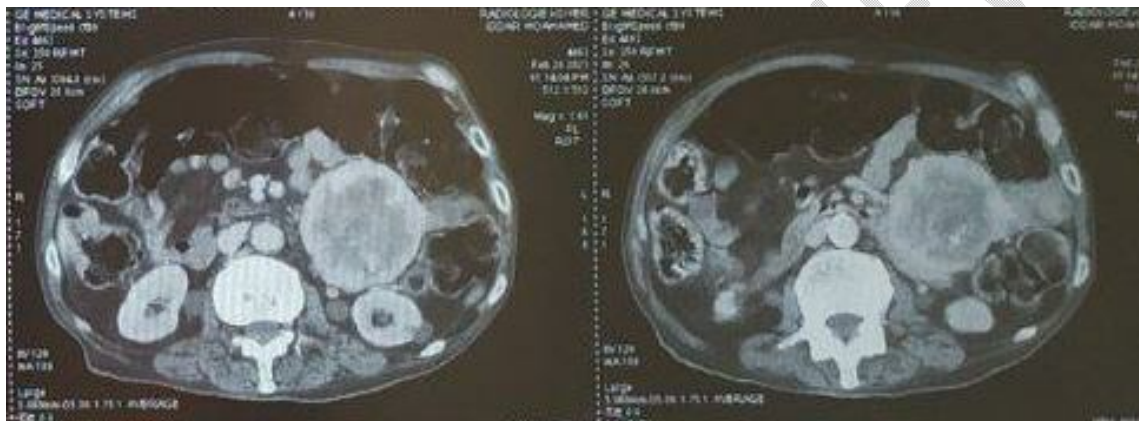


Figure 1 :CT image of the stromal mass

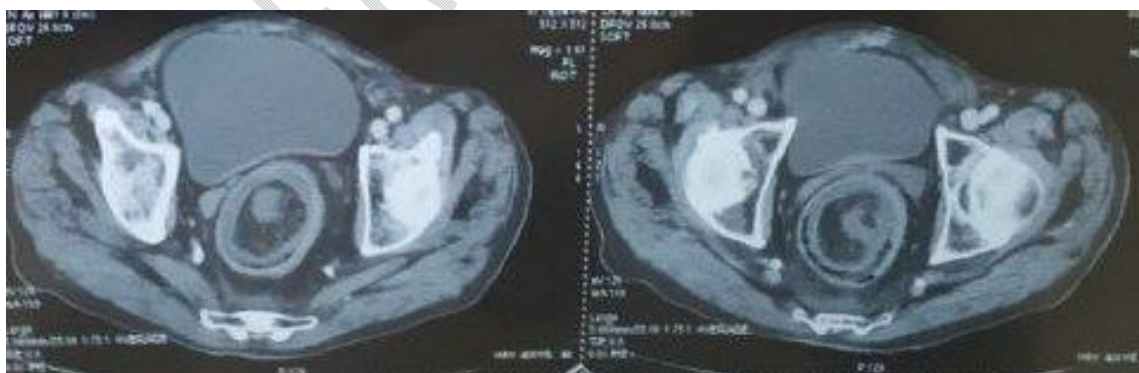


Figure 2: CT image of sigmoidorectal intussusception

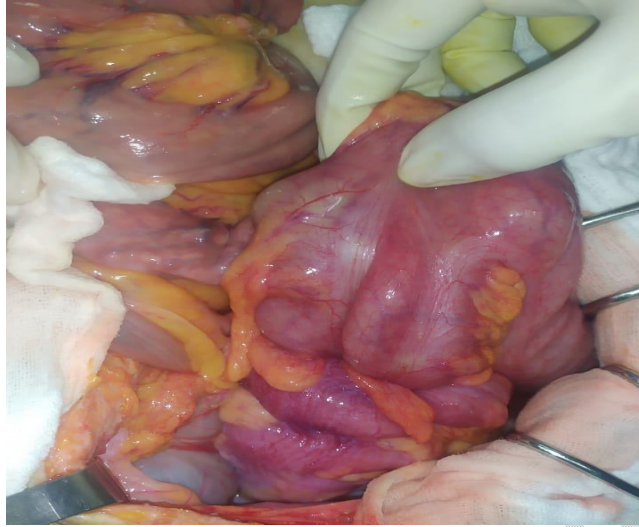

Figure 3: per-operative image of sigmoidorectal intussusception

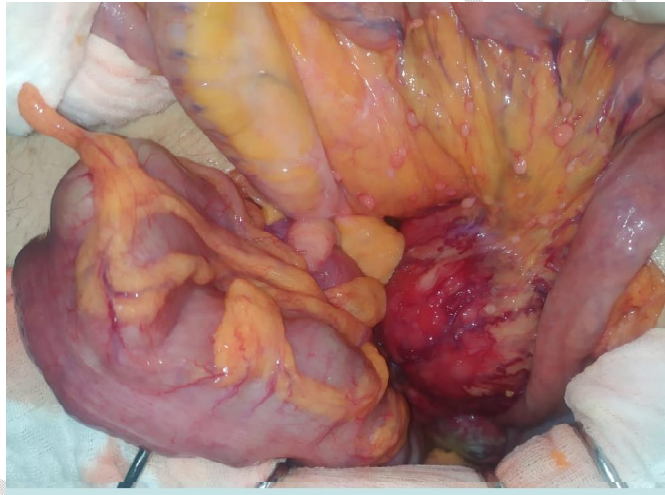


Figure 4: per-operative image of duodenal mass and carcinomatous nodules

## II. DISCUSSION

Adult intussusception is rare, less than 5% of all cases of intussusception and 1–3% of intestinal obstruction <sup>3</sup>.

Malignant lesions like adenocarcinoma, lymphoma and metastasis, is in more than half of them the cause <sup>4</sup>.

Intussusception consists on the invagination of a proximal segment of bowel into an adjacent distal segment. The lead point can be a lesion in the bowel wall or an irritant in its lumen

that may change the normal peristaltic pattern and initiate the invagination leading to intussusception. In other cases, it can be primary idiopathic intussusception when there is no lead point and is interesting in the small intestine<sup>3,5</sup>.

The non-specific clinical presentation leads to a diagnostic dilemma. The paraclinical examinations are represented by plain abdominal X-rays, demonstrating signs of intestinal obstruction and the probable site of obstruction<sup>6</sup>.

CT as a useful imaging modality for diagnosing intussusception, shows the so-called bowel-within-bowel configuration, in which the layers of the bowel are duplicated forming concentric rings, when imaged at right angles to the lumen, and a soft tissue sausage when imaged longitudinally. The mesentery (fat and vessels) will form a crescent of tissue around the compressed innermost lumen, surrounded by the two layers of the outer enveloping bowel<sup>7,8</sup>.

Adult intussusception is treated almost always surgically. The reduction should be avoided and a resection without reduction (en bloc resection) should be done to prevent disseminating malignant cells when an underlying malignancy is suspected, knowing that almost 50% of both colonic and enteric intussusceptions are associated with malignancy. In other words, the advantage of reduction, especially in the small bowel, is preservation of considerable lengths of the bowel development of short bowel syndrome<sup>5,9,10, 11</sup>.

Gastrointestinal stromal tumors (GISTs) are the most common mesenchymal tumors of the gastrointestinal tract<sup>12</sup>.

Defined as KIT (CD117) positive and derived from the interstitial cells of Cajal or their precursors, the tumor can be located anywhere in the gastrointestinal tract. The duodenum is a rare site accounting in 4%–5%, contrary to the stomach that constitutes the most common site, followed by the jejunum and ileum<sup>13</sup>.

The GIST can be associated with another malignant tumor in 4.5% to 35% of cases. The most frequently associated tumors with the GIST are gastrointestinal adenocarcinoma, prostatic adenocarcinoma, lymphoma, leukemia and breast cancer and their discovery in few cases in on the CT used as part of the extension study of the adenocarcinoma<sup>14, 15</sup>.

The localization of the two tumors can be on the same, or different parts of the gastrointestinal tract. Like our case and frequently, the association is of a colic adenocarcinoma and a small bowel GIST<sup>16</sup>.

Hypothesis such as the same carcinogen that induces simultaneous proliferation of different cell lines can explain this association but a further investigation is needed<sup>17, 18, 19, 20, 21</sup>.

In conclusion, adult intussusception is a rare cause of intestinal obstruction, most often caused by malignant lesions. The non-specific clinical presentation explains that the diagnosis is evoked on an imaging modality “the CT”. The association between the gastrointestinal adenocarcinoma and the GIST suggests the existence of a relation between the carcinogenesis pathways of the two lesions.

#### IV. REFERENCES

1. Azar T and Berger DL. Adult intussusception. *Ann Surg* 1997; 226(2): 134–138.
2. Yakan S, Caliskan C, Makay O, Denecli AG, Korkut MA. Intussusception in adults: clinical characteristics, diagnosis and operative strategies. *World J Gastroenterol* 2009; 15:1985-9.
3. P.A. Ongom, S.C. Kijjambu, Adult intussusception: a continuously unveiling clinical complex illustrating both acute (emergency) and chronic disease management, *OA Emergency Med.* 1 (August 01 (1)) (2013) 3.
4. Mazumdar et al. *Egyptian Journal of Radiology and Nuclear Medicine* (2021) 52:34
5. S S. Yalarmathi, R.C. Smith, Adult intussusception: case reports and review of literature, *Postgrad. Med. J.* 81 (2005) 174–177.
6. Somma F, Faggian A, Serra N et al (2015) Bowel intussusceptions in adults: the role of imaging. *Radiol Med* 120(1):105–117
7. Kim YH, Blake MA, Harisinghani MG et al (2006) Adult intestinal intussusception: CT appearances and identification of a causative lead point. *Radiographics.* 26(3):733–744
8. Choi S, Han J, Kim S et al. Intussusception in Adults: From Stomach to Rectum. *AJR Am J Roentgenol.* 2004;183(3):691-8. doi:10.2214/ajr.183.3.1830691
9. Azar T, Berger DL. Adult intussusception. *Ann. Surg.* 226 (1997) 134–138.
10. D.G. Begos, A. Sandor, I.M. Modlin, The diagnosis and management of adult intussusception, *Am. J. Surg.* 73 (1997) 88–94.
11. M.N. Khan, A. Agrawal, P. Strauss, Intussusception—a rare cause of acute intestinal obstruction in adults: case report and literature review, *World J. Emerg. Surg.* 3 (26) (2008).
12. Joensuu H, Fletcher C, Dimitrijevic S, et al. Management of malignant gastrointestinal stromal tumours. *Lancet Oncol* 2002;3(11):655–64.
13. Miettinen M, Lasota J. Gastrointestinal stromal tumors: Pathology and prognosis at different sites. *Semin Diagn Pathol* 2006;23(2):70–83.
14. Anis H, Selma K, Amine S, Houcine M, Montassar K. Gastric synchronous stromal tumor and adenocarcinoma: A fortuitous association? *J Clin Exp Pathol.* 2017;7(4):1000320.
15. Yan Y, Li Z, Liu Y, Zhang L, Li J. Coexistence of gastrointestinal stromal tumors and gastric adenocarcinomas. *Tumor Biol.* 2013 Apr;34(2):919-27.
16. Chiu H, Huang T, Liu Y, Ko T, Lu N. Synchronous ileal stromal tumor (GIST) and colonic adenocarcinoma. *J Intern Med Taiwan.* 2009;20:260-3.
17. Chen C, Castellanos M, Ruch M, Hsu Y. Gastrointestinal stromal tumor with synchronous colorectal adenocarcinoma. *QJM Int J Med.* 2017;110(9):591-2.
18. Chiu H, Huang T, Liu Y, Ko T, Lu N. Synchronous ileal stromal tumor (GIST) and colonic adenocarcinoma. *J Intern Med Taiwan.* 2009;20:260-3.
19. Khoshnevis J, Rakhshan A, Sobhiyeh M, Gholizadeh B, Rahbari A, Adhami F et al. Simultaneous gastric adenocarcinoma and gastrointestinal stromal tumor of the stomach: a case report. *Iran J Cancer Prev.* 2013;(1):55-8.
20. Kaur R, Bhalla S, Nundy S, Jain S. Synchronous gastric gastrointestinal stromal tumor (GIST) and other primary neoplasms of gastrointestinal tract: report of two cases. *Ann Gastroenterol.* 2013;26(4):356-9.
21. Gavriilidis P, Nikolaidou A. Colon adenocarcinoma associated with synchronous extramural gastrointestinal stromal tumor (GIST) of the ileum. *Am J Case Rep.* 2015;16:837-389.