

Cystic intestinal pneumatosis simulating hollow organ perforation peritonitis: a case report

Abstract : Cystic pneumatosis of the intestine is a rare condition whose incidence is often underestimated due to the frequency of pauci symptomatic or asymptomatic forms.

Primary forms are even less common and account for only 15% of all retained cases of this disease.

Peptic ulcers and pyloric stenosis are the most frequently incriminated aetiologies in the pathophysiology of the secondary form of cystic pneumatosis.

We describe the case of a 60 year old patient, admitted with generalized abdominal pain complicated by the appearance of mental confusion.

Clinical examination found a Glasgow score of 13/15 with generalized abdominal sensitivity. Biological findings: hyperleukocytosis at 22370 /mm, C-reactive protein was elevated at : 73.7 mg/L.

The CT scan revealed gastric and duodenal thickening associated with a medium-sized pneumoperitoneum, which could be related to peritonitis due to perforation of a hollow organ. Cerebral level: Minimal meningeal haemorrhage from the brain scythe and cerebellum tent.

Surgical exploration showed the appearance of cystic intestinal pneumatosis without digestive distress and without solution of continuity of a hollow organ.

KEYWORDS: cystic intestinal pneumatosis, pneumoperitoneum, anaerobic, peptic ulcer perforation peritonitis.

INTRODUCTION: Cystic intestinal pneumatosis is one of the rare etiologies of pneumoperitoneum, the diagnosis of which is frequently made intraoperatively by the discovery of multiple cystic intestinal lesions without interruption of parietal continuity of a hollow organ.

It is a rare pathology, but it exposes a double diagnostic problem: aetiological and differential with other causes of pneumoperitoneum and intestinal pneumatosis, notably peritonitis by digestive perforation and acute mesenteric ischaemia, which require recourse to surgical treatment in extreme urgency.

CASE REPORT:

It was a 60 year old patient, chronic smoker at 40 PA presented for generalized abdominal pain evolving since two days complicated by the appearance of a disorder of conscience has type of mental confusion.

Clinical examination found a confused patient Glasgow 13/15 , BP : 110/070 mmHg , HR : 20 CPM , HR : 84 BPM , T°37 C with generalized abdominal sensitivity

The rectal examination was without anomaly. The blood count showed a hyperleukocytosis of 22370 /mm with a high C-reactive protein of 73.7 mg/L

The CT scan showed a medium-sized pneumoperitoneum in the supra-mesocolic area of the abdomen. There was significant gastric and duodenal mucosal thickening with sub mucosal oedema and contrast after injection of PDC. Concluding that the appearance is in favour of peritonitis due to peptic ulcer perforation.

On the cerebral level, there is minimal meningeal haemorrhage from the brain scythe and cerebellum tent.

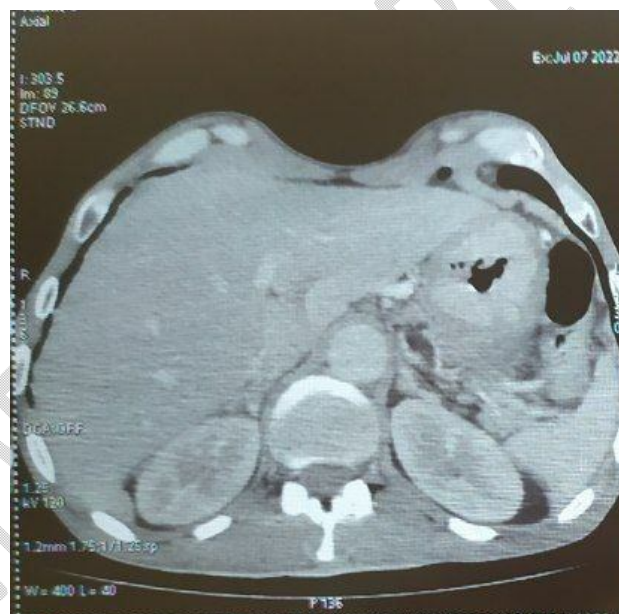

Fig. 1: Axial slides of abdominal CT scan a pneumoperitoneum

Surgical exploration showed the appearance of cystic intestinal pneumatosis without digestive distress and without continuity of a hollow organ or other associated lesion.

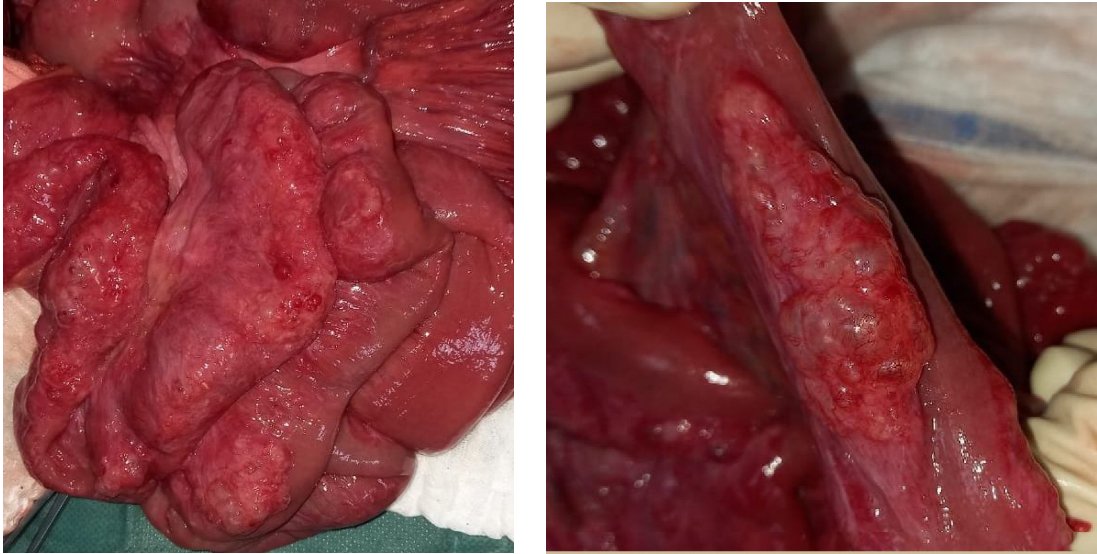


Fig. 2 and 3: Peroperative images showing. a Cystic intestinal pneumatosis

II. DISCUSSION

Cystic intestinal pneumatosis is a rare cause of pneumoperitoneum and is defined by the development of multiple cystic lesions in the intestinal wall [1].

It is a benign disease with a better prognosis, but its aetiology is still poorly understood at present [2].

However, many theories have been proposed to explain the pathophysiology of this condition, of which the mechanical theory is predominant, associating the presence of an obstacle to intestinal transit with ulceration of the digestive mucosa [3.4].

Therefore, the medical theory of anaerobic germs associated with damage to the digestive mucosa has also been described and forms the basis for conservative treatment with metronidazole. [5]

Schematically, cystic intestinal pneumatosis can be divided into two subgroups:

Secondary forms, where a digestive or extra-digestive pathology is retained as an etiological factor responsible for the development of parietal cystic lesions, represent 85% of PKI.

Thus, chronic inflammatory bowel disease, peptic ulcer disease, pyloric stenosis, chronic obstructive pulmonary diseases are the most frequently encountered aetiology

Primitive or idiopathic forms when no underlying causes can be determined [6.7].

Clinically, cystic pneumatosis is often asymptomatic or even minimally symptomatic [8].

The revealing clinical manifestation is mainly represented by abdominal pain, diarrhoea and more rarely rectal bleeding.

It should be noted that the diagnosis of PKI is made in the majority of cases only intraoperative for other surgical emergencies, notably hollow organ perforations.

Abdominal CT with contrast injection represents the gold standard in the diagnosis of PKI, its sensitivity being better than standard imaging. By analysing the radiological lesions, it allows the semiological criteria to be met, thus allowing the diagnosis of PKI to be retained and other surgical causes of pneumoperitoneum and parietal pneumatosis to be ruled out, in particular perforations of hollow organs and mesenteric ischemia [9.10].

As for the treatment, the conservative attitude with a well codified medical treatment is the rule; it aims at eradicating the anaerobic germs incriminated in the development of the cystic lesions by an antibiotic therapy based on metronidazole more or less associated with a hyperbaric oxygen therapy [11.12.13].

The indication for surgical resection of the pathological intestinal segment is limited to complicated forms and symptomatic forms with failure of well-managed medical treatment.

III. CONCLUSION

Cystic Intestinal Pneumatosis is a benign condition with an often favourable prognosis, but which poses a real problem of confusion with surgical emergencies retained as a cause of pneumoperitoneum.

Computed tomography with intravenous injection of iodine has considerably modified the therapeutic approach to a clinical suspicion of intestinal Pneumatosis by the meticulous analysis of the different radiological signs, thus limiting the iterative recourse to an often useless exploratory laparotomy.

IV. REFERENCES

- [1] C. Laclotte-Duhoux, M.-A. Bigard, Pneumatose kystique intestinale, EMC - Gastro-Entérologie 5 (3) (2010) 1–8, janv.
- [2] Barge J, Vinceneux P. Pneumatose kystique intestinale. Presse Med 1998, 27: 1804-12.
- [3] C.W.Y. Wong, P.H.Y. Chung, K.K.Y. Wong, P.K. Tam, Pneumatosis intestinalis presenting as pneumoperitoneum in a teenage girl with pyloric stenosis, BMJ Case Rep. (2015) [Internet]. 26 févr. [cité 11 juill 2020]; 2015. Disponible sur: <https://www.ncbi.nlm.nih.gov/pmc/articles/PMC4342669/>.
- [4]. Cherbonnel G, Fall B. Les pneumatoses kystiques intestinale. A propos de 2 cas. Chirurgie. 1998, 114, 89-95.
- [5]. Levitt MD, S Olsson. Pneumatosis cystoides intestinalis and high breath H2 excretion: insights into the role of H2 in this condition. Gastroenterology. 1995; 108(5): 1560-1565. This article on PubMed

- [6]. Heng Y, MD Schuffler, RC Haggitt, and CA Rohrmann. Pneumatosis intestinalis: a review. *Am J Gastroenterol.* 1995; 90(10): 1747-1758. This article on PubMed
- [7]. Grasland A, J Pouchot, J Leport, J Barge, and P Vinceneux. Pneumatosis cystoides intestinalis. *Presse Med.* 1998; 27(35): 1804-1812. This article on PubMed
- [8] B. Hicham El, Abdelmalek, B. El Bachir, M. Karim Ibn, M. Khalid, T. Khalid Aït, Pneumatose kystique iléale révélée par un volvulus du grêle, *Pan Afr. Med. J.* 6 (2010) [Internet]. 12 août [cité 12 juill 2020]. Disponible sur: <https://www.ncbi.nlm.nih.gov/pmc/articles/PMC3063497/>
- [9] K. Wada, N. Takeuchi, M. Emori, M. Takada, Y. Nomura, A. Otsuka, Two cases of pneumatosis cystoides intestinalis with intraperitoneal free air, *Gastroenterol. Res.* 10 (3) (2017) 208–211.
- [10]. Pun YL, DM Russell, GJ Taggart, and DR Barraclough. Pneumatosis intestinalis and pneumoperitoneum complicating mixed connective tissue disease. *Br J Rheumatol.* 1991; 30(2): 146-149. This article on PubMed
- [11] H. Pülat, G. C, elik, M.Z. Sabuncuoglu, ~ M.F. Benzin, O. Karaköse, R. C, etin, Pneumatosis cystoides intestinalis: a rare cause of intraabdominal free air, *Turk. J. Surg.* 33 (4) (2015) 315–317, 14 juill.
- [12] P. Devgun, H. Hassan, Pneumatosis cystoides intestinalis: a rare benign cause of pneumoperitoneum, *Case Rep. Radiol.* 2013 (2013) 1–3
- [13] P. Guillem, Radiologic pneumoperitoneum without perforation of a hollow viscus, *J. Chir. (Paris)* 139 (1) (2002) 5–15, févr.