

## **Unusual clinical presentation of cutaneous squamous cell carcinoma: a retrospective study in Al Baha region, Southern Saudi Arabia**

### **Abstract:**

Cutaneous squamous cell carcinoma (cSCC) is the second most common non-melanoma skin cancer, and it accounts for 20% of all skin cancers. It occurs typically on parts of the skin exposed to sunlight and begins as tender erythematous papules or nodules that enlarge over a period of months in most cases. This study investigates the unusual presentation of cSCC with the goal of raising awareness of rare presentations and promoting accurate diagnostic tools. It is a five-year retrospective study retrieving patient data to study the demographic, clinical and histological features of cSCC with unusual presentations that were clinically unsuspected. It was carried out in Al Baha Province, southern Saudi Arabia. A total of 25 cases were included; males predominated (60%), and the mean age of the cohort was 59.8 years. However, three patients were <50 years old and the most prevalent site of the cSCC was the nose. Tumor size ranged from 5 to 50 mm with a mean size of 14.6 mm. Tumor size was uncorrelated with a clinical suspicion of malignancy. The clinical presentation of cSCC varies from tan nodules in most cases (28%) to warty lesions in 4% of cases; the clinical diagnosis of such lesions also varied from highly malignant lesions (melanoma) to a simple inflammatory disease. Histologically, most cases (96%) were keratinizing squamous cell carcinomas. A clinical suspicion of cSCC is not always accurate, and histopathology is the most accurate tool for diagnosis. Abdominal wall, perianal and finger sites are not immune to cSCC, and young individuals are also at risk.

**Keywords:** squamous cell carcinoma, basal cell carcinoma, actinic keratosis, keratinizing

## Introduction

Cutaneous squamous cell carcinoma (cSCC) is a **malignant neoplasm** of the epidermal keratinocytes that exhibits rapid, uncontrollable growth, histological anaplasia, local invasion, and the ability to spread to other parts of the body. Based on ultraviolet exposure and skin type, the prevalence of cSCC varies around the world [1].

Globally, the prevalence of cSCC is rising, particularly among Caucasian populations; the number of cases is anticipated to reach 1 million each year in the United States. In the past three decades, the incidence of cSCC has risen from 50% to 300% [2].

The primary and most prevalent risk factor for cSCC is chronic sun exposure. An older age, a male sex, a previous history of actinic keratosis, fair skin and immunosuppression are also known risk factors. Solid-organ transplant recipients who have chronic lymphocytic leukemias or human papillomavirus (HPV) infections are at greater risk than the general population [3].

A major risk factor for developing invasive cSCC is actinic keratosis, which is considered a premalignant lesion [4]. Patients under the age of 40 are rarely affected by cSCC; the disease typically affects older men between their fifth and eighth decades of life [5].

Cutaneous squamous cell carcinoma can develop anywhere on the human body, but most often occurs on the sun-exposed areas, as well as head and neck including ears, cheeks, lips and nose which is recorded as the predominant site of this cancer [6].

According to several studies, the location of the primary tumor has a significant predictive factor for cSCC metastasis. Tumors of Lip and ear have a higher chance of metastasis (14% and 9%, respectively), compared to other sun-exposed areas [7].

Squamous cell carcinomas of the skin typically begin as tender erythematous papules or nodules over the skin, which may be surmounted by a hyperkeratosis and some producing keratotic horns. The lesion enlarges over a time period of months in most cases and becomes increasingly tender and even painful. Recurrent skin ulcerations and bleeding may develop, and some tumors—particularly those on the scalp and lower extremities—may present as an ulceration without pre-existing nodules or surrounding induration.

This study investigates the unusual presentation of cSCC lesions in clinical presentations. The goal of this work is to raise clinicians' awareness of rare or atypical presentations and the importance of accurate diagnoses of this highly malignant skin cancer.

## Materials and Methods

All cases of cSCC in medical files from the dermatology and surgery department in addition to pathology archives at our hospitals, were retrieved after obtaining approval from the relevant bioethics committee. The following patient data were reviewed: age, sex, clinical presentation (only the primary clinical presentation), first clinical suspicion diagnosed by the physician, duration of the lesion prior to management, tumor site, tumor location and recurrence status. **All patients with insufficient clinical or histological data were included in the excluding criteria. Tables with the acquired data were then imported into Excel spreadsheets for analysis.**

The cases were categorized as large or small cases based on tumor size in accordance with staging defined by the American Joint Committee on Cancer's (AJCC) seventh edition:

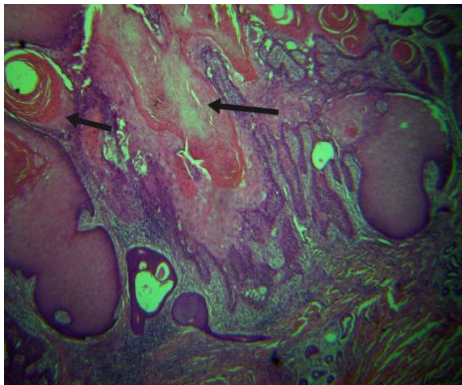
- pT1: A tumor with a diameter less than 2 cm and the presence of fewer than two high-risk factors.
- pT2: A tumor with a diameter 2 cm or more and the presence of two or more high-risk factors\*.

pT3: A tumor that has invaded the maxilla, orbit, mandible, or temporal bone.

pT4: A tumor that has invaded the skeleton axially or appendicularly.

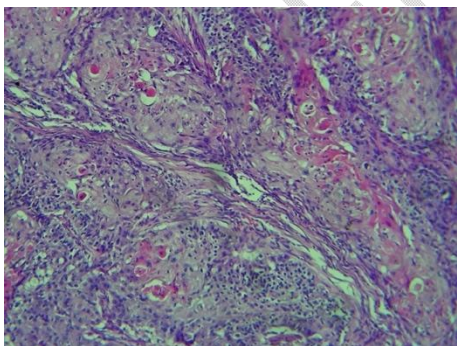
\* High-risk factors include tumors with a thickness greater than 2 mm, Clark levels of IV or V, poor or undifferentiated tissue, perineural invasion, and locations on the lip or ear.

Tumor grading was implicated based on the degree of differentiation and keratinization [8]. Squamous epithelium, obvious intercellular bridges, an abundance of keratinization, little pleomorphism, and basally positioned mitotic figures were all taken as signs of well-differentiated tissue (Figure 1A).



**Figure 1A: A case of well-differentiated cSCC exhibiting many pearls of keratin (arrows) (H&E stain, 40x)**

Keratinization is prominent, and features can be distinguished that range from moderately differentiated to poorly differentiated. Poorly differentiated features exhibit little to no keratinization and have obvious nuclear atypia (Figure 1B).



**Figure 1B: A case of moderately differentiated cSCC showing malignant squamous cells and a reduced amount of keratin (H&E stain, 200x)**

### Statistics

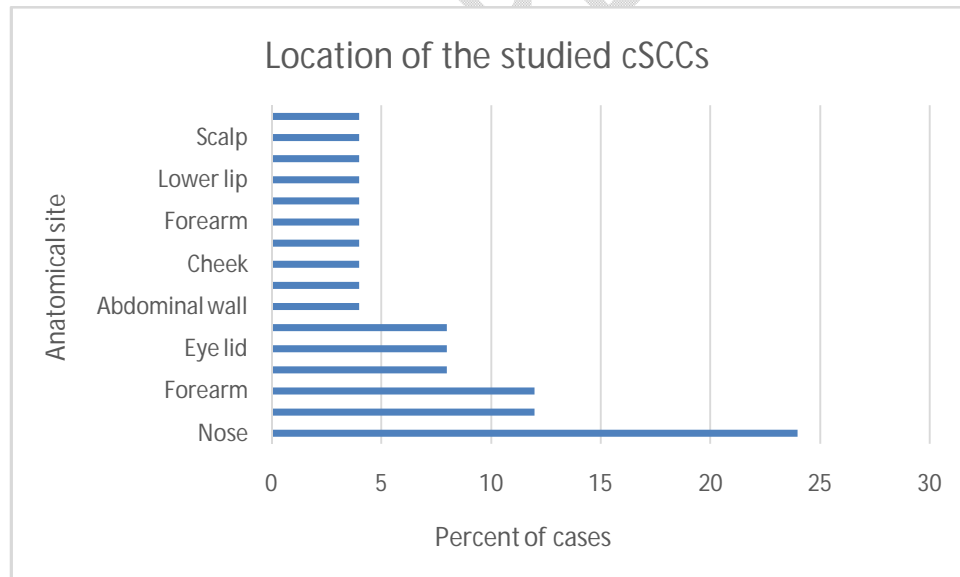
Excel software (Microsoft Corporation; Redmond, Washington, USA) was used to manage the data. Patient age, tumor size, and duration in months were recorded as a mean and standard deviation. All of the descriptive variables were given computed frequencies and percentages. Statistical significance was defined as a P-value of 0.05 or less. The kappa test was used to statistically evaluate the interrater reliability of the final pathological diagnosis and the clinical diagnosis.

## Results

A total of 25 cases were included in this study; 15 patients (60%) were male, and 10 patients (40%) were female. The mean age of the cohort was 59.8 years. The most prevalent tumor site was the nose (24% of unusually presented cases); however, one case (4%) was recorded for each of the following sites: the scalp, the lower lip, the forearm, the cheek and abdominal wall skin (Figure 2). Tumor size ranged from 5 to 50 mm with a mean size of  $14.6 \pm 10.7$  mm.

The clinical presentation of cSCC in this study varied from tan nodules in most cases (28%) to verruca-like warty lesions in 4% of cases. The clinical diagnosis of such lesions also varied from highly malignant lesions other than cSCC (particularly melanoma) to simple inflammatory diseases. Histologically, most of the cases (96%) were keratinizing squamous cell carcinomas; a keratin material was observed in most cases. However, the tumor grade and stage differed among cases (Table 1).

To examine the relationship between cSCC size and clinical suspicion of benign vs. malignant status, we statistically compared the groups. We did not find any significant differences between tumor size and suspicion of malignancy in cases with unusual presentations (Table 2).



**Figure2: Distribution of cases as a function of anatomical site.**

**Table1:** Clinico-pathological characteristics of the tumors in the study.

Characteristic	N (25)	%
<b>Age (years)</b>		
Mean $\pm$ SD	59.8 $\pm$ 13.6	
Range	36-99	
<50 years old	3	12
>50 years old	22	88
<b>Sex</b>		
Male	15	60
Female	10	40
<b>Primary clinical presentation</b>		
Tan nodule	7	28
Pigmented nodule	3	12
Ulcer	12	48
Induration	2	8
Warty	1	4
<b>Pain</b>		
Painful	3	12
Painless	22	88
<b>Tumor size</b>		
<20mm	21	84
>20mm	4	16
<b>Clinical diagnoses</b>		
Chronic wound	6	24
BCC	5	20
Melanoma	2	8
Nevus	2	
Wart	2	8
Chronic abscess	1	4
Scar	1	4
Adnexal tumor	1	4
Chronic solar dermatitis	1	4
Seborrheic keratosis	1	4
Chronic infection	1	4
Granuloma	1	4
Benign nodule	1	4
<b>Tumor histological grade</b>		
Well differentiated (G1)	16	64
Moderately differentiated (G2)	8	32
Poorly differentiated (G3)	1	4
<b>Tumor Invasion</b>		
Dermis	23	92
Subcutaneous fat	2	8

**Table 2:** Tumor size as a potential factor for clinical suspicion of benign versus malignant cases

<b>Suspected benign versus malignant cases</b>			
	N (25)	%	Mean tumor size (mm)
Malignant skin cancer	7	28	13.3
Benign lesion	18	72	14.5
<b>P-value</b>	>0.05		

## Discussion

Cutaneous squamous cell carcinoma, also known as keratinocyte carcinoma, is the second most frequent type of non-melanoma skin cancer. According to a recent study of Medicare fee-for-service patients, basal cell carcinoma BCC and SCC are equally common, despite the fact that cSCC has historically accounted for 20% of all skin malignancies. [9].

The Mayo Clinic's Rochester Epidemiology Project data revealed a 263% increase in the prevalence of cSCC between 1976–1984 and 2000–2010. Higher rates were observed as a result of the growth of the aging population and a greater focus on cancer screening [3].

The main risk factors for cSCC among elderly individuals include sun exposure, cigarette use, and alcohol addiction, which have a powerful synergistic effect [10].

Although young people often have reduced exposure to these significant risk factors, it is unclear what influence these risk factors have in young patients. In recent decades, the incidence of cSCC has increased in people under the age of 50 [11,12].

This study included three male patients younger than 50 but no female patients under the age of 50. A male patient, 36 years old, came to the clinic with a skin nodule and clinically suspected Seborrheic keratosis. A biopsy revealed squamous cell carcinoma (keratinizing). Furthermore, two patients, both 45 years old, were seen with unusual presentations. The first patient presented a nodular lesion on their nose that was clinically suspected to be BCC. However, an unexpected squamous cell carcinoma invading the dermis up to the subcutaneous fat layer was found. The second patient exhibited an unhealed wound in the perianal area, which biopsied and diagnosed as cSCC. Such a clinical presentation is unusual not only its site but also for the age of the patient. Previous studies of rare cases of cSCC have reported few cases in the perianal area; some of these cases aroused suspicion of hidradenitis suppurativa. However, hidradenitis suppurativa can occur in association with fistulas but rarely occurs with cSCC, which is uncommon at that site [13,14].

Ultraviolet radiation is one of the primary environmental risk factors for cSCC. Several studies have noted that the head and neck are common locations for cSCC [15].

Cutaneous squamous cell carcinoma on sun-protected areas are uncommon, but some authors have reported lesions in unusual sites [16].

Here we found two cSCC in the perianal site, one case on a finger, one lesion on the back and one case on the skin of the abdominal wall.

Some previous studies have reported cSCC on the abdominal wall on top of non-carcinogenic materials [17].

The most prevalent clinical diagnosis for unusual cSCCs in our case was BCC. Squamous cell carcinoma and BCC are the most common cancer types in humans, and they can be easily confused in regards to their clinical and histological features. Translucency, ulceration, pigmentation, telangiectasias, and a rolling border are characteristics that indicate BCC rather than cSCC. However, because both types of skin cancer frequently develop in people who are exposed to the sun, it can be challenging to correctly diagnose these conditions [18].

The clinical presentation of cSCC varies from skin induration, nodules, ulcerations, unusual pigmentation and warty lesions similar to verrucas. In rare incidences, cSCC may masquerade as a verruca, and an accurate diagnosis is crucial to prevent the spread of the cancer and ensuing complications [19].

We studied the histological grade and tumor invasion of the included lesions; determining the degree of cSCC differentiation is essential for proper diagnosis and prognosis. The majority of cases in this study corresponded to grade 1 (i.e., the cells were well differentiated); more than 75% of differentiated tumor cells are grade 1. As a result of the small number of patients in this study, we did not evaluate the predictive potential of the tumor grade in connection to anatomical site or clinical presentation.

## Conclusions

Cutaneous squamous cell carcinoma has a significant tendency to be misdiagnosed as BCC and, to a lower extent, as melanoma or a benign lesion such as a chronic infection, an adnexal tumor, nevus or even chronic dermatitis. Histopathological examination is the primary diagnostic tool for cSCC. The most affected anatomical site is the nose; however, the abdominal wall, perianal skin and other sun-protected areas can be affected as well. Skin indurations should be taken seriously in clinical examination as they might indicate a high-risk squamous cell carcinoma. Additional studies, focused on genetic differentiation of the different varieties of cSCC, are recommended given that lesions in sun-protected areas and lesions in young patients are both increasing in prevalence.

## Ethical approval

The Prince Meshari Bin Saud General Hospital's Research Ethics Committee provided ethical approval for this study (reference number PMS0230401).

## Data and materials availability

The corresponding author will provide all data sets collected for this work upon reasonable request.

## References

- 1- Baloglu, H, Dogan, B. An unusual presentation of primary cutaneous squamous cell carcinoma. *Journal of the European Academy of Dermatology and Venereology* 2003; 17(5): 556–8. doi:10.1046/j.1468-3083.2003.00629.x
- 2- Corchado-Cobos R, García-Sancha N, González-Sarmiento R, et al. Cutaneous squamous cell carcinoma: from biology to therapy. *International Journal of Molecular Sciences*. 2020; 21(8):2956. <https://doi.org/10.3390/ijms21082956>
- 3- Que SKT, Zwald FO, Schmults CD. Cutaneous squamous cell carcinoma: incidence, risk factors, diagnosis, and staging. *J. Am. Acad. Dermatol* 2018; 78: 237–47.
- 4- Ahmady S, Jansen MH, Nelemans PJ, et al. Risk of invasive cutaneous squamous cell carcinoma after different treatments for actinic keratosis: a secondary analysis of a randomized clinical trial. *JAMA dermatology* 2022;158(6):634–40.
- 5- Randhawa T, Shameena P, Sudha S, Nair R. Squamous cell carcinoma of tongue in a 19-year-old female. *Indian J Cancer* 2008;45:128–30.
- 6- Gurudutt VV, Genden EM. Cutaneous squamous cell carcinoma of the head and neck. *J Skin Cancer*. 2011;2011:502723. doi: 10.1155/2011/502723. Epub 2011 Feb 21. PMID: 21461387; PMCID: PMC3064996.
- 7- Cheng J, Yan S. Prognostic variables in high-risk cutaneous squamous cell carcinoma: a review. *Journal of cutaneous pathology* 2016;43(11):994–1004.
- 8- Cañueto J, Burguillo J, Moyano-Bueno D, et al. Comparing the eighth and the seventh editions of the American Joint Committee on Cancer staging system and the Brigham and Women's Hospital alternative staging system for cutaneous squamous cell carcinoma: implications for clinical practice. *J Am Acad Dermatol* 2019;80(1):106-113.e2. doi: 10.1016/j.jaad.2018.06.060.
- 9- Rogers HW, Weinstock MA, Feldman SR, Coldiron BM. Incidence estimate of nonmelanoma skin cancer (keratinocyte carcinomas) in the U.S. population, 2012. *JAMA Dermatol*. 2015;151(10):1081–6. doi: 10.1001/jamadermatol.2015.1187. PMID: 25928283.
- 10- Kaur J, Singh A, Chopra R. Unusual presentation of squamous cell carcinoma in young female patient: a case report and review of literature. *J Oral Maxillofac Pathol*. 2016;20(1):163. doi: 10.4103/0973-029X.180984.
- 11- Monteiro LS, Amaral JB, Vizcaíno JR, et al. A clinical-pathological and survival study of oral squamous cell carcinomas from a population of the north of Portugal. *Med Oral Patol Oral Cir Bucal*. 2014;19:e120–6.
- 12- Santos HB, dos Santos TK, Paz AR, et al. Clinical findings and risk factors to oral squamous cell carcinoma in young patients: a 12-year retrospective analysis. *Med Oral Patol Oral Cir Bucal*. 2016;21(2):e151–6. doi: 10.4317/medoral.20770.
- 13- Kohorst JJ, Shah KK, Hallemeier CL, et al. Squamous cell carcinoma in perineal, perianal, and gluteal hidradenitis suppurativa: experience in 120. *Dermatol Surg* 2019;45(4):519–26. doi: 10.1097/DSS.0000000000001713.
- 14- Hegab AM, Baheeg M, Shehata MS, et al. Long-term outcome of ligation of intersphincteric fistula tract (LIFT) for management of trans-sphincteric anal fistula.

International Journal of Surgery Open 2022;41:100461.

<https://doi.org/10.1016/j.ijso.2022.100461>

- 15- Kim Y, Feng J, Su KA, Asgari MM. Sex-based differences in the anatomic distribution of cutaneous squamous cell carcinoma. *International Journal of Women's Dermatology* 2020;6(4):286–9. <https://doi.org/10.1016/j.ijwd.2020.05.008>
- 16- Rogers HW, Weinstock MA, Harris AR, et al. Incidence estimate of nonmelanoma skin cancer in the United States, 2006. *Arch Dermatol* 2010;146:283–7
- 17- Birolini C, Minossi JG, Lima CF, et al. Mesh cancer: long-term mesh infection leading to squamous-cell carcinoma of the abdominal wall. *Hernia* 2014; 18L: 897–901  
<https://doi.org/10.1007/s10029-013-1083-x>
- 18- Ryu TH, Kye H, Choi JE, et al. Features causing confusion between basal cell carcinoma and squamous cell carcinoma in clinical diagnosis. *Annals of dermatology*. 2018;30(1):64–70. <https://doi.org/10.5021/ad.2018.30.1.64>
- 19- Cohen PR, Erickson CP, Calame A. Cutaneous Squamous Cell Carcinoma Masquerading as a Verruca: Case Report and Literature Review of Coexisting Wart and Invasive Squamous Cell Carcinoma on the Hand. *Cureus*. 2022 Dec 11;14(12):e32408. doi: 10.7759/cureus.32408. PMID: 36636549; PMCID: PMC9831616.

UNDER PEER REVIEW