

# Potential of *Pterocarpuserinaceus* aqueous stem bark extract to prevent oxidative kidney damage in diabetic rats.

## ABSTRACT

Diabetes is a chronic, metabolic disease characterized by elevated levels of blood glucose, which over time leads to serious damage to the heart, blood vessels, eyes, kidneys and nerves. This present studies investigated the potential of *Pterocarpuserinaceus* of aqueous stem bark extract to prevent oxidative kidney damage in diabetic rats. Thirty six (36) male wistar rats of 100 to 200g were used in this study. Diabetes mellitus was induced by injecting alloxan at the dose of 150mg/kg body weight and aqueous extract of *Pterocarpuserinaceus* stem bark at doses of 100, 200 and 400mg/kg b.wt were administered orally for 14 days. Blood glucose level and oral glucose tolerance test was determined. At the end of the experiment, the serum, kidney tissue and kidney homogenate were obtained for the determination of kidney function parameters, histology, lipid peroxidation, antioxidant and inflammation markers. Phytochemical results shows the presence of phenols, tannins, saponins, alkaloids, glycosides, cardiac glycosides and flavonoides. Diabetic rats administered with *Pterocarpuserinaceus* aqueous stem bark extract showed significant ( $P < 0.05$ ) decrease in, blood glucose, creatinine, blood urea nitrogen (BUN), potassium, MDA, TNF-alpha, IL-6 and TGF- $\beta$  when compared with diabetic control rats. Also a non significant ( $P > 0.05$ ) decrease in uric acid, albumin, and an increase in sodium, GSH when compared with the diabetic control group. A significant ( $P < 0.05$ ) increase was observed in SOD, CAT, GPx, and GST when compared with diabetic control rats. The kidney histostructure was also protected. Thus, from this study the aqueous extract of *Pterocarpuserinaceus* stem bark exhibited significant antihyperglycemic, improvement in kidney indices, antioxidant and anti inflammatory properties and prevented kidney tissue damage in alloxan-induced diabetic rats which might be useful for diabetes mellitus patients.

*Keywords.* Alloxan, anti inflammatory, antioxidant, Diabetes mellitus, Kidney, *Pterocarpuserinaceus*.

## 1. INTRODUCTION

Diabetes mellitus (DM) is a metabolic syndrome, characterised by chronic hyperglycaemia and glucose intolerance because of defects in insulin secretion, action, or a combination of both [1]. It is a chronic metabolic disorder that leads to long-term complications affecting some tissues such as heart, kidney, retina, and peripheral nerves. Diabetic nephropathy (DN) is one of the most serious complications of diabetes and the most common cause of end-stage renal failure characterized by specific renal morphological and functional alterations and reactive oxygen species (ROS) play an important role in high glucose induced renal injury [2]. Oxidative stress is induced by the imbalance of reactive oxygen species generation and endogenous antioxidant activity. This ROS elicits inflammatory signalling pathways which in turn induces oxidative stress and inflammation which are main causes for DN [3]. In humans, diabetic nephropathy manifests as a clinical syndrome consisting of albuminuria, a progressive decline in renal function. Previous studies have shown that hyperglycemia-induced oxidative stress contributes significantly to kidney injury. This fact is given credence by the observation that attenuation of oxidative stress in Alloxan induced diabetic rats prevent diabetic nephropathy [4]. *Pterocarpuserinaceus* Poir. (*P. erinaceus*) from the Fabaceae is a medicinal plants traditionally used to treat several diseases including diabetes mellitus [5]. It is popularly known as, African rosewood, African kino, or teak (in English). In Northern Nigeria it is called "madobiya", "sha jinni", "banuhi", "zanchi" while in the South, it is called "apepe", "era", "osundudu" or "upeka" [6].

The aim is to determine the potential of *Pterocarpuserinaceus* aqueous stem bark extract in preventing oxidative kidney damage in diabetic rat.

## 2 MATERIALS AND METHODS

### 2.1 Plant Sample Collection and Extraction

The stem bark *Pterocarpuserinaceus* was collected from Gudi, Akwanga local Government, Nasarawa State, Nigeria and taxonomically identified and authenticated by department of Plant science and Biotechnology, Faculty of Science, Nasarawa University Keffi, Nigeria. The plant was washed, shade dried for 30 days and then reduced to powder form using mortar and pestle. Maceration method was used according to [7]. Five hundred grams (500 g) of the pulverized *Pterocarpuserinaceus* stem bark was soaked in 2500 ml of the extracting solvent (hot water) in the ratio of 1g of sample to 5ml of (i.e. 1:5) and stirred for few minutes, it was allowed to stand at room temperature for 48 hours with occasional agitation to increase penetration of solvent to the active compounds, after which the mixture was filter with muslin cloth (folded twice). The filtrates was then concentrated using water bath, dispensed in a glass bottle and stored in the refrigerator.

## 2.2 Phytochemical Screening

The qualitative phytochemical screening was carried out according to the methods as described by Vishnu et al [8].

### 2.3: Radical DPPH Scavenging Assay

The DPPH free radical scavenging assay was performed according to [9]. Two hundred (200  $\mu$ L) of 0.1 mM DPPH prepared in methanol was added to 100  $\mu$ L of the plant extract. The resulting mixture were incubated at room temperature in the dark for 15 minutes. Absorbance was observed at 517 nm. The experiment was carried out in triplicates and percentage inhibition of the DPPH radical scavenging activity was calculated.

% Inhibition =  $((A_0 - A_1) / A_0) \times 100$  where  $A_0$  is the absorbance of the control (ascorbic acid) and  $A_1$  is the absorbance of the sample.

## 2.4 Acute Oral Toxicity Studies

The Lorke's method was used to determine the acute toxicity. This method has two phases. Phase 1 involves nine rats of three rats per group. they were administered *Pterocarpuserinaceus* orally at the dose of 10, 100 and 1000 mg/kg. second phase involving three rats of one rat per group were given 1600, 2900 and 5000 mg/kg.b.w of the extract. Animals were kept under close observation for 24 hours in each phase and then observed for any change in the general behavior and/or physical activities; mortality was recorded within 48 hours [10].

## 2.5 Experimental Animals

Thirty six (36) male albino wistar rats weighing 100-200 g were used in the study. They were purchased from University of Jos. they were housed 6 rats per cage and allow acclimatization to laboratory condition for one week before the beginning of experiments according to Al-Fartosy [11]. Animals were maintained at room temperature and with a 12h light/12h dark cycle and allowed *ad libitum* access to feed and water.

## 2.6 Induction of Diabetes Mellitus

Diabetes was induced by an intraperitoneal injection of 150 mg/kg single dose of alloxan dissolved in normal saline. The animals were fasted for twelve hours before alloxan was injected. They were left for 72 hours (3 days) for diabetes to develop, after which blood glucose level were again determined to ascertain that the rats were diabetic. Rats with fasting blood glucose  $\geq 200$  mg/dl were included in the study and randomized to different groups [12]. Also glucose level were checked weekly till the end of the experiment.

## 2.7 Experimental Protocol

Six groups with six rats in each group received the following treatment schedule:

Group A (Normal control): Rats given only feeds and water

Group B (Diabetic control): Diabetic rats + feed and water

Group C: (Positive control): Diabetic rats + 25mg/kg b.wt Vit C

Group D: Diabetic rats + 100mg/kg b.wt of extract + feed and water

Group E: Diabetic rats + 200mg/kg b.wt of extract + feed and water

Group F: Diabetic rats + 400mg/kg b.wt of extract + feed and water

## **2.8 Fasting blood glucose determination**

Tail tips of the rats were pricked to obtain blood for FBG determination. This was carried out using glucometer (ACCU CHEK) [13]. The fasting blood glucose level was done 72 hours after injection and then weekly till the end of the experiment.

## **2.9 Oral Glucose Tolerance Test (OGTT)**

The OGTT was carried out on the 14<sup>th</sup> day of the experiment. Overnight fasted rats were orally administered with glucose (2 g/kg body weight) 30 mins after extract/ drug administration. Blood samples were collected from tail vein at 0, 30, 60, 90, and 120 min after glucose administration for immediate measurement of blood glucose levels.

## **2.10 Biochemical investigation**

At the end of 14 days, the animals were fasted overnight (12hrs) and were euthanized and dissected. Whole blood obtained by cardiac puncture into non-heparinized tubes were allowed to clot for 1h, 30mins and afterwards centrifuged (4000g for 10mins) to remove cells and recover serum for the biochemical assays. Serum uric acid was determined using the method of Barham and Trinder [14], Serum Creatinine was determined using the method of Bartels and Bohmer [15]. The method of Fawcett and Scott [16] was used to determine blood urea nitrogen. Sodium was determined using the method as described by Maruna; Trinder [17; 18], potassium was determined with the method of Tietz, [19]. The method of Grant et al., [20] was used to determine serum albumin.

## **2.11 Preparation of kidney homogenate**

The kidney were removed immediately after sacrifice, trimmed and rinsed with isotonic saline, minced and a homogenate was prepared with 10% (w/v) phosphate-buffered (0.1 M, pH 7.4) using a homogenizer. The kidney homogenate was centrifuged and the supernatant was used to estimate the following parameters: Malondialdehyde (MDA) as described by Buege & Aust, [21] superoxide dismutase (SOD) by the method of Sun & Zigman [22], Catalase (CAT) as described by Sinha, [23], Reduced glutathione (GSH) by the method of Sedlak & Lindsay [24], Glutathione peroxidase (GPx) as described by Ursini et al., [25], Glutathione transferase (GST) using the method of Habig et al., [26]. The levels of inflammatory cytokines (serum TNF- $\alpha$  and IL-6 and TGF- $\beta$ ) were also measured using commercially ELISA kits as per manufacturer's instructions.

## **2.12 Histopathology Test**

The kidneys were collected and washed with normal saline and preserved in 10% buffered formalin. The tissues then trimmed into sections, processed, and embedded in paraffin. Five microns thickness sections of the kidney were cut, stained with haematoxylin and eosin (H and E) and observed under the microscope [27].

## 2.13 Statistical Analysis

Data were analyzed using Statistical Package for the Social Sciences (SPSS) Version 25 and presented as mean  $\pm$  SD of triplicate determinations. Multiple group comparisons were performed using LSD test following one-way analysis of variance (ANOVA) in order to detect intergroup differences. Significant differences were expressed as  $p < 0.05$ .

## 3 RESULTS AND DISCUSSION

### 3.1 RESULTS

#### 3.1.1 Phytochemical Analysis

Phytochemical screening of *Pterocarpuserinaceus* stem bark shows the presence of phenols, tannins, saponins, alkaloids, glycosides, cardiac glycosides and flavonoides.

**Table 1: Phytochemical analysis of aqueous extract of *Pterocarpuserinaceus* stem bark**

Phytochemicals	Qualitative composition
Phenols	+
Tannins	+
Saponins	+
Alkaloids	+
Glycosides	+
Terpenoids	-
Cardiac glycosides	+
Steroids	-
Phlobatannins	-
Flavonoids	+
Anthroquinones	-

All values represent Mean  $\pm$ SD (n=3).+ means presence while – means absence

#### 3.1.2 DPPH radical scavenging activity of aqueous extract of *Pterocarpuserinaceus* stem bark

Table 2 shows the DPPH radical scavenging activity of the aqueous extracts of *Pterocarpuserinaceus* stem bark and standard ascorbic acid (AA). *Pterocarpuserinaceus* possessed the higher activity (93.14  $\pm$  0.46 %, 82.35 $\pm$ 0.92%) at a concentration of 300  $\mu$ g/ml and 400  $\mu$ g/ml when compared with the standard ascorbic acid(AA) which was 90.79  $\pm$  0.23% and 91.91 $\pm$ 0.45% at the same concentrations.

**Table 2: DPPH radical scavenging activity of aqueous extract of *Pterocarpuserinaceus* stem bark**

Concentration $\mu$ g/ml	% inhibition <i>Pterocarpuserinaceus</i>	% inhibition Ascorbic acid
--------------------------	--	----------------------------

100	32.35 ± 0.46	86.63±0.23
200	23.86±1.39	87.75±0.23
300	93.14±0.46	90.79±0.23
400	82.35±0.92	91.91±0.45

All values represent Mean ±SD (n=3)

### 3.1.3 Effect of aqueous extract of *Pterocarpuserinceus* stem bark on oral glucose tolerance test (OGTT)

Oral glucose tolerance test as presented in Table 3 after the glucose load, showed that the mean blood glucose level increased up to 30 mins in all groups. It then started decreasing progressively up to 120 mins in groups C, D, E and F. Group B continued to increase from 30mins up to 120 mins. There was a significant ( $p < 0.05$ ) increase in group B glucose level when compared with group A (normal control). Also a significant ( $p < 0.05$ ) decrease was observed with groups C, D, E and F when compared with group B (diabetic control).

**Table 3: Effect of aqueous extract of *Pterocarpuserinceus* stem bark on oral glucose tolerance test (OGTT) on 14<sup>th</sup> day of experiment in mg/dl.**

Groups	0hr	30min	60min	90min	120min
A	71.10±2.70 <sup>b</sup>	125.100±8.10 <sup>b</sup>	105.100±4.30 <sup>b</sup>	119.70±0.90 <sup>b</sup>	106.20±9.00 <sup>b</sup>
B	304.20±5.40 <sup>a</sup>	451.20±4.52 <sup>a</sup>	450.00±7.20 <sup>a</sup>	514.80±3.60 <sup>a</sup>	516.60±3.60 <sup>a</sup>
C	121.50±4.50 <sup>ab</sup>	405.00±16.20 <sup>a</sup>	297.00±5.40 <sup>ab</sup>	237.60±8.25 <sup>ab</sup>	162.00±16.20 <sup>b</sup>
D	118.80±14.40 <sup>ab</sup>	272.40±88.79 <sup>ab</sup>	263.40±67.11 <sup>ab</sup>	236.40±76.79 <sup>ab</sup>	143.40±50.47 <sup>b</sup>
E	114.30±2.70 <sup>ab</sup>	339.30±114.30 <sup>a</sup>	260.10±99.90 <sup>ab</sup>	213.30±45.90 <sup>ab</sup>	131.40±1.80 <sup>b</sup>
F	85.20±11.71 <sup>b</sup>	396.60±49.37 <sup>a</sup>	328.80±107.78 <sup>a</sup>	304.80±52.74 <sup>ab</sup>	177.60±64.66 <sup>b</sup>

All values represent Mean ±SD (n=3); <sup>a</sup>=significant ( $p < 0.05$ ) when compared with A; <sup>b</sup>=significant ( $p < 0.05$ ) when compared with B; A= normal control, B= diabetic control, C=diabeticrats + Vit C, D=diabeticrats + 100mg/kg b.w of extract, E= diabeticrats + 200mg/kg b.w of extract, F= diabeticrats + 400mg/kg b.w of extract

### 3.1.4 Effect of aqueous extract of *Pterocarpuserinaceus* stem bark on some serum kidney function parameters

As shown in Table 4 levels of serum Uric Acid (UA), creatinine (SCr) and blood urea nitrogen (BUN) were significantly ( $p < 0.05$ ) increased in diabetic control group B when compared with normal control rats. Administration of *P. erinaceus* (100 mg/kg, 200 mg/kg, 400 mg/kg) b.wt in groups D, E, F significantly ( $p < 0.05$ ) decreased BUN and SCr levels when compared to the diabetic control group. The decrease in UA in vit C and all the *Pterocarpuserinaceus* group (D, E, F) were not significant ( $p > 0.05$ ) when compared with the diabetic control group B. There was a decrease in the level of Na<sup>+</sup> and K<sup>+</sup> in the diabetic group (B) when compared with the normal control (A) but was not significant ( $p > 0.05$ ). Also there was an increase in the level of Na<sup>+</sup> in *Pterocarpuserinaceus* treated groups (D, E, F) and vit C which was not significant

( $p > 0.05$ ).  $K^+$  decreased significantly ( $p < 0.05$ ) with *Pterocarpuserinaceus* (200 mg/kg, 400 mg/kg) in groups E and F when compared with diabetic control group. Serum albumin significantly ( $p < 0.05$ ) reduced in diabetic control group. When administered with *Pterocarpuserinaceus* (100 mg/kg, 200 mg/kg, 400 mg/kg) in groups D, E, F and vit C, increased slightly but not significant ( $p > 0.05$ ) when compared to diabetic control group B.

**Table 4: Effect of aqueous extract of *Pterocarpuserinaceus* stem bark on some serum kidney function parameters.**

GROUPS	UA mg/dl	BUN mg/dl	SCr mg/l	Na <sup>+</sup> mg/l	K <sup>+</sup> mg/dl	Albumin g/dl
A	1.01±0.01	97.78±60.00 <sup>b</sup>	0.62±0.03 <sup>b</sup>	105.94±1.69	6.65±0.88	5.04±0.08 <sup>b</sup>
B	1.34±0.06	220.00±3.35 <sup>a</sup>	1.01±0.01 <sup>a</sup>	103.13±1.12	6.07±0.20	4.70±0.21 <sup>a</sup>
C	1.00± 0.00	165.56±1.11	0.42±0.13 <sup>ab</sup>	106.5 ± 1.88	5.53±1.15	4.86 ± 0.19
D	1.08±0.15	114.07±51.75 <sup>b</sup>	0.51±0.13 <sup>b</sup>	105.88 ±5.36 <sup>a</sup>	4.86±1.10	4.67 ±0.09 <sup>a</sup>
E	1.21±0.28	91.11±34.92 <sup>b</sup>	0.66±0.08 <sup>b</sup>	107.88 ±10.06 <sup>a</sup>	4.16±0.81 <sup>b</sup>	4.56±0.17 <sup>a</sup>
F	1.21±0.34	66.67±35.56 <sup>b</sup>	0.68±0.13 <sup>b</sup>	105.50 ±1.11 <sup>a</sup>	3.6±0.12 <sup>b</sup>	4.66±0.21 <sup>a</sup>

All values represent Mean ± SD (n=3); <sup>a</sup>=significant ( $p < 0.05$ ) when compared with A; <sup>b</sup>=significant ( $p < 0.05$ ) when compared with B; A= normal control, B= diabetic control, C=diabeticrats + Vit C, D=diabeticrats + 100 mg/kg b.w of extract, E= diabeticrats + 200 mg/kg b.w of extract, F= diabeticrats + 400 mg/kg b.w of extract, Na = sodium; K= Potassium; BUN = Blood Urea Nitrogen; SCr = serum creatinine, UA=Uric acid.

### 3.1.5. Effect of aqueous extract of *Pterocarpuserinaceus* stem bark on lipid peroxidation and antioxidants of the kidney.

As shown in table 5, there was a significant ( $p < 0.05$ ) increase in MDA levels in diabetic control when compared with normal control group. Administration of *Pterocarpuserinaceus* (100mg/kg,200mg/kg,400mg/kg) in groups D, E, F significant ( $p < 0.05$ ) reduced MDA levels. SOD, CAT, GPx, GSH, and GST levels significantly ( $p < 0.05$ ) reduced in diabetic control group B when compared to normal control group A. Treatment with *Pterocarpuserinaceus* (100 mg/kg, 200 mg/kg, 400mg/kg b.w) in groups D, E, F increased SOD levels significantly ( $p < 0.05$ ) when compared with diabetic control. CAT level increased in groups D, E significantly ( $p < 0.05$ ). GPx increased significantly with group treated with *Pterocarpuserinaceus* 400 mg/kg b.w (F) but was not significantly ( $p > 0.05$ ) increased in groups treated with 100mg/kg and 200mg/kg (D, E). Vit C reduced MDA, increased CAT, SOD and GST significantly ( $p < 0.05$ ), when compared with diabetic rats and non significantly ( $p > 0.05$ ) increased GSH and GPx when compared with diabetic control group.

**Table 5: Effect of aqueous extract of *Pterocarpuserinaceus* stem bark on lipid peroxidation and antioxidants of the kidney**

GROUPS	MDA mg/L	SOD U/mg protein	CAT U/ mg protein	GPx U/mg protein	GSH mg/L	GST nmole/CDMB
A	1.9±0.27 <sup>b</sup>	522.05±53.07 <sup>b</sup>	1336.38±287.12 <sup>b</sup>	246.02±42.02 <sup>b</sup>	10.52±1.98 <sup>b</sup>	2.1±0.42 <sup>b</sup>
B	2.55±0.17 <sup>a</sup>	242.64±20.72 <sup>a</sup>	683.09±13.25 <sup>a</sup>	163.31±1.96 <sup>a</sup>	8.27±0.22 <sup>a</sup>	0.35±0.02 <sup>a</sup>
C	1.8±0.05 <sup>b</sup>	417.84±14.5 <sup>ab</sup>	1292.41±150.49 <sup>b</sup>	175.17±6.47 <sup>a</sup>	9.07±0.33	1.12±0.01 <sup>ab</sup>
D	2.07±0.29 <sup>b</sup>	423.2±5.80 <sup>ab</sup>	977.77±88.71 <sup>ab</sup>	173.35±3.97 <sup>a</sup>	8.32±0.48 <sup>a</sup>	1.24±0.31 <sup>ab</sup>
E	2.1±0.60 <sup>b</sup>	462.76±81.79 <sup>ab</sup>	922.78±125.35 <sup>ab</sup>	170.52±14.89 <sup>a</sup>	8.35 ±0.52 <sup>a</sup>	1.2±0.79 <sup>ab</sup>
F	1.99±0.02 <sup>b</sup>	336.82±1.11 <sup>ab</sup>	699.41±27.08 <sup>a</sup>	209.66±5.26 <sup>ab</sup>	8.44 ±0.36 <sup>a</sup>	1.67±0.31 <sup>b</sup>

All values represent Mean ±SD (n=3); <sup>a</sup>=significant (p<0.05) when compared with A; <sup>b</sup>=significant (p<0.05) when compared with B; A= normal control, B= diabetic control, C=Alloxan induced rats + Vit C, D=diabetic rats + 100 mg/kg b.w of extract, E= diabetic rats + 200 mg/kg b.w of extract, F= diabetic rats + 400 mg/kg b.w of extract. MDA = Malondialdehyde, SOD = Superoxide Dismutase, CAT = Catalase, GPx=Glutathione Peroxidase, GST= Glutathione Transferase, GSH=Reduced Glutathione.

### 3.1.6 Effect of aqueous extract of *Pterocarpuserinaceus* stem bark on inflammatory cytokines in the kidney.

Table 6 shows the results on inflammatory cytokines. TNF-alpha, IL-6 and TGF-β levels increased significantly (p<0.05) in diabetic control group B when compared to the normal control group A. Treatment with *Pterocarpuserinaceus* (100 mg/kg, 200 mg/kg, 400 mg/kg) in groups D, E, F and Vit C significantly reduced TNF-alpha, IL-6 and TGF-β levels in diabetic rats when compared to diabetic control group.

**Table 6: Effect of aqueous extract of *Pterocarpuserinaceus* stem bark on inflammatory cytokines in the kidney**

GROUPS	TNF-alpha ng/ml	IL-6 ng/ml	TGF-β Pg/ml
A	39.48±0.54 <sup>b</sup>	47.26±11.49 <sup>b</sup>	0.69±0.28 <sup>b</sup>
B	322.99±9.04 <sup>a</sup>	137.52±5.00 <sup>a</sup>	16.85± 0.87 <sup>a</sup>
C	34.07±4.33 <sup>b</sup>	45.52±7.15 <sup>b</sup>	0.54± 0.17 <sup>b</sup>
D	37.68±8.19 <sup>b</sup>	50.43±16.14 <sup>b</sup>	0.63 ± 0.31 <sup>b</sup>
E	30.65±8.79 <sup>b</sup>	70.70±18.05 <sup>b</sup>	2.43±2.30 <sup>b</sup>
F	28.85±6.27 <sup>b</sup>	57.19±24.23 <sup>b</sup>	0.69±0.33 <sup>b</sup>

All values represent Mean ±SD (n=3); <sup>a</sup>=significant (p<0.05) when compared with A; <sup>b</sup>=significant (p<0.05) when compared with B; A= normal control, B= diabetic control, C=Alloxan induced rats + Vit C, D=diabetic rats + 100mg/kg b.w of extract, E= diabetic rats + 200 mg/kg b.w of extract, F= diabetic rats + 400 mg/kg b.w of extract. TGF-β = Transforming growth factor beta, TNFα = Tumor necrosis factor α, IL-6 = Interleukin 6

### 3.1.7 Histopathological examination of the kidney

Section from the kidney of the normal control group shows the normal architecture of the convoluted tubules (CT), Bowman's capsule (BC) and glomerulus (G) (A). In diabetic rats, kidney showed an increase in size of Bowman's space and atypical convoluted tubules. when compared with the normal control group (B). Sections of kidneys from animals treated with aqueous stem bark extract of *Pterocarpuserinaceus*(100, 200 and 400 mg/kg) D, E, and F respectively, showed glomeruli (G), Bowman's capsule (BC) and convoluted tubule (CT) at various stages of restoration.

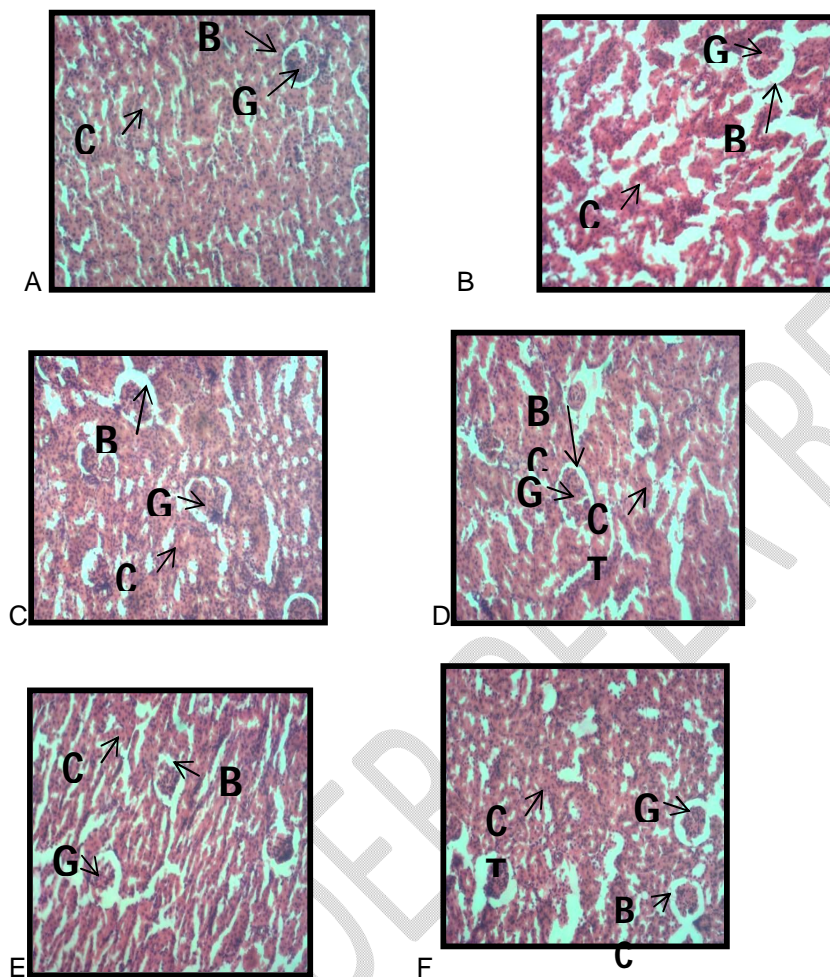


Figure 1: Showing photomicrograph of the kidney. A= normal control, B= diabetic control, C=diabeticrats + Vit C, D=diabeticrats + 100mg/kg b.w of extract, E= diabeticrats + 200mg/kg b.w of extract, F= diabeticrats + 400mg/kg b.w of extract.convoluted tubules (CT), Bowman's capsule (BC) and glomerulus (G)

### 3.2 Discussion

Phytochemical screening of *Pterocarpuserinaceus* shows the presence of phenols, tannins, saponins, alkaloids, glycosides, cardiac glycosides and flavonoides. The presence of these phytochemical in *P. erinaceus* stem bark was also reported by Ahmed *et al.*, [28]; Patrick *et al.*, [29]. Also absence of anthroquinones was in agreement with Ajayi and Uguru, [30]. The difference in phytochemicals observed may be due to genetic variations and environmental factor [28]. It has also been reported that flavonoids, phenolics, saponins occurring in variety of plants are reported to have shown antidiabetes and antioxidant activity in laboratory animals [31]. Therefore, the presence of one or all of these phytoconstituents might

beresponsible for the pharmacological properties of *Pterocarpuserinaceus* stem bark such as antidiabetic, and antioxidant activities.

Acute toxicity test ( $LD_{50}$ ) of *Pterocarpuserinaceus* stem bark aqueous extract was found to be greater than 5000 mg/kg b.wt. Therefore the doses used in acute toxicity are safe in the rats because there were no mortality, weakness or any visible sign of toxicity. This result agrees with other research work [32; 33].

The free radical scavenging activities is thought to be due to their hydrogen donating ability [34]. The results obtained in this study suggest that aqueous extract of *Pterocarpuserinaceus* stem bark showed radical scavenging activity and could be used as source of antioxidant for prevention and treatment of oxidative stress associated diseases. These results revealed that the aqueous extract of *Pterocarpuserinaceus* stem bark had a similar free radical scavenging activity when compared with standard ascorbic acid. Patrick *et al.*, [35] also showed that *Pterocarpuserinaceus* possessed antioxidant activity with DPPH.

A glucose tolerance test is used to determine body's ability to handle or metabolize a standardized measures amount of glucose load [36]. This test can be used to diagnose pre-diabetes and diabetes. From the data obtained with the oral glucose tolerance test, it is clear that blood glucose levels reached a peak and returned to near fasting values after 2 h in both normal and treated rats. Increased blood glucose levels remained high even after 2 h in diabetic control rats. *Pterocarpuserinaceus* stem bark administration effectively prevented the increase in blood glucose without causing a hypoglycemic state, an effect due to the restoration of the delayed insulin response. This result is in line with Atchouet *et al.*, [37] which showed that 250mg/kg b.w of *Pterocarpuserinaceus* stem bark hydroethanolic extract effectively decrease postprandial hyperglycemic condition.

The kidney maintains optimum chemical composition of fluids by removal of metabolic waste such as urea, uric acid and creatinine. When there is a renal disease, the concentration of these metabolites increases in the blood [38]. Creatinine is a waste product that comes from the normal wear and tear on muscles of the body. The amount of creatinine in the serum is usually constant. In this study there was a significantly elevated level of creatinine in diabetic control rats which is an indication of an impaired kidney function since it can be excreted easily by the kidney. Deficiency of insulin and the inability of glucose to reach the extra hepatic tissues stimulates gluconeogenesis as alternate route of glucose supply. Free circulating glucogenic amino acids are released as a result of increased proteolysis which sustains gluconeogenesis. These glucogenic amino are deaminated in the liver to urea in urea cycle thus explaining the increased level of urea in diabetic control [39]. Uric acid is the end product of purine metabolism. In our current research, the increased levels of creatinine, BUN, and uric acid in diabetic control group supports renal damage, an important index of diabetic nephropathy in agreement with Ekakitie *et al.* [40]. Also many other studies showed significant increase of these metabolites in diabetic rats [41;42]. However, oral administration of aqueous extract of *Pterocarpuserinaceus* stem bark improved this impairment in renal function by reducing serum creatinine, BUN, and uric acid. This also supports the anti-nephropathy (ameliorating) potential of the extract. In this study in serum albumin was reduced in diabetic control group which may be partially explained due to reduced reabsorption of albumin in the proximal convoluted tubule [43] or may be due to albuminuria, which is an important clinical marker of diabetic nephropathy [38]. The result shows that *Pterocarpuserinaceus* aqueous stem bark extract reduces the development of diabetic nephropathy by slightly increasing serum albumin as compared with diabetic control group.

Electrolyte imbalance resulting from kidney failure, dehydration, fever, and vomiting has been suggested as one of the contributing factors toward complications observed in diabetes and other endocrine disorders [44]. The decrease in the the levels of  $Na^+$  and  $K^+$  levels in the diabetic control group when compared with the normal group may be as a result of an altered distribution of electrolytes and it is related to hyperglycemia induced osmotic fluid shifts or of total-body deficits brought about by osmotic diuresis [45] accompanied with the marked urinary loss of water and electrolytes. The increase in the level of  $Na^+$  in the group treated with *Pterocarpuserinaceus* (100mg/kg, 200mg/kg, 400mg/kg ) is an indication that the extract may have the ability to improve insulin secretion and uptake in diabetic rats drives glucose and water into the cells, thereby reducing dehydration, reverses the initial direction of water movement and results in an increment of serum sodium levels [46]. On the other hand further decrease in  $K^+$  observed with

the groups treated with *Pterocarpuserinaceus* (100 mg/kg, 200 mg/kg, 400 mg/kg ) may be due to redistribution of potassium K<sup>+</sup> from the extracellular to the intracellular fluid compartment which happens when insulin is utilized by cells [47]. This is an indication that *Pterocarpuserinaceus* aqueous extract may have the ability to improve insulin secretion and glucose uptake in diabetic rats.

Oxygen free radicals react with all biological substances; however, the most susceptible ones are polyunsaturated fatty acids. Reactions with these cell membrane constituents lead to lipid peroxidation [48; 49]. Increased prooxidant activity, as indicated by elevated kidney malondialdehyde (MDA) levels in this study, is an indication of decline in defence mechanisms of enzymatic and non enzymatic antioxidants [50]. *Pterocarpuserinaceus* aqueous stem bark extract significantly reduced the lipid peroxidation product levels in diabetic rats, confirming that *Pterocarpuserinaceus* aqueous stem bark extract is a potent antioxidant. In the present study, catalase (CAT) superoxide dismutase (SOD) and glutathione peroxidase (GSH-Px) antioxidants and glutathione transferase (GST) activities were significantly decreased in kidney of diabetic rats. The significant decrease in these enzyme activities could suggest that the enzyme has been inactivated by ROS, which are increased in diabetic rats. SOD catalyze the dismutation of superoxide (O<sub>2</sub><sup>-</sup>) to hydrogen peroxide (H<sub>2</sub>O<sub>2</sub>) and O<sub>2</sub>.H<sub>2</sub>O<sub>2</sub> is then deactivated by CAT or GPX [11]. GSH is a potent non-enzymatic antioxidant whose actions includes conjugation with free radicals directly, enzyme-mediated neutralization of free radicals, and the regeneration of other antioxidants vitamins such as Vitamin C [51]. The kidney of diabetic control rats showed a decreased level of GSH which might be due to increased utilization for scavenging free radicals and increased consumption by GPx and GST in which it acts as substrat. Treatment with *Pterocarpuserinaceus* and vitamin C ameliorated GSH, SOD, CAT, GPx and GST activities in kidney of diabetic rats. These results suggest that with *Pterocarpuserinaceus* stem bark extract has free radical scavenging activity, which may exert a beneficial effect against pathological changes caused by ROS. This result is in agreement with other studies [29; 34]. The antioxidant activity of *Pterocarpuserinaceus* stem bark may be as a result flavonoid and tannins which were revealed in this study. They may have acted alone or in synergy.

Proinflammatory cytokines and renal tubule fibrosis play an important role in the development and progression of diabetic nephropathy [52]. In this present study, a significant ( $p < 0.05$ ) increase in the levels of TNF- $\alpha$ , IL-6 and TGF- $\beta$  in kidney tissue of diabetic control group rats. TNF- $\alpha$  is cytotoxic to glomerular, mesangial and epithelial cells and competent to induce direct renal injury through the generation of reactive free radicals in various cells, including mesangial cells. IL-6 accelerates mesangial cell proliferation, enhances fibronectin expression, affects extracellular matrix dynamics at both mesangial and podocyte levels and increases endothelial permeability [53]. TGF- $\beta$ 1 promotes extracellular matrix accumulation in the mesangium, which decreases glomerular filtration rate, and leads to glomerulosclerosis and interstitial fibrosis in diabetic kidney [54]. However treatment with *Pterocarpuserinaceus* significantly ( $p < 0.05$ ) attenuated these pro inflammatory cytokines and TGF- $\beta$  levels, thereby moderating the consequences of inflammation and lowered kidney fibrosis in diabetic rats.

The results of the study showed that diabetic kidney changes may be protected by administration of *Pterocarpuserinaceus* aqueous stem bark extract as seen in the mild restoration of treated group. The *Pterocarpuserinaceus* aqueous stem bark extract possibly acts as an antioxidant thereby checking the oxidative damages to the microstructure of the kidney.

#### 4 Conclusion

Data from the present study clearly indicate that the aqueous extract of *Pterocarpuserinaceus* stem bark exhibited significant antihyperglycemic, improved renal function test, prevented glomerular damage by reducing oxidative stress which leads to lipid peroxidation, reducing inflammatory cytokines and as well regenerated the kidney tissues. The results of this present study supports the antidiabetic and antioxidant and anti inflammatory potential of *Pterocarpuserinaceus* stem bark as claimed in the traditional use. The flavonoids, tannins, alkaloids and phenols present in the extracts may be responsible for its activity as well. Further studies are required to investigate the actual mechanism of action of the bioactive components of aqueous extract of *Pterocarpuserinaceus* with the view to enhancing it for maximum antidiabetic and antioxidant activity.

## REFERENCE

1. Manpreet SK, Luigi G. Diabetic nephropathy: Is there a role for oxidative stress? *Free radical biology & medicine*.2017; 116:50–63. <https://doi.org/10.1016/j.freeradbiomed.2017.12.040>
2. Guo GW, Xiao HL, Wei L, Xue Z, Cui Z. Protective Effects of Luteolin on Diabetic Nephropathy in STZ-Induced Diabetic Rats. *Evidence-Based Complementary and Alternative Medicine*. 2011; ID 323171. doi:10.1155/2011/323171
3. Munehiro K, Yoshio O, Daisuke K. Rodent models of diabetic nephropathy: their utility and limitations. *International Journal of Nephrology and Renovascular Disease*. 2016;9:279–290
4. Jamshidi H, Zeinabady Z, Zamani E, Shokrzadeh M, Shaki F. Attenuation of Diabetic Nephropathy by Carvacrol through Anti-oxidative Effects in Alloxan-Induced Diabetic Rats. *Research Journal of Pharmacognosy*.2018;5(2): 57-64. doi: 10.22127/rjp.2018.58508
5. Kokou A, Povi L, Kwashie E. In vitro study of protective effect of *Pterocarpuserinaceus*Poir. stem bark and *Amaranthus spinosus* L. root extracts on cataractogenesis and glomerulopathy. *Bulletin of the National Research Centre*. 2021;45:91. <https://doi.org/10.1186/s42269-021-00552-8>
6. Aliyu M, Chedi BAZ. Effects of the Ethanolic Stem Bark Extract of *PterocarpusErinaceus*Poir (Fabaceae) on Some Isolated Smooth Muscles. *Bayero Journal of Pure and Applied Sciences*.2010;3(1):34 – 3
7. Ewansiha J, Garba S, Mawak J, Oyewole O. Antimicrobial Activity of *CymbopogonCitratius* (Lemon Grass) and It's Phytochemical Properties. *Frontiers in Scienc*. 2013;2: 214-220. 10.5923/j.fs.20120206.14.
8. Vishnu B, Sheerin FMA, Sreenithi V A Guide to Phytochemical Analysis. In: *International Journal of Advance Research and Innovative Ideas in Education*. 2019; 5(1):2395-4396 B.
9. Kikuzaki H, Nakatani N. Antioxidant Effects of Some Ginger Constituents. *Journal of Food Science*.1993; 58:1407-1410. <http://dx.doi.org/10.1021/jf00020a008>
10. Enevide C, Arome D, Ameh FS. A new method for determining acute toxicity in animal models. *Toxicology international*. 2013;20(3):224–226. <https://doi.org/10.4103/0971-6580.121674>
11. Al-Fartosy AJM. Protective Effect of Galactomannan Extracted from Iraqi *Lyciumbarbarum* L. Fruits against Alloxan-Induced Diabetes in Rats. *American Journal of Biochemistry and Biotechnology*. 2015;11(2):73–83. <https://doi.org/10.3844/ajbbsp.2015.73.83>
12. Etuk EU. Animal models for studying diabetes mellitus. *Agriculture and Biology Journal of North America*. 2010;1(2):130-134
13. Ajiboye BO, Oyinloye BE, Essien PE, Onikanni SA, Ojo OA, Kappo AP. Ameliorative potential of *Sterculiatragacantha* aqueous extract on renal gene expression and biochemical parameters in streptozotocin-induced diabetic rats. *Journal of Pharmaceutical Investigation*. 2020;51(1), 103–113. <https://doi.org/10.1007/s40005-020-00506-8>
14. Barham D, Trinder P. *Analyst*. 1972;97:142-145
15. Bartels H, Bohmer M. Quantitative Determination of Creatinine. *ClinicaChimicaActa*.1972;37: 193.
16. Fawcett J K, Scott J E. A rapid and precise method for the determination of urea. *Journal of clinical pathology*.1960; 13(2):156–159. <https://doi.org/10.1136/jcp.13.2.156>
17. Maruna RFL. Colorimetric determination of sodium in human serum and plasma. *ClinicaChimicaActa*. 1958; 2: 581.
18. Trinder P. *Analyst*.1951; 76:596.
19. Tietz NW. *Fundamentals of Clinical Chemistry*, W.B. Saunders Co., Phila, PA.1986; p. 874.
20. Grant GH, Silverman LM, Christenson RH. Amino acids and proteins. In: *Fundamentals of Clinical Chemistry*. 3rd ed. Philadelphia: WB Saunders; 1987;291-345.
21. Buege JA, Aust SD. Microsomal lipid per-oxidation. *Methods in Enzymology*. 1978; 52:302-310.
22. Sun M, Zigma S. An Improved Spectrophotometer Assay of Superoxide Dismutase Based on Epinephrine Antioxidation. *Analytical Biochemistry*. 1978;90:81-89. [https://doi.org/10.1016/0003-2697\(78\)90010-6](https://doi.org/10.1016/0003-2697(78)90010-6)
23. Sinha AK. Colorimetric Assay of Catalase. *Analytical Biochemistry*. 1972; 47:389-394. [http://dx.doi.org/10.1016/0003-2697\(72\)90132-7](http://dx.doi.org/10.1016/0003-2697(72)90132-7)
24. Sedlak J, Lindsay RH. Estimation of total, protein-bound, and nonprotein sulfhydryl groups in tissue with Ellman's reagent. *Analytical biochemistry*, 1968;25(1):192–205. [https://doi.org/10.1016/0003-2697\(68\)90092-4](https://doi.org/10.1016/0003-2697(68)90092-4)

25. Ursini F, Mariorino M, Brigelius-Flohé R, Aumann KD, Roveri A, Schomburg D, Flohé L. Diversity of glutathione peroxidase. *Methods in Enzymology*.1995; 252:38–53.
26. Habig WH, Pabst MJ, Jakoby WB. Glutathione S-transferases. The first enzymatic step in mercapturic acid formation. *The Journal of biological chemistry*.1974;249(22):7130–7139
27. Lowry OH, Rosebrough NJ, Farr AL, Randall RJ. Protein measurement with the Folin phenol reagent. *The Journal of biological chemistry*/1951;193(1):265–275.
28. Ahmed M, Modibbo A, Zaruwa M, Sudi I. Phytochemical and Nutrient Composition of Pterocarpuserinaceus Stem Bark. *International Journal of Biochemistry Research & Review*,2017; 19(2), 1–6. <https://doi.org/10.9734/ijbcr/r/2017/36546>
29. Patrick AT, Samson F, Madusolumuo MA. Antulcerogenic Effects of Aqueous Stem-Bark Extracts of Pterocarpuserinaceus on Indomethacin-Induced Ulcer in Albino Rats. *J Biochem Cell Biol*2018;1: 107.
30. Ajayi VF, Uguru M. Acute and Sub acute Toxicity Studies of Pterocarpuserinaceus in Rats. *World Journal of Innovative Research (WJIR)*.2021;10(4):01-11.
31. Malviya N, Jain S, Malviya S. Anti-diabetic potential of medicinal plants. *ActaPoloniaePharmaceutica*. 2010;67(2):113-118
32. Salawu OA, Aliyu M, Tijani AY. Haematological studies on the ethanolic stem bark extract of PterocarpuserinaceusPoir (Fabaceae). *African Journal of Biotechnology*.2008; 7(9): 1212-15
33. Atchou K, Lawson-Evi P, Ekl-Gadegbeku K. In vitro study of protective effect of PterocarpuserinaceusPoir. stem bark and Amaranthusspinosus L. root extracts on cataractogenesis and glomerulopathy. *Bulletin of the National Research Centre*. 2021; 45(1) <https://doi.org/10.1186/s42269-021-00552-8>
34. Rahman MM, Islam MB, Biswas M, Alam K. In vitro antioxidant and free radical scavenging activity of different parts of *Tabebuia pallida* growing in Bangladesh. *BMC Res Notes*.2015;8: 621 <https://doi.org/10.1186/s13104-015-1618-6>
35. Patrick A, Samson F, Jalo K, Thagriki D, Aduwamai U, Madusolumuo M. In Vitro Antioxidant Activity And Phytochemical Evaluation Of Aqueous And Methanolic Stem Bark Extracts Of Pterocarpuserinaceus. *World Journal of Pharmaceutical Research*.2016;6805:134-151. 10.20959/wjpr20164-5858.
36. Eyth E, Hajira B, Smith CJ. Glucose Tolerance Test. Nih.gov; *StatPearls Publishing*. 2019 <https://www.ncbi.nlm.nih.gov/books/NBK532915/>
37. Atchou K, Lawson-Evi P, Metowogo K, AkliKokou K, Gbeassor M. Hypoglycemic effect and antioxidant potential of PterocarpuserinaceusPoir. stem bark and Amaranthusspinosus L. roots extracts. *Journal of Pharmaceutical Sciences and Research*.2020;12(3):340-350
38. Sharma B, SiddiquiMohd. S, Ram G, Yadav RK, Kumari A, Sharma G, Jasuja ND. Rejuvenating of Kidney Tissues on Alloxan Induced Diabetic Mice under the Effect of Momordicacharantia. *Advances in Pharmaceutics*. 2014;1–9.<https://doi.org/10.1155/2014/439158>
39. Atangwho IJ, Ebong PE, Eteng MU, Eyong EU, Obi AU. Effect of Vernoniaamygdalina Del Leaf on Kidney Function of Diabetic Rats. *International Journal of Pharmacology*. 2007;3(2):143–148. <https://doi.org/10.3923/ijp.2007.143.148>
40. Ekakitie L, Ajiboye BO, Oyinloye BE, Owero-ozeze OS, Onikanni SA, Ojo OA. Attenuation of diabetic nephropathy in alloxan-induced diabetic rats by Solanummacrocarpon Linn aqueous leaves extract. *Comparative Clinical Pathology*.2021; 30(2):173–179. <https://doi.org/10.1007/s00580-021-03220-5>
41. Abd El-HameedAM. Polydatin-loaded chitosan nanoparticles ameliorates early diabetic nephropathy by attenuating oxidative stress and inflammatory responses in streptozotocin-induced diabetic rat. *Journal of Diabetes & Metabolic Disorders*. 2020.<https://doi.org/10.1007/s40200-020-00699-7>
42. Abouzed T K, Contreras M, del M, Sadek KM, Shukry MH, Abdelhady D, Gouda WM, Abdo W, Nasr NE, Mekky RH, Segura-Carreter A, Kahilo KAA, Abdel-Sattar E. Red onion scales ameliorated streptozotocin-induced diabetes and diabetic nephropathy in Wistar rats in relation to their metabolite fingerprint. *Diabetes Research and Clinical Practice*.2018;140:253–264. <https://doi.org/10.1016/j.diabres.2018.03.042>
43. Tojo A, Onozato ML, Ha H, Kurihara H, Sakai T, Goto A, Fujita T, Endou H. Reduced albumin reabsorption in the proximal tubule of early-stage diabetic rats. *Histochemistry and cell biology*.2001; 116(3):269–276. <https://doi.org/10.1007/s00418010031>

44. Khanduker S, Ahmed R, Khondker F, Aharama A, Afrose N, Chowdhury M A. Electrolyte Disturbances in Patients with Diabetes Mellitus. *Bangladesh Journal of Medical Biochemistry*, 2017; 10(1):27–35. <https://doi.org/10.3329/bjmb.v10i1.36698>
45. Datchanamurthi S, Vanaja R, Rajagopalan B. Evaluation of serum electrolytes in type II diabetes mellitus. *International Journal of Pharmaceutical Sciences Review and Research*. 2016;40:251-253.
46. Olorunnisola OS, Adetutu A, Popoola RB, Owoade AO, Adegbola P, Adesina BT. Nephroprotective effect of ethanolic leaf extract of *Thaumatococcus Danielli* (Benth.) in streptozotocin induced diabetic rats. *Functional Foods in Health and Disease*. 2017;7(12):923. <https://doi.org/10.31989/ffhd.v7i12.349>
47. Coregliano-Ring L, Goia-Nishide K, Rangel ÉB. Hypokalemia in diabetes mellitus setting. *Medicina*. 2022;58(3):431. <https://doi.org/10.3390/medicina58030431>
48. Memişoğulları R, Bakan E. Levels of ceruloplasmin, transferrin, and lipid peroxidation in the serum of patients with Type 2 diabetes mellitus. *Journal of diabetes and its complications*, 2004; 18(4):193–197. [https://doi.org/10.1016/S1056-8727\(03\)00032-1](https://doi.org/10.1016/S1056-8727(03)00032-1)
49. Fatani SH, Babakr AT, NourEldinEM, Almarzouki AA. Lipid peroxidation is associated with poor control of type-2 diabetes mellitus. *Diabetes & Metabolic Syndrome: Clinical Research & Reviews*. 2016; 10(2):S64–S67. <https://doi.org/10.1016/j.dsx.2016.01.028>
50. Tiwari BK, Pandey KB, Abidi AB, Rizvi SI. Markers of Oxidative Stress during Diabetes Mellitus. *Journal of Biomarkers*. 2013; 1–8. <https://doi.org/10.1155/2013/378790>
51. Braidly N, Zarka M, Jugder BE, Welch J, Jayasena T, Chan DKY, Sachdev P, Bridge W. The Precursor to Glutathione (GSH),  $\gamma$ -Glutamylcysteine (GGC), Can Ameliorate Oxidative Damage and Neuroinflammation Induced by A $\beta$ 40 Oligomers in Human Astrocytes. *Frontiers in Aging Neuroscience*. 2019; 11. <https://doi.org/10.3389/fnagi.2019.00177>
52. Palsamy P, Subramanian S. Resveratrol protects diabetic kidney by attenuating hyperglycemia-mediated oxidative stress and renal inflammatory cytokines via Nrf2–Keap1 signaling. *Biochimica et Biophysica Acta (BBA) - Molecular Basis of Disease*. 2011; 1812(7):719–731. <https://doi.org/10.1016/j.bbadis.2011.03.008>
53. Navarro-González JF, Mora-Fernández C. The role of inflammatory cytokines in diabetic nephropathy. *Journal of the American Society of Nephrology JASN*. 2008; 19(3):433–442. <https://doi.org/10.1681/ASN.2007091048>
54. Chang AS, Hathaway CK, Smithies O, Kakoki M. Transforming growth factor- $\beta$ 1 and diabetic nephropathy. *American journal of physiology. Renal physiology*. 2016; 310(8):F689–F696. <https://doi.org/10.1152/ajprenal.00502.2015>

## ETHICAL APPROVAL

Ethical clearance was approved by NSUK Animal Care and Use Research Committee (NSUK-ACUREC).