

# Phytochemical characterization and acute toxicity investigation of the hydroethanolic leaf extract of *Dacryodes edulis* (G. Don) H.J. Lam on Wistar rat models

## ABSTRACT

Medicinal plants play an important role in the management of several diseases and have become widespread. However, people use plant species without considering the toxicity they may present. In a previous study, the hydroethanolic leaf extract of *D edulis* showed a very good anti-ulcer activity (86% protection rate). The aim of this study was to evaluate the phytochemical composition and to investigate the acute toxicity of this extract on zootechnical, biochemical and histological parameters in Wistar rats.

Fresh leaves of *Dacryodes edulis* were collected in Yaoundé, Cameroon and a qualitative and quantitative phytochemical assessment was carried out using the methods described by Harbone. Then the acute toxicity was tested according to Organization for Economic Co-operation and Development (OECD) guideline 423, by forming 2 experimental groups of 10 animals each (5 males and 5 females): Group I (Control), which received 2 mL of physiological saline solution (SSF 0.9%), Groups II, which received the hydro-ethanolic leaf extract of *D. edulis* in a single dose of 2000 mg/kg. The zoophysical behaviour of the animals was observed for 14 days and on the 14th day of exposure, biochemical (Protein, creatinine, ALT, and AST) and histopathological parameters of the liver and kidney were measured.

Several primary metabolites including total polyphenols, tannins, coumarins, flavonoids, betacyans were identified, anthraquinones, cardiac glycosides and ascorbic acid. Furthermore, the extract did not cause any pathological changes as revealed by the biochemical markers of the organs whose functions were evaluated, and the histological analysis showed a normal organ architecture when compared to controls. The hydro-ethanolic extract was therefore relatively safe and without toxic effects according to the parameters tested at the dose of 2000 mg/kg.

**Keywords:** *Dacryodes edulis*, phytochemicals, acute toxicity, liver, kidneys.

## INTRODUCTION

“Medicinal plants play a fundamental role in the treatment of various diseases to the extent that their use has become widespread throughout the world” (1, 2). Due to the large variability of applications of medicinal plants, they are often considered by the population to be the safest and free from adverse effects in the body, as they are of natural origin (3, 4). “Plant species can contain extremely toxic substances such as strychnine, digitoxin, cyanogenic glycosides” (5, 6), “Several cases of acute or chronic toxicity related to the use of medicinal plants have been reported and the toxic effects usually observed include mild gastrointestinal symptoms, allergic reactions and other more serious effects such as renal and/or liver toxicity, haematological, cardiovascular, neurological, carcinogenic and sometimes death” (7-9).

Thus, to ensure safety in the use of herbal products, toxicological investigations are always necessary to determine the LD50 and to better prevent serious adverse effects and to have scientific evidence to choose effective and appropriate doses for humans (10, 11). “Toxicological studies ensure the safety of the product throughout the ADME (administration distribution, metabolism, excretion) pathway and generally include the determination of toxicity (acute, sub-acute, chronic), mutagenicity, genotoxicity and the reproductive toxicity” (12). “*Dacryodes* (family *Burseraceae*) is a

plant genus that currently includes about 70-80 species naturally distributed in tropical America, South and Central Africa and Southeast Asia" (10). "The main species in this genus include *Dacryodes edulis* (G. Don) H.J.Lam, *Dacryodes rostrata* (Blume) H.J.Lam, *Dacryodes buettneri* (Engl.) H.J.Lam, *Dacryodes klaineana* (Pierre) H.J.Lam" (11). "*Dacryodes edulis* (G. Don) H.J. Lam is the most popular species" (13). "The different parts of the plant are used by local populations in West and Central Africa for nutrition and ethnomedicine (12). The fruits are mainly used for consumption while the other parts (leaves, stems, roots, bark) are used in other forms for several purposes" (14). "The bark, for example, is used to treat skin diseases, wounds, dysentery, etc., while the leaves, according to several recent studies, are known to have numerous pharmacological properties, including : antibacterial, antidiabetic, anticancer properties" (15–17). "Leaf decoctions are also used to heal high blood pressure, to treat malaria, general weakness, and relieve labour pains and diabetes mellitus" (18).

"The use of this plant in a wide range of traditional medical practices has required several scientific studies to evaluate its therapeutic potential" (12). "Antioxidant activity of leaves and oil; antimicrobial and antibacterial activity of seeds(19); haematopoietic activities (20), anti-cardiovascular and anti-depranocytic of seeds and leaves (12) have been reported". However, very little information and fairly detailed data are available regarding the safety of extracts of this plant. The aim of this study was to assess the acute toxicity of the hydro-ethanolic leaf extract of *D. edulis*. A previous study in which the antiulcer properties of two leaf extracts (aqueous and hydro-ethanolic) showed a more significant antiulcer activity of the hydro-ethanolic extract, so this extract was chosen for this study.

## **MATERIALS AND METHODS**

### **Plant material**

Fresh leaves in first flower phenophase of the plant were collected in a locality of Yaoundé in the Central Region of Cameroon and were then identified by the national botanical library (Herbarium) and assigned a voucher number 66954. The leaves were dried in the shade at room temperature for 2 weeks.

### **Preparation of extract:**

The hydro-ethanolic extract was obtained by dissolving 100g of powder in 1000 ml of a water/ethanol absolute mixture (40/60 v/v ratio). After a stay of 48h at room temperature, the mixture was filtered through a Whatman N°1 filter paper and the collected filtrate was evaporated in an oven at 50°C.

### **Phytochemicals characterization**

The phytochemical screening involved identification of the presence of the following primary and secondary metabolites: carbohydrates, proteins, lipids, total polyphenols, tannins, coumarins, mucilages, saponosides, alkaloids, flavonoids and flavonoles, betacyans, quinones, anthraquinones, phlobotanins, oxalates, cardiac glycosides, steroids, terpenoids and ascorbic acid. Identification and quantification was done according to the methods of Marcano and Hasenawa (1991) (21), Harbone (1998) (22).

### **Animal material and acclimatization condition**

Twenty adult male and female Wistar rats with a body weight between 170 and 200 g were used for the experiment. They were acclimatized for seven days during which they were fed ad libitum with standard food and drinking water and housed in clean cages under well ventilated housing conditions throughout the experiment.

### **Acute toxicity assay**

The test was performed according to the method described in the OCED guideline 423 on oral toxicity (23). The specimens were divided into 2 groups of 10 specimens as shown in Table 1.

Table 1 : Establishment of the study groups.

Group 1	5 males	distilled water
	5 females	
Group 2	5 males	HEE at 2000 mg / kg
	5 females	

Group 1 received 2 ml/kg of distilled water and was used as a control. Group 2 received the plant extract as a single dose of 2000mg/kg. All treatments were administered once by oral gavage. The animals were closely observed for 4 h after administration and once a day for 14 days on general behaviour, clinical signs of toxicity, mortality, food and water intake. Body weight was measured before and then daily until the last day of the experiment. At the end of the experiment (day 14), the animals were sacrificed and a heart puncture was performed to collect blood for biochemical evaluations. Then, the animals were euthanised by cervical dislocation and the following organs were removed for macroscopic (heart, liver, lungs, brain, spleen, kidneys, testes/ovaries) and histopathological (liver, kidneys) analysis.

### **Biochemical Marker testing.**

#### ***Serum biochemical analysis***

Biochemical analysis was performed in all animals. The collected blood was transferred to tubes without anticoagulant and centrifuged at 3500 rpm for 10 minutes. Serum from each sample was recovered and stored in cryotubes at -80°C in the freezer until the measurement. Aspartate amino transferase (AST), alanine aminotransferase (ALT), creatinine, urea, uric acid and total protein were assessed using the Chonolab kits (Barcelonna, Spain) and the UV/VIS spectrophotometer (VWR).

#### **Histopathological analysis of liver and kidney**

“Organs were removed from all animals, washed with 0.9% (w/v) saline, weighed and fixed in 10% formaldehyde solution. The organs were cleaved and processed for paraffin embedding. Sections (5  $\mu$ m thick) were made using a LEICA RM 2125 RT microtome and stained with haematoxylin-eosin (HE)” (24). The tissues were analyzed under the light microscope for general structure, degenerative changes, evidence of necrosis and signs of inflammation. Microscopic images were scanned by micro-camera.

#### **Statistical Analysis of Data**

The data required for anti-ulcer cases was replicated three times in all groups, and the results were exhibited as mean  $\pm$  S.E.M. Comparison between test groups and control groups was performed using ANOVA followed by Tukey's Kramer's pos hoc test, the difference between groups was significant at a p-value < 0.05

## **RESULTS**

### **Phytochemical content**

The metabolites found were: sugars, proteins, total polyphenols, tannins, coumarins, total polyphenols, tannins, coumarins, flavoids, betacyans, anthraquinones, cardiac glycosides, ascorbic acid. Table 2 shows the quantitative estimates of the main metabolites.

### **Effects on the zootechnical parameters**

#### **Effect on weight gain**

The animals that received the product showed an increasing trend that was similar to that of the control groups (figure 1).

#### **Effect on weight gain by administration of « Immunoboost ».**

The extract caused a non-significant ( $p$ -value  $>0.05$ ) decrease in weight gain in both males and females (Figure 2).

### Effect on food intake

A non-significant decrease in food and water intake was observed (figure 3 and figure 4).

### Effect on the relative weight of internal organs

No significant difference with a  $p$ -value  $> 0.05$  between untreated and test animals was observed. The product therefore did not affect the internal macroscopy of the animals (Table 3).

Table 2 : Phytochemicals content estimation of the main metabolites

Metabolites	quantitative estimation
Carbohydrates (Ueq/gMS)	44.75 $\pm$ 1.52
Total proteins(Ueq/gMS)	104.92 $\pm$ 0.64
Polyphenols (Uep/gMS)	60.06 $\pm$ 0.97
Flavonoids (Ueq/gMS)	315.29 $\pm$ 7.14
Flavonols (Ueq/gMS)	150.25 $\pm$ 0.00
Total tanins (Ueq/gMS)	25.60 $\pm$ 5.22

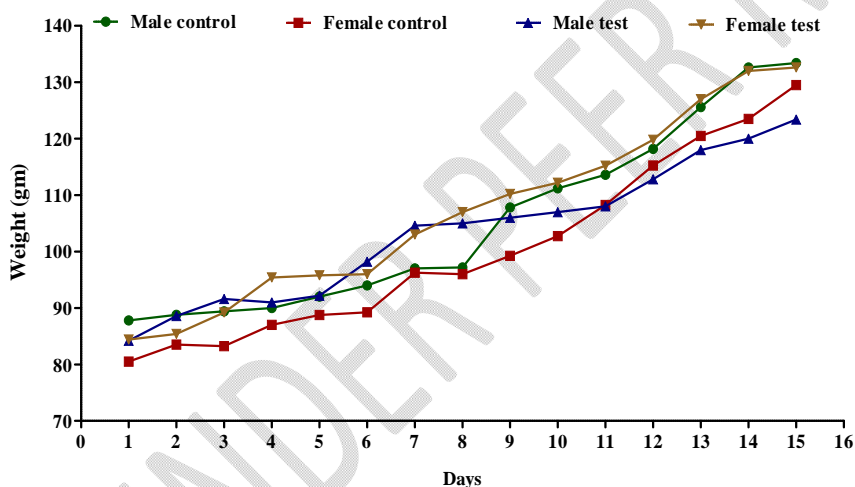


Figure 1: Kinetics of weight change.

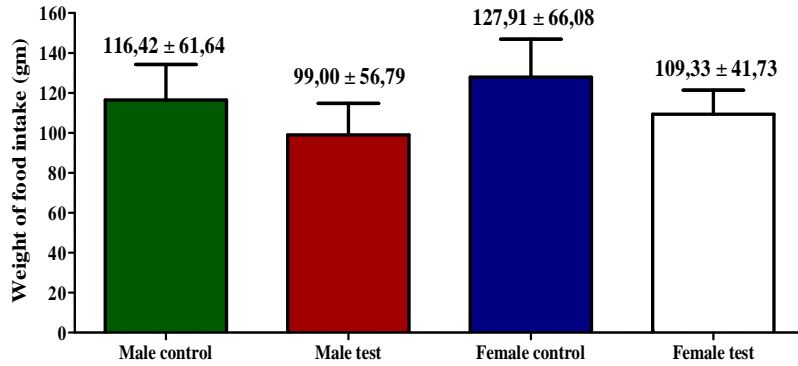


Figure 2: Weight gain by administration of Immunoboost

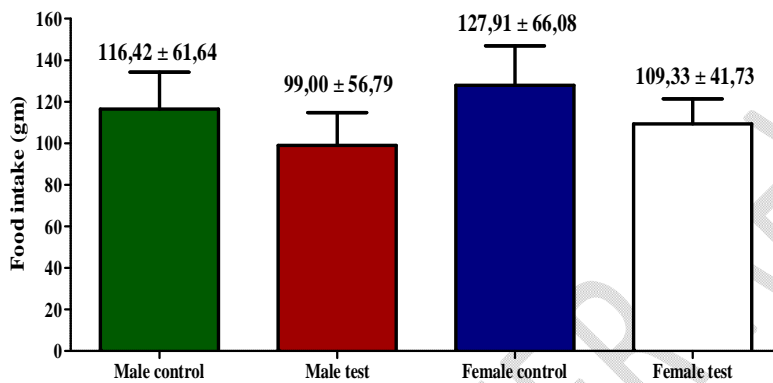


Figure 3: Evaluation of food intake

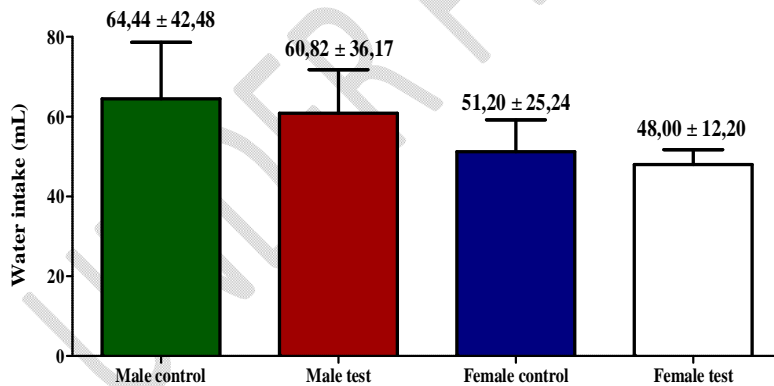


Figure 4: Evaluation of water intake.

Table 3: Effects of the extract on the internal organ weight.

Organs	Male control	Male test	Female control	Female test
Heart	0.35 ± 0.07	0.33 ± 0.06	0.37 ± 0,03	0.39 ± 0.05
Liver	5.10 ± 0.59	4.06 ± 0.65	4.05 ± 0,14	5.20 ± 0.79
Lungs	0.94 ± 0.28	1.02 ± 0.29	0.89 ± 0,21	1.12 ± 021
Brain	0.95 ± 0.05	1.08 ± 0.33	1.08 ± 0,07	1.14 ± 0.08

Spleen		1.62 ± 0.44	1.34 ± 0.28	0.66 ± 0,08	0.82 ± 0.43
	Left	0.41 ± 0.02	0.41 ± 0.08	0.43 ± 0,02	0.46 ± 0.02
Kidneys	Right	0.40 ± 0.01	0.40 ± 0.09	0.43 ± 0,02	0.46 ± 0.03
	Left	0.63± 0.09	0.63 ± 0.09	0.05 ± 0,01	0.05 ± 0.01
Testis/Ovary	Right	0.60 ± 0.17	0.54 ± 0.22	0.06 ± 0,03	0.05 ± 0.02

The results are expressed as mean ± standard deviation (n = 5). The analysis of variances are obtained from the ANOVA test, followed by the Tukey-Kramer multiple comparison test.

### Effects of the extract on liver and kidney histology.

#### Effect on liver structure

The histological analysis of the liver (figure 5) of the different groups of animals did not show any major changes in its internal structure.

#### Effect on the internal structure of the kidneys

The histology of the kidneys of both groups did not show any morphological alterations in structure (figure 6).

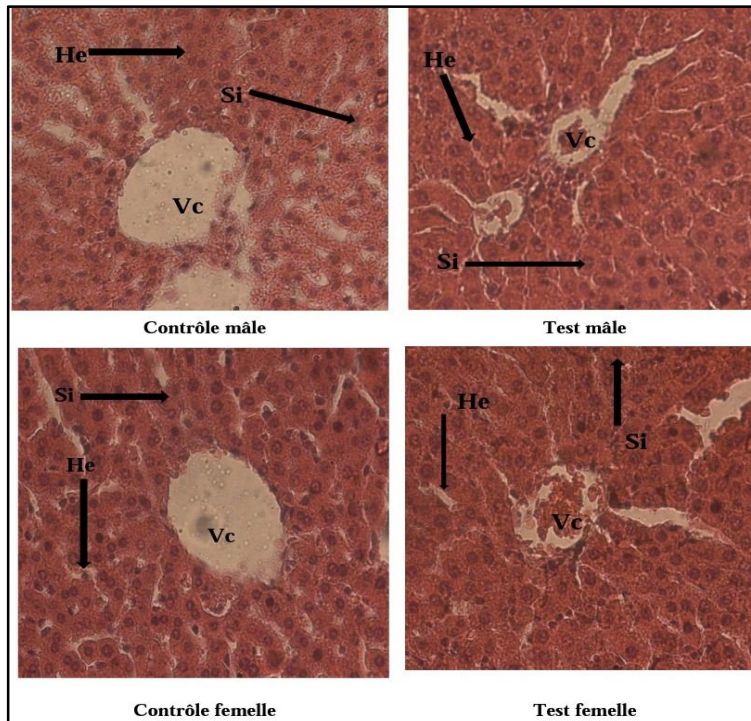
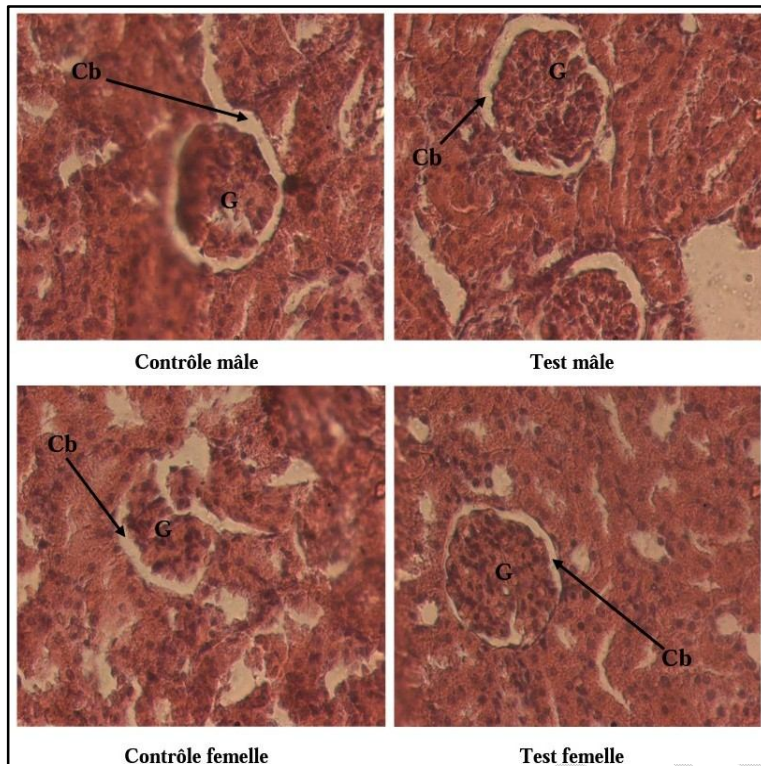


Figure 5 : Histological section of the liver of the animals in the different groups. No pathological alterations were observed. A normal architecture of the centrilobular vein (Vc), hepatocytes (He) and sinusoids (Si) is evident.



Figure 6 : Histological sections of the animals' kidneys.

When compared to the test groups (both males and females), a well-differentiated architecture can be observed, whether in the glomeruli (G), Bowman's capsule (Cb), the urinary space or the podocytes



### Effects on biochemical markers of liver and kidney damage

#### ***Effect on markers of liver injury***

Administration of the extract caused a non-significant increase ( $p$ -value  $> 0.05$ ) in AST and ALT. The AST/ALT ratio being close to 1, this indicates an absence of hepatic cytolysis (figure 7). Furthermore, the plasma protein concentration did not change significantly compared to the control group (figure 7).

#### **Effect on markers of kidney injury**

Figure 8 shows the effect of the plant on biochemical parameters of the kidney damage. The administration of the extract caused a non-significant increase with a  $p$ -value  $> 0.05$  of creatinine, urea and uric acid.

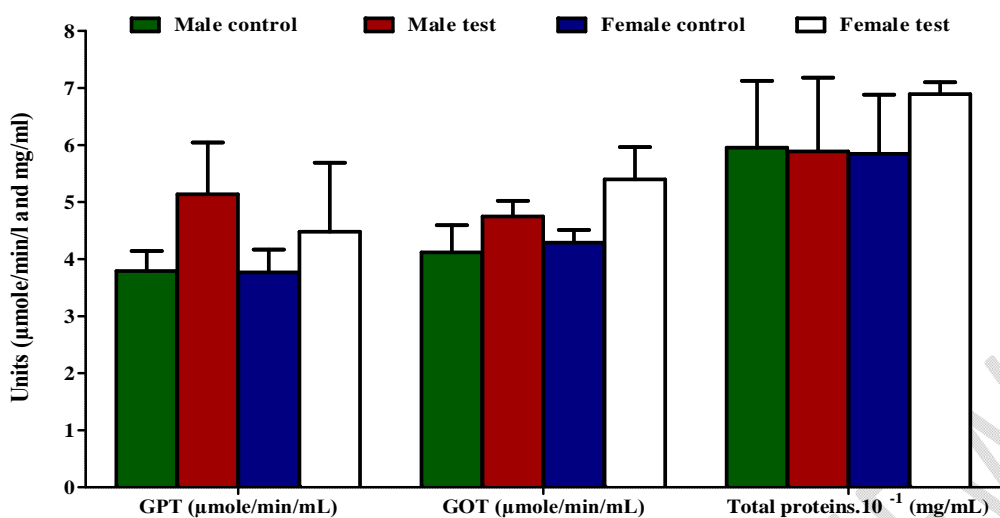


Figure 7: Effects of the extract on biochemical parameters of liver injury.

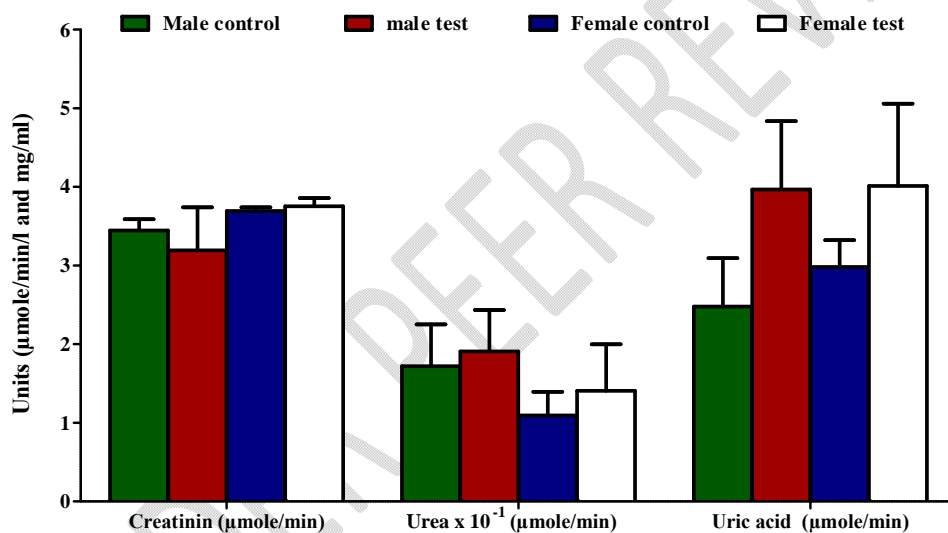


Figure 8: Effect on biochemical parameters of kidney injury

Table 4: Summary table of biochemical parameters

Parameters	Male control	Male test	Female control	Female test
AST (µmole/min/mL)	3,79 ± 0,78	5,14 ± 1,81	3,77 ± 0,89	4,48 ± 2,42
ALT (µmole/min/mL)	4,12 ± 1,06	4,75 ± 0,55	4,29 ± 0,50	5,40 ± 1,13
Proteins (mg/mL)	59,54 ± 26,18	67,21 ± 17,51	58,46 ± 23,15	68,92 ± 20,41
Creatinine (µmole/min)	3,45 ± 0,32	3,19 ± 1,10	3,69 ± 23,07	3,75 ± 38,46
Uric acid (µmole/min)	2,48 ± 1,38	3,97 ± 1,73	2,98 ± 0,77	4,01 ± 2,33
Urea (µmole/min)	17,19 ± 10,67	19,06 ± 10,58	10,94 ± 5,98	14,06 ± 11,83

The results are expressed in terms of mean  $\pm$  standard deviation ( $n = 5$ ). The analysis of variance are obtained from the ANOVA test, followed by the Tukey-Kramer multiple comparison test. The difference is significant at a  $p$ -value  $< 0.05$

## DISCUSSION

*D. edulis* is used in phytomedicine and nutrition; several studies have reported numerous pharmacological properties of its extracts (12). Moreover, the extracts contain numerous compounds such as polyphenols, tannins, flavonoids. Despite the important biological activities of these compounds, they may still be involved in some toxic effects. Thus, phenolic compounds can be haematotoxic, hepatotoxic and even carcinogenic and mutagenic(25). Therefore, an assessment of toxicity is essential. Acute toxicity tests carried out on animals in vivo provide a reliable indication of the toxicity of chemicals, as well as the nature of these effects and the exposure doses at which they occur, in order to better prevent them (26, 27). Animals were observed for 14 days after acute administration of a hydro-ethanolic leaf extract of *D. edulis* (HEE) at a single dose of 2000 mg/kg and no deaths were recorded as mortality is one of the main toxicity endpoints (28).

During the 14 day experimental period of observation the rat did not exhibit any change in the physical appearance such as in the skin and fur, eyes, and mucous membranes. Furthermore, there were no signs of abnormal changes in the behavioral pattern, injury, or enduring signs of severe distress among the rats, including irritability, tremors, lethargy, sleep, coma, convulsion and diarrhoea, respectively. Other clinical signs of toxicity were recorded (weight, food intake, water intake, etc). Indeed, the increase or decrease in body weight indicates more or less important physiological changes such as variations in liver disorders, decrease in the absorption of biomolecules (proteins, amino acids and other nutrients), hormonal variations (29). On the other hand, the decrease in body weight can affect the internal organ weight (30) and is a basic and sensitive indicator of toxicity (31). In this study, the result showed that the relative weight of vital organs such as heart, liver, spleen, kidney and lung of all treated groups did not differ significantly ( $p > 0.05$ ) from those of controls. Similar results were also obtained by Araujo *et al* (28) and Ononamadu *et al* (32).

The liver is the main organ involved in the metabolism and biotransformation of xenobiotics. It is therefore the major target of many drugs and foreign substances that enter the body. Thus, this organ can be the subject of various types of lesions due to the presence of these foreign bodies. These injuries most often lead to an overproduction of proteins and liver enzymes (33). Thus, the evaluation of biochemical parameters of liver function including enzymes (AST, ALT and PAL) and metabolites (proteins) allows the appreciation of the functional integrity of the liver after an acute exposure to xenobiotics (34). Transaminases (ALT and AST) are enzymes of carbohydrate and amino acid metabolism while alkaline phosphatase (PAL) is involved in the hydrolysis of phosphate bonds. They are often used to assess the functional integrity of the liver, plasma membrane and endoplasmic reticulum (35). ALT is particularly considered to be the most specific marker of hepatocellular injury as it is mainly stored in the liver in contrast to AST which is also found abundantly in various other organs (kidneys, brain, heart) (36). An increase in serum ASAT and ALAT enzyme activity directly reflects hepatocellular damage (37).

In this study, no significant difference ( $p < 0.05$ ) was observed in the activities of these enzymes in all animals treated with 2000mg/kg extract compared to controls (table 4). Furthermore, serum total protein levels were also not significantly changed compared to controls. This suggests that the extract did not affect the ability of the liver to produce protein. These results imply that the extract is harmless and has no harmful effect on liver tissue. It should be noted the serum protein levels are regulated by synthesis in the liver and therefore these levels directly reflect the synthesis capacity of this vital organ. An increase in total protein leads to dehydration which disrupts overall homeostasis (38). The kidneys receive about 25% of the cardiac blood flow and all xenobiotics that pass through the bloodstream reach this organ. They are therefore considered targets of toxicity as is the liver (39). The kidneys control the excretion of urea, creatinine and the reabsorption of electrolytes into the blood. Failure of renal activity will result in an accumulation of electrolytes, urea and creatinine in the body fluid (40). Indeed, creatinine concentration is widely considered to be a measure of glomerular filtration rate and is used in clinical practice as one of the main indicators of renal function (41). Administration of the 2000mg/kg extract had no significant effect on plasma creatinine concentration ( $p < 0.05$ ). On the other hand, a significant increase was observed in urea and uric acid; the latter being related to kidney

diseases and urinary tract problems, the increase observed here does not systematically reflect a toxic effect of the extract. These biochemical results corroborate well with the histopathological observations made on the kidney and liver, as histopathological analysis is the gold standard for assessing the pathological changes induced by the administration of a plant extract on tissues or organs (42). Both organs (liver and kidney) showed normal tissues compared to the control; this is an indicator that the structural and functional integrity of these organs was not affected. These results confirm those of Ononamadu *et al* (2020) (32) and Aponjolosun *et al* (2022) (16) who although working with methanolic extracts, observed no damage to vital organs at doses above 2000mg/kg.

## CONCLUSION

The toxicity study of ethanolic leaf extract of *D. edulis* at 2000mg/kg showed no mortality and during the 14-day experimental period of observation, the rats did not exhibit any change in the physical appearance. Moreover, there were no signs of abnormal changes in the behavioral pattern. Furthermore, the biochemical and histological examination of the liver, and kidneys did not show any differences between the control and the test groups. With this, the hydro-ethanolic extract was found to be safe at 2000mg/kg, p.o. according to the 423 OECD Guidelines.

## Ethical Approval:

This was a preclinical study approved by the scientific committee of the Department of Biochemistry and with adherence to the OECD guideline 423 for conduct of animal studies on oral administration of xenobiotics.

## ACKNOWLEDGEMENTS

The authors would like to thank the team of the laboratory of preclinical animal studies and pharmaco-toxicology of the Faculty of Medicine and Biomedical Sciences of the University of Yaoundé 1 where this work was carried out.

## CONFLICTS OF INTEREST

The authors declare no conflict of interest.

### Authors' contributions

This work was carried out in collaboration among all authors. Authors NH, TEF, CF, designed the study, wrote the protocol, and wrote the first draft of the manuscript. Authors NH, BH, NNB, WB managed the analyses of the study; data mining performed the statistical analysis, and the specified literature searches. All authors read and approved the final manuscript.

### Funding.

This work was funded by the teachers' research mobilization grant of the Ministry of Higher Education (MINESUP), Cameroon, with private financial support of project from the Nomo Honore family.

## REFERENCES

1. Yuan H, Ma Q, Ye L, Piao G. The Traditional Medicine and Modern Medicine from Natural Products. *Molecules* [Internet]. mai 2016 [cité 10 nov 2022];21(5):559. Disponible sur: <https://www.mdpi.com/1420-3049/21/5/559>
2. Mythilypriya R, Shanthy P, Sachdanandam P. Oral Acute and Subacute Toxicity Studies with Kalpaamruthaa, a Modified Indigenous Preparation, on Rats. *Journal of Health Science*. 2007;53(4):351-8.
3. Han CT, Kim MJ, Moon SH, Jeon YR, Hwang JS, Nam C, et al. Acute and 28-Day Subacute Toxicity Studies of Hexane Extracts of the Roots of *Lithospermum erythrorhizon* in Sprague-

- Dawley Rats. Toxicological Research [Internet]. 2015 [cité 10 nov 2022];31(4):403-414. Disponible sur: <http://koreascience.or.kr/article/JAKO201502150665866.page>
4. Li Y, Kandhare AD, Mukherjee AA, Bodhankar SL. Acute and sub-chronic oral toxicity studies of hesperidin isolated from orange peel extract in Sprague Dawley rats. Regulatory Toxicology and Pharmacology [Internet]. 1 juill 2019 [cité 10 nov 2022];105:77-85. Disponible sur: <https://www.sciencedirect.com/science/article/pii/S0273230019300923>
  5. Aydın A, Aktay G, Yesilada E. A Guidance Manual for the Toxicity Assessment of Traditional Herbal Medicines. Natural Product Communications [Internet]. 1 nov 2016 [cité 10 nov 2022];11(11):1934578X1601101131. Disponible sur: <https://doi.org/10.1177/1934578X1601101131>
  6. Araújo MC de PM, Barcellos NMS, Vieira PM de A, Gouveia TM, Guerra MO, Peters VM, et al. Acute and sub chronic toxicity study of aqueous extract from the leaves and branches of *Campomanesia velutina* (Cambess) O. Berg. Journal of Ethnopharmacology [Internet]. 6 avr 2017 [cité 10 nov 2022];201:17-25. Disponible sur: <https://www.sciencedirect.com/science/article/pii/S0378874116315410>
  7. Hazarika I, Geetha KM, Sundari PS, Madhu D. Acute oral toxicity evaluation of extracts of *Hydrocotyle sibthorpioides* in wister albino rats as per OECD 425 TG. Toxicology Reports [Internet]. 1 janv 2019 [cité 10 nov 2022];6:321-8. Disponible sur: <https://www.sciencedirect.com/science/article/pii/S2214750019300411>
  8. Han JS, Lee BS, Han SR, Han HY, Chung MK, Min BS, et al. A subchronic toxicity study of *Radix Dipsaci* water extract by oral administration in F344 rats. Regulatory Toxicology and Pharmacology [Internet]. 1 nov 2016 [cité 10 nov 2022];81:136-45. Disponible sur: <https://www.sciencedirect.com/science/article/pii/S0273230016302070>
  9. Balogun FO, Tom Ashafa AO. Acute and Subchronic Oral Toxicity Evaluation of Aqueous Root Extract of *Dicoma anomala* Sond. in Wistar Rats. Evidence-Based Complementary and Alternative Medicine [Internet]. 13 avr 2016 [cité 10 nov 2022];2016:e3509323. Disponible sur: <https://www.hindawi.com/journals/ecam/2016/3509323/>
  10. Onana JM. A synoptic revision of *Dacryodes* (Burseraceae) in Africa, with a new species from Central Africa. Kew Bull [Internet]. 1 sept 2008 [cité 10 nov 2022];63(3):385-400. Disponible sur: <https://doi.org/10.1007/s12225-008-9064-4>
  11. Tee LH, Yang B, Nagendra KP, Ramanan RN, Sun J, Chan ES, et al. Nutritional compositions and bioactivities of *Dacryodes* species: A review. Food Chemistry [Internet]. 15 déc 2014 [cité 10 nov 2022];165:247-55. Disponible sur: <https://www.sciencedirect.com/science/article/pii/S0308814614008000>
  12. Olivier TT, Moñse F, Jackson SA, Francis NT. A review on traditional uses, phytochemical and pharmacological profiles, spiritual and economic values, and toxicity of *dacryodes edulis* (G. DON) H.J. LAM. Journal of Drug Delivery and Therapeutics [Internet]. 12 sept 2016 [cité 19 juin 2021];6(5):84-90. Disponible sur: <http://www.jddtonline.info/index.php/jddt/article/view/1276>
  13. *Dacryodes edulis* (G. Don) H.J. Lam [Internet]. [cité 29 oct 2022]. Disponible sur: [https://www.prota4u.org/database/protav8.asp?fr=1&g=pe&p=Dacryodes+edulis+\(G.Don\)+H.J.Lam](https://www.prota4u.org/database/protav8.asp?fr=1&g=pe&p=Dacryodes+edulis+(G.Don)+H.J.Lam)
  14. Jirovetz L, Buchbauer G, Stoyanova AS, Georgiev EV, Damianova ST. Composition, Quality Control, and Antimicrobial Activity of the Essential Oil of Long-Time Stored Dill (*Anethum graveolens* L.) Seeds from Bulgaria. J Agric Food Chem [Internet]. 1 juin 2003 [cité 10 nov 2022];51(13):3854-7. Disponible sur: <https://doi.org/10.1021/jf030004y>
  15. Wego Kamgaing MT, Mvondo MA, Poualeu Kamani SL, Minko Essono S, Wansi Ngnokam SL. The Aqueous Extract of *Dacryodes edulis* (Burseraceae) Leaves Inhibits Cell Proliferation Induced by Estradiol on the Uterus and Vagina of Ovariectomized Female Wistar Rats. Advances in Pharmacological and Pharmaceutical Sciences [Internet]. 21 nov 2020 [cité 15 sept 2021];2020:e8869281. Disponible sur: <https://www.hindawi.com/journals/aps/2020/8869281/>
  16. Aponjolosun BS, Fasola TR. Phytochemical, Antimicrobial and Toxicity Assessment of *Dacryodes edulis* (G. Don.) H. J. Lam. Leaf Extracts. African Journal of Biomedical Research

- [Internet]. 31 janv 2022 [cité 19 juin 2022];25(1):101-106. Disponible sur: <http://ojshosting.com/index.php/ajbr/article/view/227>
17. Ononamadu CJ, Alhassan AJ, Ibrahim A, Imam AA, Ihegboro GO, Owolarafe TA, et al. Methanol-Extract/Fractions of *Dacryodes edulis* Leaves Ameliorate Hyperglycemia and Associated Oxidative Stress in Streptozotocin-Induced Diabetic Wistar Rats. *J Evid Based Complementary Altern Med* [Internet]. 1 janv 2019 [cité 7 sept 2021];24:2515690X19843832. Disponible sur: <https://doi.org/10.1177/2515690X19843832>
  18. Erukainure OL, Mopuri R, Oyebode OA, Koorbanally NA, Islam MdS. *Dacryodes edulis* enhances antioxidant activities, suppresses DNA fragmentation in oxidative pancreatic and hepatic injuries; and inhibits carbohydrate digestive enzymes linked to type 2 diabetes. *Biomedicine & Pharmacotherapy* [Internet]. 1 déc 2017 [cité 6 juin 2022];96:37-47. Disponible sur: <https://www.sciencedirect.com/science/article/pii/S0753332217329736>
  19. Ononamadu CJ, Alhassan AJ, Ibrahim A, Imam AA, Ihegboro GO, Owolarafe AT, et al. Toxicological study of aqueous-methanol solvent fraction of methanol extract of *Dacryodes edulis* leaves. *Toxicol Rep.* 2020;7:909-18.
  20. Ufelle S, Ukaejiofo E, Achukwu P, Eluke B, Ghasi S, Neboh E. Potential Haemopoietic Effects of *Dacryodes Edulis* Seeds Extract in Wistar Rats. 1 mai 2015;3:2348-5728.
  21. Marcano L, Hasenawa D. Analysis of phytochemicals in leaves and seeds. *Agronomy Journal.* 1991;83:445-52.
  22. Harborne AJ. *Phytochemical Methods A Guide to Modern Techniques of Plant Analysis.* Springer Science & Business Media; 1998. 504 p.
  23. OECD. Test No. 423: Acute Oral toxicity - Acute Toxic Class Method [Internet]. Paris: Organisation for Economic Co-operation and Development; 2002 [cité 10 mars 2023]. Disponible sur: [https://www.oecd-ilibrary.org/environment/test-no-423-acute-oral-toxicity-acute-toxic-class-method\\_9789264071001-en](https://www.oecd-ilibrary.org/environment/test-no-423-acute-oral-toxicity-acute-toxic-class-method_9789264071001-en)
  24. Papanicolaou (PAP) Staining: Introduction, Principle, Procedure and Interpretation - Laboratoryinfo.com [Internet]. 2021 [cité 13 nov 2022]. Disponible sur: <https://laboratoryinfo.com/papanicolaou-pap-staining-principle-procedure-interpretation/>
  25. Michałowicz J, Duda W. Phenols – Sources and Toxicity. :16.
  26. Kim HY, Zuo G, Lee SK, Lim SS. Acute and subchronic toxicity study of nonpolar extract of licorice roots in mice. *Food Sci Nutr.* mai 2020;8(5):2242-50.
  27. Rojas-Armas J, Arroyo-Acevedo J, Ortiz-Sánchez M, Palomino-Pacheco M, Castro-Luna A, Ramos-Cevallos N, et al. Acute and Repeated 28-Day Oral Dose Toxicity Studies of *Thymus vulgaris* L. Essential Oil in Rats. *Toxicological Research* [Internet]. 15 juill 2019 [cité 13 nov 2022];35(3):225-32. Disponible sur: <http://www.toxicolres.org/journal/view.html?doi=10.5487/TR.2019.35.3.225>
  28. Araújo MC de PM, Barcellos NMS, Vieira PM de A, Gouveia TM, Guerra MO, Peters VM, et al. Acute and sub chronic toxicity study of aqueous extract from the leaves and branches of *Campomanesia velutina* (Cambess) O. Berg. *Journal of Ethnopharmacology* [Internet]. 6 avr 2017 [cité 13 nov 2022];201:17-25. Disponible sur: <https://www.sciencedirect.com/science/article/pii/S0378874116315410>
  29. Lee MY, Shin IS, Seo CS, Kim JH, Han SR, Shin HK. Subchronic oral toxicity studies of the traditional herbal formula Bangpungtongseong-san in Crl: CD (SD) rats. *Journal of Ethnopharmacology* [Internet]. 18 déc 2012 [cité 13 nov 2022];144(3):720-5. Disponible sur: <https://www.sciencedirect.com/science/article/pii/S0378874112006915>
  30. Teo S, Stirling D, Thomas S, Hoberman A, Kiorpes A, Khetani V. A 90-day oral gavage toxicity study of d-methylphenidate and d,l-methylphenidate in Sprague–Dawley rats. *Toxicology* [Internet]. 15 oct 2002 [cité 13 nov 2022];179(3):183-96. Disponible sur: <https://www.sciencedirect.com/science/article/pii/S0300483X02003384>
  31. Thanabhorn S, Jaijoy K, Thamaree S, Ingkaninan K, Panthong A. Acute and subacute toxicity study of the ethanol extract from *Lonicera japonica* Thunb. *J Ethnopharmacol.* 11 oct 2006;107(3):370-3.
  32. Ononamadu CJ, Alhassan AJ, Ibrahim A, Imam AA, Ihegboro GO, Owolarafe AT, et al. Toxicological study of aqueous-methanol solvent fraction of methanol extract of *Dacryodes edulis* leaves. *Toxicol Rep.* 2020;7:909-18.

33. Joseph IE, Jaja IF, Boyi AH, Olugbenga OM. Comparative effects of methanol and oil extracts of *Ocimum gratissimum* on testicular morphology and epididymal sperm reserve of adult male albino rats (Wistar strain). *Toxicology Reports* [Internet]. 1 janv 2019 [cité 14 nov 2022];6:1127-34. Disponible sur: <https://www.sciencedirect.com/science/article/pii/S2214750019301301>
34. Airaodion A, John A, Ogbuagu E, Atiba F, Olawoyin D. Nephro and Hepatotoxic Effect of Air-Freshener in Wistar Rats. 30 juill 2020;1-9.
35. Airaodion A, Ogbuagu E, Ogbuagu U, Odefemi A, Agunbiade A, Airaodion E. Hepatoprotective Effect of *Parkia biglobosa* on Acute Ethanol-induced Oxidative Stress in Wistar Rats. 17 juin 2019;2:1-11.
36. Airaodion A, Ngwogu A, Ekenjoku J, Ngwogu K. Hepatoprotective Potency of Ethanolic Extract of *Garcinia kola* (Heckel) Seed against Acute Ethanol-Induced Oxidative Stress in Wistar Rats. 30 janv 2020;1-10.
37. Ogbuagu E, Airaodion A, Ogbuagu U, Airaodion E. Prophylactic Propensity of Methanolic Extract of *Vernonia amygdalina* Leaves against Acute Ethanol-Induced Oxidative Stress in Wistar Rats. 24 juill 2019;11:37-46.
38. Ogbuagu E, Unekwe P, Airaodion A, Nweke I, Ogbuagu U. Hepatotoxic effect of *Xylopia aethiopica* Fruit in Wistar Rats. 16 janv 2021;1-16.
39. Yuet Ping K, Darah I, Chen Y, Sreeramanan S, Sasidharan S. Acute and Subchronic Toxicity Study of *Euphorbia hirta* L. Methanol Extract in Rats. *BioMed Research International* [Internet]. 10 déc 2013 [cité 10 nov 2022];2013:e182064. Disponible sur: <https://www.hindawi.com/journals/bmri/2013/182064/>
40. Akunne PN, Orhue NEJ. Investigation of the toxicity of aqueous and methanol extracts of *Dacryodes edulis* seed on Wistar rats. *International Journal of Science Academic Research*. 2021;5:2.
41. Silva-Correa CR, Villarreal-La Torre VE, González-Siccha AD, Cruzado-Razco JL, González-Blas MV, Sagástegui-Guarniz WA, et al. Acute toxicity of aqueous extract of *Ambrosia arborescens* Mill. on biochemical and histopathological parameters in rats. *Toxicol Res* [Internet]. 1 avr 2022 [cité 10 nov 2022];38(2):225-33. Disponible sur: <https://doi.org/10.1007/s43188-021-00106-0>
42. Neergheen-Bhujun VS. Underestimating the Toxicological Challenges Associated with the Use of Herbal Medicinal Products in Developing Countries. *BioMed Research International* [Internet]. 19 sept 2013 [cité 10 nov 2022];2013:e804086. Disponible sur: <https://www.hindawi.com/journals/bmri/2013/804086/>