

## Case report

### **Ureteric transection with jejunal injury secondary to bicycle handle bar penetrating injury.**

#### **Abstract:**

**Background:** Ureteric trauma is rare, occurring in <1% of all traumas. Bicycle handlebar injury is a unique trauma mechanism especially noticed in childhood.

**Case presentation:** We present a unique case of a 13-year-old male who sustained a penetrating abdominal injury from a bicycle handlebar. Upon initial examination there was herniation of bowel through the abdominal wound, so exploratory laparotomy was performed. There was transection of the jejunum at a distance of 10 cm from the duodeno-jejunal flexure with more than 75 % of the circumference of the jejunum and evidence of tear of Gerota's fascia of left kidney and upon exploration of the retroperitoneum, there was transection of the upper one third of left ureter near the left renal pelvis with foreign body (child's cloth remnant) seen which was initially managed by placement of an infant feeding tube as a bridge between the two transected ends owing to a defect of 3 cm as a temporary emergency salvage procedure. He then underwent percutaneous nephrostomy insertion. After 3 months, patient underwent definitive repair by left sided pyeloureterostomy over a DJ stent.

**Conclusion:** This case demonstrates the emergency and delayed definitive management of ureteric transection and jejunal injury secondary to penetrating bicycle handlebar injury.

#### **Keywords:**

Ureter, jejunal, bicycle, handlebar, penetrating.

#### **Background:**

Penetrating abdominal trauma secondary to bicycle handlebars is rare. Most reports regarding handlebar injuries in the literature are related to traumatic abdominal wall hernias, solid organ injury, or bowel injury.<sup>1-5</sup> Likewise, ureteric injury related to external trauma is also rare, with even the busiest adult trauma centres typically seeing fewer than 10 cases per year.<sup>6</sup> We present a unique case of ureteric transection and jejunal injury secondary to bicycle handlebar injury.

#### **Case presentation:**

An otherwise healthy 13-year-old male presented to the emergency department after a bicycle accident. Primary survey revealed tachycardia, hypotension and Glasgow Coma Score of 10. Secondary survey was remarkable for a deep 3-centimetre (cm) laceration in the left lower quadrant. There was active bleeding from the wound, with bowel herniating through a fascial defect. Given these findings the patient was brought to the operating room for exploration. An exploratory laparotomy was performed via midline abdominal incision. The underlying fascial defect was found to be approximately 5 cm. There was transection of the jejunum at a distance of 10 cm from the duodeno-jejunal flexure with more than 75 % of the circumference of the jejunum and evidence of tear of Gerota's fascia of left kidney and upon exploration of the retroperitoneum, there was transection of the upper one third of left ureter near the left renal pelvis with foreign body (child's cloth remnant) seen. The jejunal injury

was repaired after resecting the injured segment and then handsewn anastomosis done using vicryl 3-0. The ureteric transection was initially managed by placement of a 6 Fr infant feeding tube as a bridge between the two transected ends owing to a defect of 3 cm as a temporary emergency salvage procedure as the patient was haemodynamically unstable. The complex abdominal wall injury was repaired primarily after placing a 32 Fr abdominal drain. Postoperatively after the patient's condition improved, he underwent Computerised Intravenous pyelography (CT-IVP) which showed a small leak near the repaired left ureter (see figures-1a-d).

So, the patient underwent ultrasound guided left sided percutaneous nephrostomy insertion after cystoscopy with retrograde pyelography also confirmed the leak from the left ureter (see figure-2). Patient was discharged after 4 weeks with percutaneous nephrostomy in situ. After 3 months of the accident, patient was then planned for a definitive surgery. Patient underwent definitive surgery through a left subcostal incision and identifying the left ureter with removal of the infant feeding tube and then ureteropyelostomy after adequate mobilisation of the left kidney and left ureter using 3-0 polydioxanone (PDS) suture over a double-J stent and a drain left in place in the retroperitoneum (Figure-03-intraoperative image). Post-operatively the patient recovered well and was discharged five days later after the operative drain was removed. The double-J stent was removed at postoperative week six with concurrent cystoscopy and retrograde ureterogram demonstrating a normal ureter with no evidence of stricture.

### **Discussion:**

According to our review of literature, most bicycle-related incidents described in the literature deal with head trauma. Handlebar injury is also an important mechanism of bicycle-related trauma, and the associated morbidity is underappreciated. Most cases described in the literature are secondary to blunt trauma. The most common injuries described include bowel perforation, solid organ injury, and traumatic abdominal wall hernia.<sup>1-5</sup> There are no studies on penetrating injuries in case of bicycle handlebar injuries. In a retrospective review by Nadler et al.,<sup>3</sup> 31% of children sustaining direct-impact handlebar injuries required operative intervention. Ureteric injuries account for <1% of all urologic traumas,<sup>7</sup> with the majority being a result of penetrating trauma. Table 1 data compiled from the National Trauma Database shows the varying mechanisms of ureteric injury.<sup>8</sup> The diagnosis and management of ureteric injury is challenging and often delayed or missed. A retrospective review of traumatic ureteric injury by Medina et al. found that only 40% of patients with ureteric injury had positive findings on preoperative imaging studies<sup>9</sup>. Computed tomography with delayed phase images must be included if there is any suspicion of ureteric injury. Cystoscopy with retrograde ureterogram/pyelogram is the most accurate way of identifying ureteric injury, but may not be feasible if patient is hemodynamically unstable. Due to a high rate of concomitant injuries many ureteric injuries are diagnosed intra-operatively during exploration for other reasons. This can pose a challenge for the surgeon as haemorrhage or spillage of intestinal contents can make detecting leakage of a small amount of urine difficult. The possibility of ureteric injury should be suspected if there is violation of retroperitoneum. Approximately 60% of injuries occur in the proximal ureter<sup>10</sup>. In emergency setting if the patient is haemodynamically unstable, a unique approach of placing infant feeding tube as a bridge was used in our study. The type of operative repair varies depends on the location of the injury. Regardless of the location of injury, the basic tenets of repair always involve debridement to healthy tissue and tension-free anastomosis over a stent with absorbable suture. In our patient, a unique approach of placing an infant feeding tube to bridge the ureteric defect was

used as a temporary measure as the patient was haemodynamically unstable. He did undergo a definitive repair after a period of 3 months and it was successful. Thus, this case report does add a unique perspective of emergency management of ureteric injuries.

### **Conclusion:**

A high index of suspicion is necessary for timely diagnosis of ureteric injuries. Intra-operative discovery of retroperitoneal violation warrants further exploration, with identification of ureteric trauma prompting an appropriate repair based on the location of the injury. However, in an emergency setting with hemodynamic instability, novel approaches like placing an infant feeding tube to bridge the large ureteric defect can be used to tide over the crisis.

### **List of abbreviations:**

DJ stent - Double-J stent.

i.v. - Intravenous.

PDS - Polydioxanone

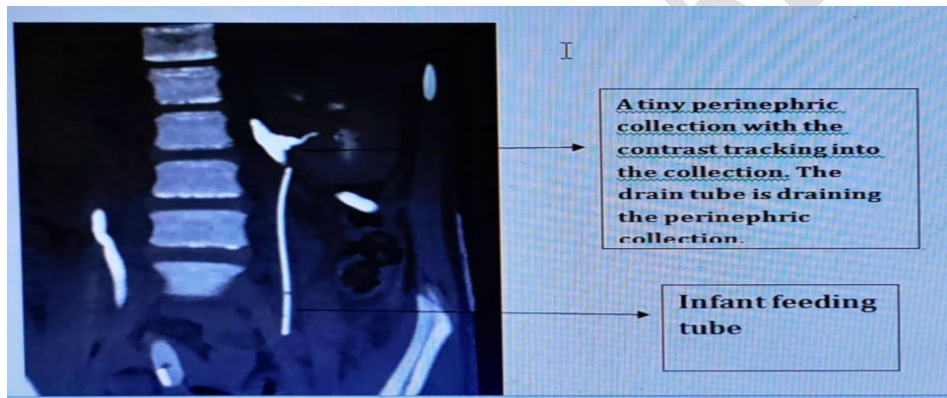
### **References:**

1. K.P. Debbink, D.B. Tashjian, M.V. Tirabassi, R. Gaffey, J. Nahmias; Ureteric transection secondary to penetrating handlebar injury, *Trauma Case Reports*, Volume 10, 2017, Pages 16-18, ISSN 2352-6440, <https://doi.org/10.1016/j.tcr.2017.07.002>.
2. Karaman, A. Karaman, M.K. Aslan, D. Erdoğan, Y.H. Cavuşoğlu, O. Tütün, A hidden danger of childhood trauma: bicycle handlebar injuries, *Surg. Today* 39 (7) (2009) 572–574.
3. E.P. Nadler, D.A. Potoka, B.L. Shulz, K.E. Morrison, H.R. Ford, B.A. Gaines, The high morbidity associated with handlebar injuries in children, *J. Trauma* 58 (6) (2005) 1171–1174.
4. J. Goliath, V. Mittal, J. McDonough, Traumatic handlebar hernia: a rare abdominal wall hernia, *J. Pediatr. Surg.* 39 (10) (2004) 20–22.
5. T.D. Clarnette, S.W. Beasley, Handlebar injuries in children: patterns and prevention, *Aust. N. Z. J. Surg.* 67 (6) (1997) 338.
6. S.B. Brandes, M.J. Chelsky, R.F. Buckman, R.M. Hanno, Ureteral injuries from penetrating trauma, *J. Trauma* 36 (6) (1994) 766–769
7. J.C. Presti Jr., P.R. Carroll, J.W. McAninch, Ureteral and renal pelvic injuries from external trauma: diagnosis and management, *J. Trauma* 29 (3) (1989) 370–374.
8. S.M. Siram, S.Z. Gerald, W.R. Greene, et al., Ureteral trauma: patterns and mechanisms of injury of an uncommon condition, *Am. J. Surg.* 199 (2010) 566–570.
9. D. Medina, R. Lavery, S.E. Ross, D.H. Livingston, Ureteral trauma: preoperative studies neither predict injury nor prevent missed injuries, *J. Am. Coll. Surg.* 186 (1998) 641–644.
10. Pereira BMT, M.P. Ogilvie, J.C. Gomez-Rodriguez, et al., A review of ureteral injuries after external trauma, *Scand. J. Trauma* 18 (6) (2010).

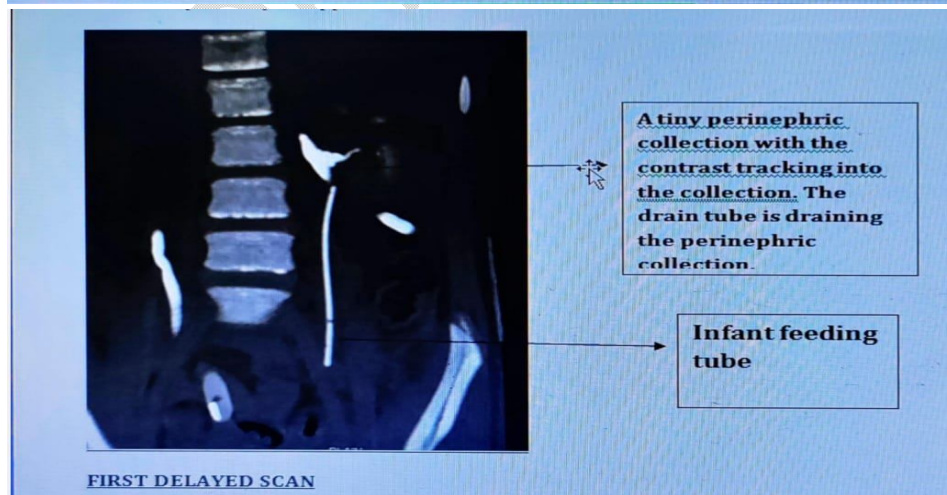
**Figure Legends:**

Figure-1a	CT IVP image
Figure-1b	First delayed scan CT IVP
Figure-1c	Second delayed scan-CT IVP image after clamping the drain tube.
Figure-1d	Reconstructed CT-IVP image showing left sided repaired ureteric injury by a bridging IFT and leakage of contrast through the distal part of the repair into the left perinephric drain
Figure-02	Left sided RGP image confirming leakage
Figure-03	Intraoperative image showing left ureteropyelostomy after adequate mobilisation of the left kidney and left ureter using 3-0 polydioxanone (PDS) suture over a double-J stent.
Table-1	Mechanism of ureteric injury
Table-2	Pertinent reconstructive option for repair of ureteric injury; based on location

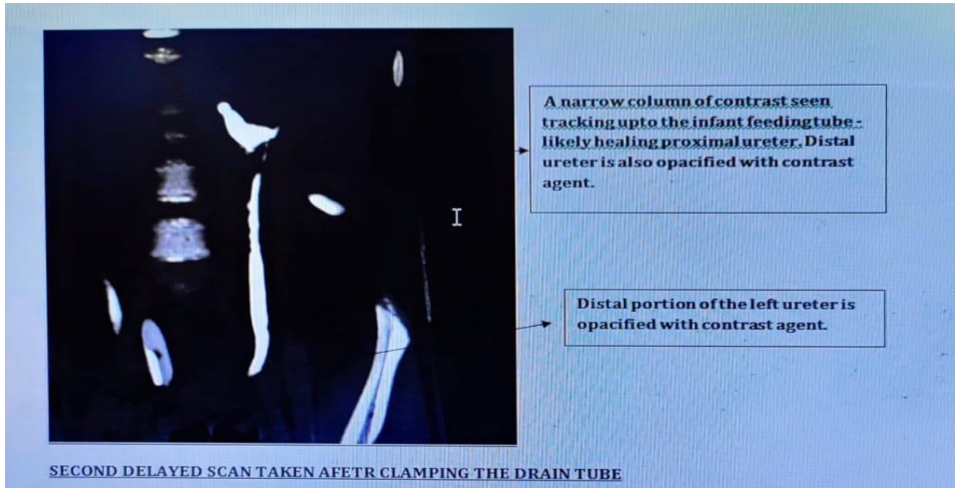**Figures:**



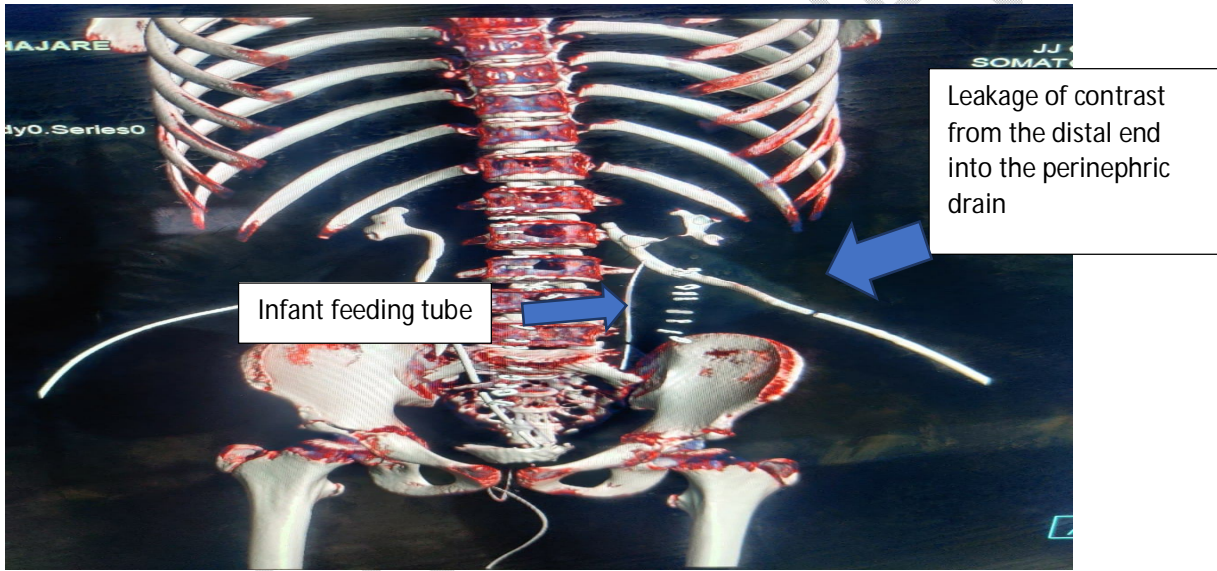
**Figure-1a**



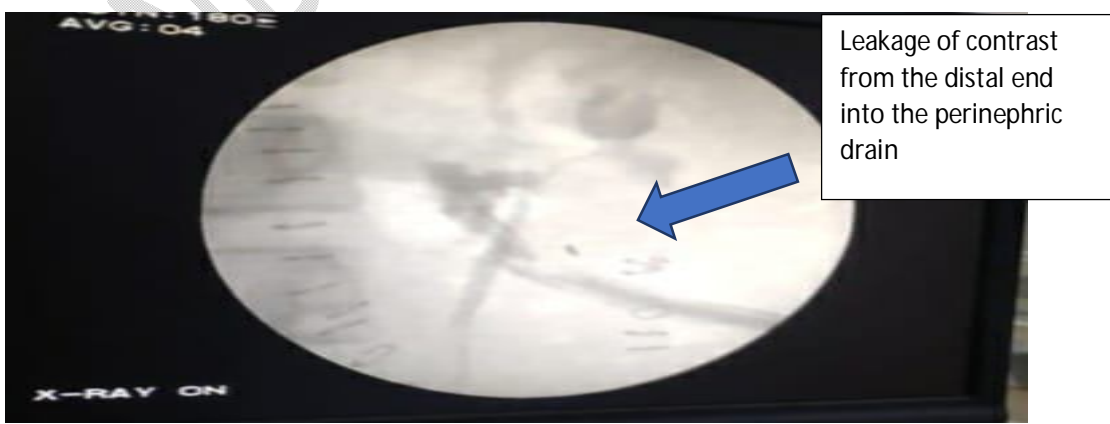
**Figure-1b**



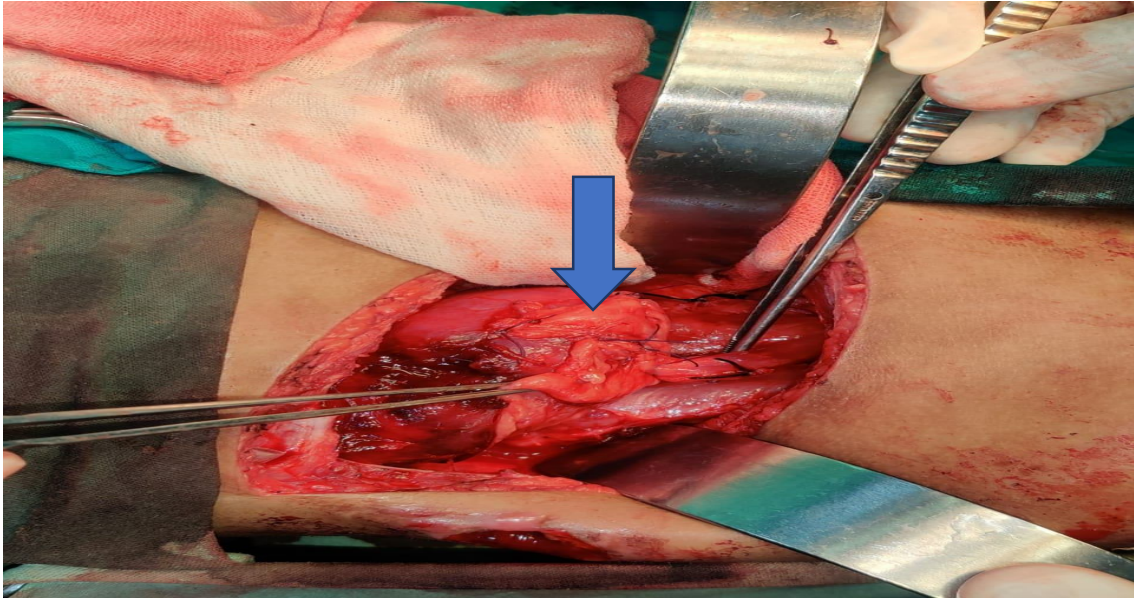
**Figure-1c**



**Figure-1d**



**Figure-02**



**Figure-03**

**Table 1**  
Mechanism of ureteric injury.

	n	% of total cases
Blunt trauma	224	38
Motor vehicle collision	110	19
Pedestrian	25	4
Motorcyclist	18	3
High fall	15	3
Low fall	8	1
Cyclist	3	<1
Other	45	8
Penetrating trauma	358	62
Gunshot wound	316	54
Stab	29	5
Other	13	2

**Table 2**  
Pertinent reconstructive options, based on location.

Upper third	Uretero-ureterostomy Ureteropyelostomy
Middle third	Uretero-ureterostomy Transuretero-ureterostomy Anterior wall bladder flap (Boari)
Lower third	Ureteroneocystostomy (direct reimplantation) Ureteroneocystostomy (psoas hitch)