

1
2 **Small bowel obstruction by a Primary flange on**
3 **mesenteric ganglionic tuberculosis :**
4 **A case report**
5
6
7
8
9
10

11 **ABSTRACT**
12

Tuberculosis remains a global public health issue. Lymph node tuberculosis is one of the most common extrapulmonary manifestations of tuberculosis, Mesenteric lymph node tuberculosis is rare and difficult to treat. It is revealed by intestinal obstruction in 20-27% of cases .
Knowing how to evoke the diagnosis of tuberculosis is the indispensable condition for rapid and adapted management. The surgical treatment is not standardized and depends primarily on the reason for the surgical indication.
We present a rare case of a Small bowel obstruction by a Primary flange on mesenteric ganglionic tuberculosis, who benefited from a surgical cure.

13
14 *Keywords: tuberculosis, flange, small bowel , mesenteric ganglionic*
15
16
17

18 **1. INTRODUCTION**

19 Tuberculosis has recently resurged as a worldwide public health concern in spite of the
20 recent advances in its diagnosis and management [1].. This is thought to be because of the poor hygiene conditions, the
21 greater prevalence of acquired immune deficiency syndrome (AIDS) and depression of the immune system [2]..
22 Tuberculosis is an infectious disease caused by Mycobacterium tuberculosis, an acid-fast bacillus that is transmitted
primarily through the respiratory tract and undergoes lymphohematogenous dissemination [1].

23 Atypical extrapulmonary presentations of this infection may significantly delay its diagnosis and management.
24 Tuberculous lymphadenitis (TL) is an extrapulmonary manifestation of a Mycobacterium tuberculosis infection. It is
25 characterized by necrotizing mycobacterial infection of the lymph nodes. The clinical presentation of this disease ranges
26 from fever and malaise to cervical lymphadenopathy and fistula formation. The purpose of this study is to acquaint
27 physicians to identify this disease in a timely manner [4].

28 We report the case of intestinal occlusion caused by primary flange of mesenteric ganglionic tuberculosis .
29

30 **2. CASE PRESENTATION**
31
32

We report the case of a 37 year old male patient, with history of HIV under treatment, was admitted in our emergency department with acute abdominal pain, vomiting and an occlusive syndrome.

The clinical examination found a patient in good general condition, with no disorder of the hemodynamic state ; TA : 110/60 mmHg Fc: 64 bpm, saturation: 98%,
The abdominal examination found a distended painful abdomen.
And a normal laboratory findings.

A CT scan imaging revealed an obstruction of the small bowel on primitive flange, this diagnosis has been retained because the patient has no surgical history.

The patient has been conditioned with a nasogastric tube during 24 hours with no improvement. So a surgical treatment was planned under general anesthesia in the emergency operating room.

The surgical exploration found an obstruction of the small bowel on a flange between the ileum and a mesenteric adenopathy, the flange has been cut with the scissors and the node has been removed.

The patient recovered well and left the hospital in the fifth day.

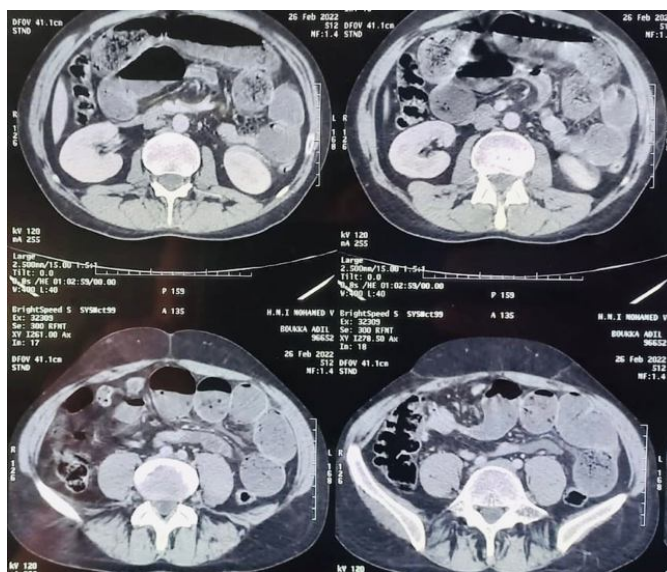
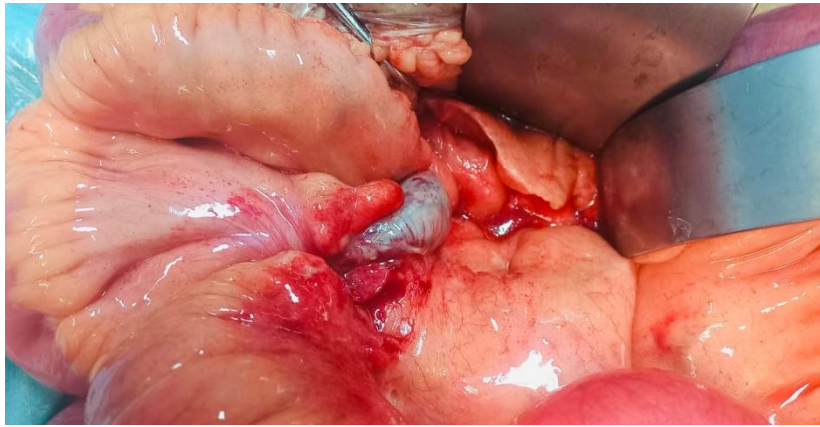
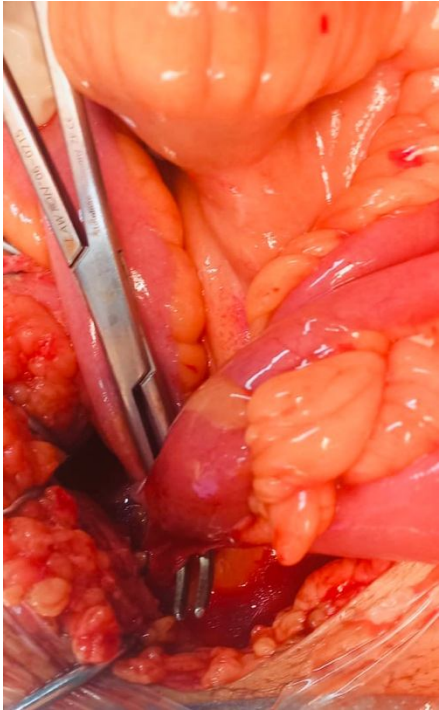


Fig. 1. CT-scan imaging showing an obstruction of the small bowel



55
56 **Fig. 2. Operatory imaging showing a mesenteric adenopathy**



57
58 **Fig. 3. Surgical photo showing the flange between the ileum and a mesenteric adenopathy**

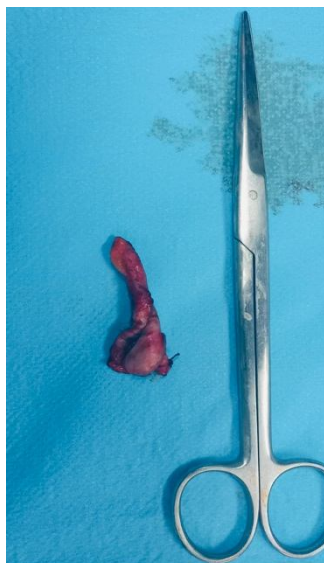

Fig. 4. Mesenteric node after removing

3. DISCUSSION

Tuberculosis remains a global public health issue. According to the World Health Organization (WHO) in 2016, 10.4 million people contracted it with 1.7 million deaths [5]. It is due to *Mycobacterium tuberculosis*. 14% of tuberculosis cases reported worldwide are extrapulmonary [6]. Gastrointestinal involvement accounts for 3 to 5% of all visceral locations. It is revealed by intestinal obstruction in 20-27% of cases [7].

In Morocco, 26,000 to 27,000 new cases of all forms of tuberculosis are detected annually. Extrapulmonary TB accounts for 46% of TB cases and is dominated by lymph node and pleural involvement, which accounts for 70% of extrapulmonary forms [8]. Lymph node tuberculosis is a relatively common form of extrapulmonary disease, and is essentially a therapeutic challenge.

The incidence of TB infection has risen not only in developing countries but also in developed countries. This is partly explained by acquired immunodeficiency virus (HIV) infection, precariousness and immigration [10]. This has led to an increase in the incidence of extrapulmonary localizations, which account for nearly 1/3 of the tuberculosis cases reported in Morocco [9]. Abdominal localization is a relatively common extrapulmonary form, accounting for 5-10% of all localizations [11]. This frequency is higher and could double to triple in HIV-positive subjects.

Digestive involvement may be primary by direct ingestion of mycobacterium or secondary to highly bacilliferous pulmonary lesions by haematogenic or lymphatic route [12]. The bacterial agent is usually the bovine or human *Kokh bacillus*, exceptionally atypical mycobacteria in immunocompromised subjects [12].

TB infection can also be of interest to any other segment of the digestive tract. It is often represented by agglutinated loops, hypertrophic digestive parietal infiltration with peritoneal nodules, and a cluster of deep lymphadenopathy including mesenteric. But this aspect may be lacking, and before an irregular hypertrophic off-centered digestive infiltration, a tumor origin is often evoked [13]. Lymph node localization in intra-abdominal tuberculosis may also be the cause of the pseudo-tumoral appearance.

Ultimately, if the urgency and clinical symptomatology allow them to be performed safely, endoscopic examinations are the most useful [14]. Indeed, the contribution of endoscopy is essential, it allows the detection of lesions, even the most superficial [15, 16]. Its main interest is that it allows the realization of biopsies with

95 histological and bacteriological studies (culture) and then avoids morbidity and mortality related to an exploratory
96 laparotomy [17,18].

97 Knowing how to evoke the diagnosis of tuberculosis is the indispensable condition for rapid and adapted
98 management, because the vital prognosis is at stake [13]. Laparotomy is sometimes the only recourse in case of
99 negativity of the echo or scano-guided puncture [13]. Indeed, 20 to 40% of patients [19] will have a laparotomy,
100 either in emergency before a complication (stenosis, occlusion, compressive mass, flattening of certain casein
101 cavities, perforation and fistula), or for diagnostic purposes.

102 This surgical treatment must be combined with TB treatment. The surgical treatment is not standardized and
103 depends primarily on the reason for the surgical indication. Thus, the removal of one or more obstacles in case of
104 occlusion or a hemostasis process in case of massive bleeding will usually make a resection necessary. It also
105 depends and especially on the lesions observed during the surgical exploration, which most often involve
106 intestinal resections with or without restoration of continuity or internal bypass or stoma[20].

107 108 109 110 **4. CONCLUSION** 111

112 The diagnosis of intestinal tuberculosis is difficult; Knowing how to evoke the diagnosis of tuberculosis is the
113 indispensable condition for a rapid and adapted management, because the vital prognosis is at stake.

114 115 **RIGHT TO PRIVACY AND INFORMED CONSENT**

116 The authors declare that no patient data appear in this article.
117
118
119
120

121 **COMPETING INTERESTS** 122

123 The authors declare that they have no ties of interest in relation to this article
124
125

126 **REFERENCES** 127 128

- 129 1. WHO. Global tuberculosis control: surveillance, planning, financing. WHO report 2007 (WHO/HTM/TB/2007.376).
 - 130 2. Miziara ID. Tuberculosis affecting the oral cavity in Brazilian HIV-infected patients. Oral Surg Oral Med Oral Pathol Oral Radiol Endod 2005; 100: 179-182.
 - 131 3. Jha BC, Dass A, Nagarkar NM, et al. Cervical tuberculous lymphadenopathy: Changing clinical pattern and concepts in management. Postgrad Med J 2001; 77: 185-187.
 - 132 4. Acute Mesenteric Tuberculous Lymphadenitis: A Comparative Analysis of Twenty-one Cases
133 Monitoring Editor: Alexander Muacevic and John R Adler
134 Asif Mehmood,¹ Amna Ehsan,² Maryam Mukhtar,² Faisal Inayat,³ and Waqas Ullah⁴
 - 135 5. WHO . Global tuberculosis report 2017. Accessed November 20 2018.
 - 136 6. WHO . Treatment of tuberculosis: guidelines. 4th ed. Genève: 2010.
 - 137 7. Chaabane NB, Mansour WB, Hellara O, Melki W, Loghmeri H, Bdioui F, et al. La tuberculose gastro-intestinale. Hépatogastro. 2012;19(1):28–35.
- 144
145
146

147

148 8. Royaume du Maroc Ministère de la Santé Direction de l'Epidémiologie et de lutte contre les maladies. Programme
149 national de lutte anti tuberculeuse - Edition Avril 2011.

150

151 9. Denis-Delperre N, Merrien D, Billaud E, et al. Tuberculose extra-pulmonaire dans la région du centre-ouest: Étude
152 rétrospective de 217 cas (GERICCO 199161993) Presse Med. 1998 Feb 28;27(8):341-6.

153

154 10. Ismaïli Z, Amraoui M, Mansouri F, Essamri W, Benazzouz M, Essaïd EA. Tuberculose colique pseudo-tumorale à
155 double localisation. Médecine du Maghreb. 2006;142:5-8.

156

157

158 11. Romand F, Gaudin JL, Bobinchon R, Souquet JC. Tuberculose abdominale d'allure pseudo tumorale. Presse Med.
159 1997 Nov 22;26(36):1717-21.

160

161 12. De Jesus LE, Marques AM, Rocha MS, et al. Left colon stenosis caused by tuberculosis. J Pediatr Surg. 2004;39:e5-
162 e7.

163 13. Romand F, Gaudin JL, Bobinchon R, Souquet JC. Tuberculose abdominale d'allure pseudo tumorale. Presse Med.
164 1997 Nov 22;26(36):1717-21.

165 14. Martinez Tirado P, Loez De Hierro Ruiz M, Martinez Garcia R, Martinez Cara JG, Martin Rodriguez MM, Castilla
166 castellano MM. Intestinal tuberculosis A diagnostic challenge. Gastroenterol Hepatol. 2004;27:43-4.

167 15. Misra SP, Misra V, Dwivedi M, Gupta SC. Colonic tuberculosis: clinical features, endoscopic appearance and
168 management. J Gastroenterol Hepatol. 1999 Jul;14(7):723-9.

169 16. Isaacs P, Zissis M. Colonic tuberculosis and adenocarcinoma: an unusual presentation. Eur J Gastroenterol Hepatol.
170 1997 Sep;9(9):913-5.

171 17. Florent C, Rambaud JC. Traité de gastro-entérologie. Tuberculose digestive. 2000:983-7

172

173 18. Kacem C, Kamoun A, Bahout M, Zermani R, Najjar T. Colonic tuberculosis: an exceptional cause of a massive
174 surgical hemorrhage a propos of a case and review of the literature. Tunis Med. 1999;77(10):530-3.

175

176 19. Badre W, et Coll Tuberculose digestive pseudo-tumorale. Magh Med. 2002;22(363):208-11.

177

178

179 20. Nguyen Duc C, Pha Hai B, Pham Van T, Ton That B, Huguier M. Tuberculoses compliquées du tube digestif. Annales
180 de chirurgie. 2006;131:306-10.