

Fournier's Gangrene: A Report of Two Cases and Literature Review

Abstract

Fournier's gangrene is a very serious surgical emergency seen all over the world. With the newer advancement of surgical techniques and critical care medicine, the mortality and morbidity of this disease has come down significantly over a period of time. An early diagnosis including evaluation of predisposing and etiological factors, metabolic and physiological parameters with prompt resuscitation, aggressive surgical debridement, broad-spectrum antibiotic coverage, and continuous monitoring of all the parameters is essential for a good outcome, therefore reducing the high mortality and morbidity of this condition. In this study, we reported two different cases of Fournier's gangrene. Our first case was a young, non-diabetic, and without any multi-organ failure, who was managed successfully with good outcome. The second case was a 67-year-old man with diabetes and multi-organ dysfunction with extensive gangrene at presentation, who recovered well, but with a stormy postoperative period.

Keywords: Fasciitis, Necrotizing, Fournier's Gangrene, Sepsis, Debridement, Diabetes melitus.

Introduction

Fournier's gangrene is a potentially fatal specific form of necrotizing fasciitis, localized on the external genital organs and the perianal region, that can afflict people of any age or gender and causing small vessel thrombosis, obliterate endarteritis, and ultimately skin and tissue necrosis, with manifestations of severe intoxication and multiple organ failure [1,2]. The clinical features of Fournier's gangrene include severe pain, soreness, and necrosis of the tissues in the affected locations, which are primarily in the genital area. Brodie's sign, a black area that signals inflammation, first appears [3]. From this point on, the patient's overall state rapidly deteriorates as the necrotic inflammation rapidly spreads along the fascia planes and extends into the surrounding regions (perineum, scrotum, hypogastrium, and occasionally the area from the thigh up to the diaphragm) [4]. It is commoner in males with a male to female ratio of 10 to 1 [5]. It is a severe urological and surgical emergency with fatality rates that range from 15% to 50% [6]. Diabetes mellitus, alcoholism, cancers, immunosuppression, liver and renal disease are predisposing factors thought to play a role in the development of the disease [7]. Aerobic and anaerobic bacteria are synergistically involved as a result of anorectal and urogenital trauma and/or infection most of the time. For a successful outcome and to lessen the high mortality and morbidity of this condition, an early diagnosis that includes evaluation of predisposing and etiological factors, metabolic and physiological parameters, prompt resuscitation, aggressive surgical debridement, broad-spectrum antibiotic coverage, and continuous monitoring of all the parameters is essential.

We present two cases of Fournier's gangrene following a perianal abscess and diabetes mellitus which were successfully treated in Bethesda Family Hospital despite the severity of the patients' conditions.

Presentation of Case

Case 1

A 47-year-old rural male fisherman was admitted to the hospital with severe perianal and scrotal pain, and fever of five days duration. It started as a boil at the perianal area about two weeks before presentation and gradually extended to his scrotum. He was not a known diabetic but took a lot of alcohol. On physical examination, he was ill- looking, not pale, anicteric and febrile (Temperature 39⁰ C). His pulse rate was 120 b/min and blood pressure 90/55 mmHg. Examination of the perianal area and the genital region showed a necrotizing soft-tissue infection of the perianal area and scrotum with foul smelling discharge. Crepitations were felt on palpating the area. A diagnosis of Fournier's gangrene complicating a perianal abscess was made.

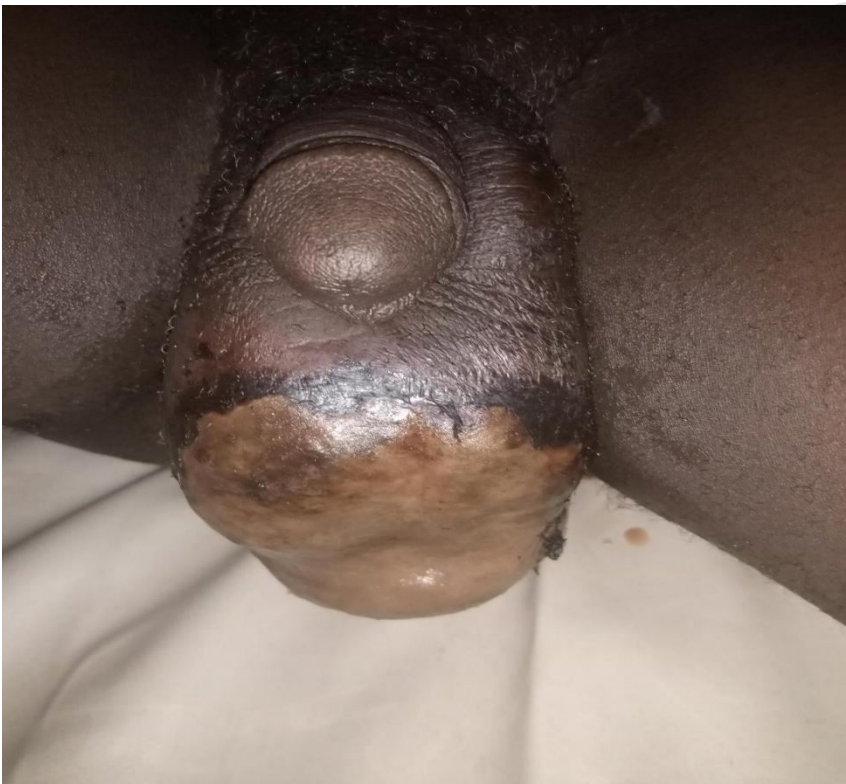

Fig. 1 Fournier's gangrene on presentation

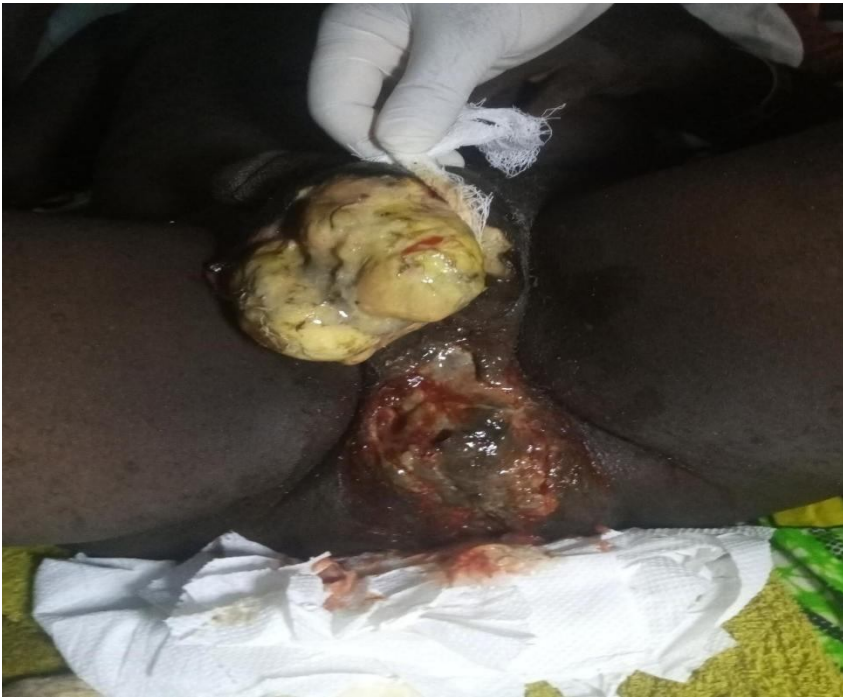

Fig. 2 Fournier's gangrene after the first debridement

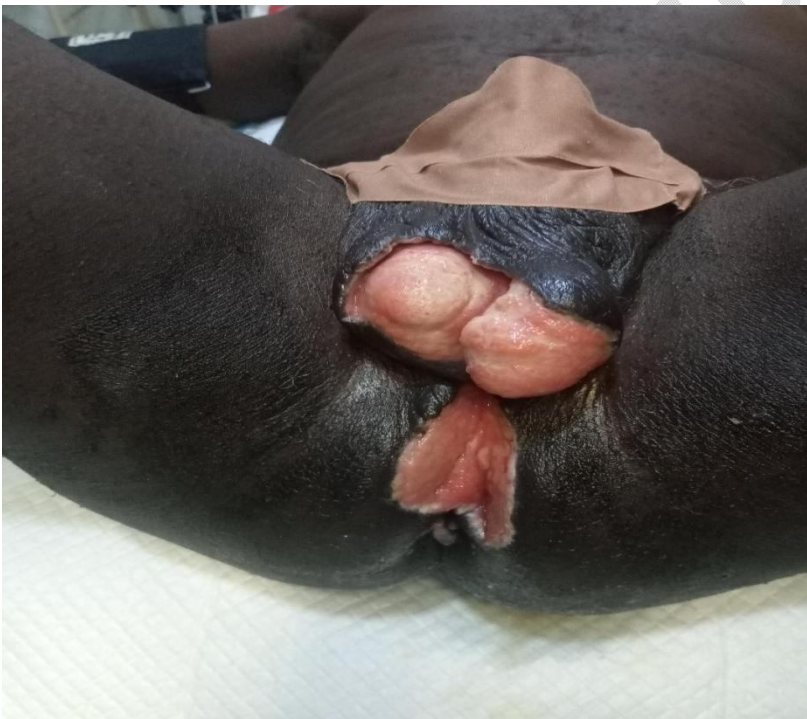

Fig. 3 Fournier's gangrene with adequate granulation tissue awaiting reconstruction

He was admitted and commenced on aggressive fluid administration, analgesic and antipyretic, and haemodynamic support. A urethral catheter was passed to monitor fluid input and output. Blood sample was taken for full blood count, fasting blood glucose

and serology. The white blood cell count was $23.0 \times 10^9/L$ with neutrophilia (89.0%), fasting blood glucose was 5.6 mmol/L. With improvement in his haemodynamic status, he was taken to the theatre for surgical debridement under general anesthesia. Preoperative antibiotic treatment with ceftriaxone and metronidazole was initiated. Wound swab was taken for microscopy, culture and sensitivity. The necrotic skin in the scrotum and the perianal region was evacuated into a wide-open drainage area, without any damage to the testicles, spermatic cords, or external sphincter. The wound swab yielded *Staphylococcus aureus* and *Escherichia coli* which were sensitive to ceftriaxone and ceftazidime. Debridement was done three times with moist gauze dressing twice daily until healthy granulation tissue was observed. Subsequently, dry dressings were used. The infection gradually subsided, the gas gangrene resolved completely and good granulation tissue started appearing six weeks after the surgery. The different stages of the lesion are shown in figures 1, 2 and 3. Reconstruction with secondary suturing of the wound was done on the 37th postoperative day and the sutures removed on the 42nd postoperative day. The wound was completely healed and he was discharged on the 45th day.

Case 2.

A 67-year-old male farmer, a known diabetic on irregular treatment, living in a very remote part of Rivers state, Nigeria reported to the hospital with complaints of swelling, pain, and foul smelling discharge from the scrotum of 5 days duration. On examination, he was confused, acutely ill-looking, pale, anicteric, febrile (Temp. 38.5°C) and moderately dehydrated. His pulse rate was 118 b/min, blood pressure was 130/80 mm Hg and respiratory rate 27 cycle/min. Systemic examination revealed no clinical abnormality but for his scrotum which showed gross edema with multiple discharging gangrenous patches, tender, with palpable crepitations all over. He was commenced on analgesic and antipyretic, intravenous fluid (Ringers lactate), intravenous ceftriazone along with metronidazole, and blood samples taken for investigations. A Foley's catheter was passed and retained, and 150 mL of concentrated urine was drained. Blood haemogram revealed PCV 27%, white cell count: $22.0 \times 10^9/L$ with neutrophilia (N-89%). Biochemical parameters were deranged (blood urea: 14.0 mmol/L, serum creatinine: 112.0 $\mu\text{mol/L}$, random blood sugar: 25 mmol/L, serum billirubin: 25.8 $\mu\text{mol/L}$, AST: 65 IU/L, ALT: 60 IU/L). But the prothrombin time and serum electrolytes were within normal range. He was commenced on insulin injections for his high blood glucose and scheduled for emergency surgical debridement.

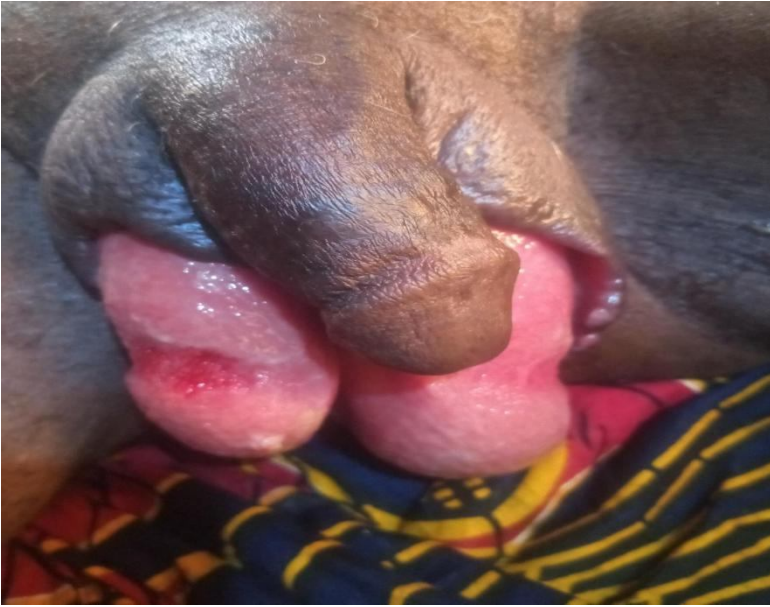

Fig 4: Clean wound with adequate granulation tissue

Wound swab was taken for microscopy, culture and sensitivity. Culture report showed *E. coli* and *Staph. aureus* sensitive to ceftriazone and ciprofloxacin hence the same antibiotic regimen was continued. His urine output became normal by the 2nd post-operative day. By the 5th post-operative day, his blood urea and serum creatinine came within normal range. The blood glucose level was well controlled with insulin therapy. Regular wet dressing was done along with topical application of povidone iodine and the wound was debrided two more times until healthy tissue became visible on the 57th post operative day.

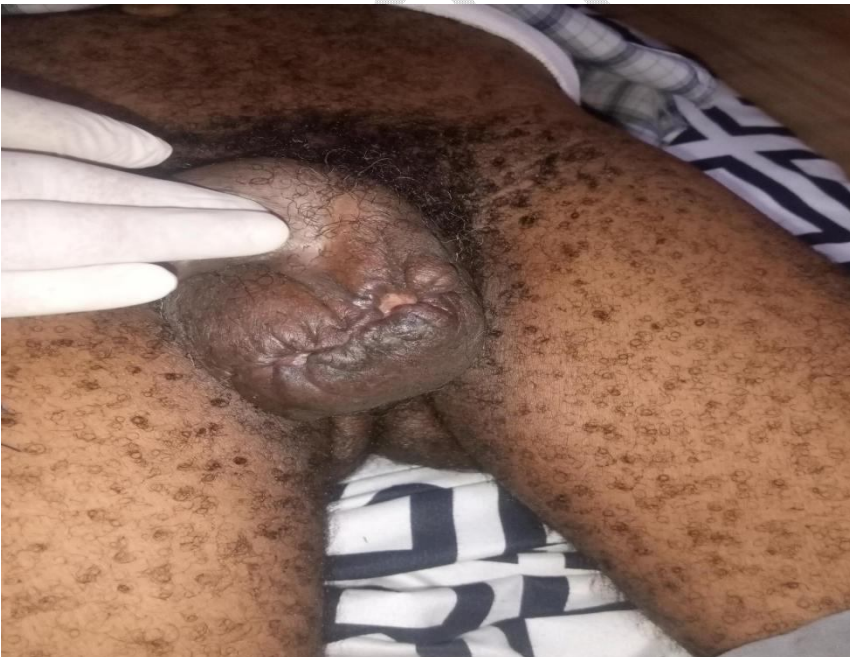


Fig. 5 Scrotum after reconstruction

The wound became clean with adequate granulation tissue hence was reconstructed by secondary suturing on the 65th post operative day. It healed uneventfully and he was discharged from the hospital on the 74th post operative day.

Discussion

Fournier's gangrene begins with symptoms such as fever and scrotal swelling and severe pain. Crepitus, purulent discharge, and necrosis become distinct diagnostic features of necrotizing fasciitis as the infection spreads [8]. It is a potentially fatal specific form of necrotizing fasciitis, localized on the external genital organs and the perianal region, that can afflict people of any age or gender and causing small vessel thrombosis, obliterate endarteritis, and ultimately skin and tissue necrosis, with manifestations of severe intoxication and multiple organ failure [1,2]. The infection commonly arise from the gastrointestinal tract, genitourinary tract and cutaneous injuries and soft tissue [9]. Czymek et al in a study on females reported a high incidence of 31.6% emanating from vulvar and Bartholin gland abscesses as well as in postoperative period following episiotomy and hysterectomy [7]. Among the males, the commonest source of infection is minor injuries or soft tissue infection of scrotal skin [10]. However, the portal of entry is difficult to establish more often.

The predisposing factors include diabetes mellitus, alcoholism, old age, debilitating illness, chronic cortecosteroid use, chemotherapy, obesity, paraplegia, cancers, immunosuppression, liver, and renal disease.[7] Multiple predisposing factors predict a poor prognosis and correlate significantly with mortality [11]. When sepsis is present at the time of hospital admission, the reported overall mortality rate might be as high as 70-80% [12]. Interestingly, there may be no definitive predisposing factors [10]. Wound cultures commonly show poly microbial infections by aerobes and anaerobes, which include coliforms, klebsiella, streptococci, staphylococci, clostridia, bacteroids, and corynbacteria, of which at least three organisms on the average are found from each diagnosed patient when good laboratory services are available [13]. The majority of these organisms are common commensals found in the perineum and genitalia that become virulent and work in concert to infiltrate tissue and inflict severe harm since the host's cellular immunity is compromised [14]. *Escherichia coli* has been reported to be the commonest organism isolated from the wound, probably because of the commensal nature of these organisms in the perianal region. Anaerobes are not isolated in our hospital because of technical difficulties. The infection proceed unchecked rapidly along the facial planes due to the impaired defence mechanisms in the host. The Aerobes and anaerobes working in synergy produce a variety of exotoxins and enzymes that aid in tissue distruction and the spread of infection, such as collagenase, heparinase, hyaluronidase, streptokinase, and streptodornase. The aerobes induce platelet aggregation and complement fixation and the anaerobes produce heparinase and collagenase which lead to microvascular thrombosis and dermal necrosis. Further spread of infection is aided by the impaired phagocytic activity in the necrotic tissue [9].

The diagnosis of Fournier's gangrene is clinical. However, in difficult situations, where doubtful diagnosis exists, radiological evaluation is imperative. These include plain radiography, ultrasonography and CT scan. Of all these, ultrasonography is a

commonly available investigation modality which is very useful in detecting gas in the scrotal wall and the extent of the disease process [15]. The importance of laboratory studies such as full blood count lies in the fact that white blood count presents a prognostic indicator at the time of presentation. Certain parameters, like low hematocrit, low-serum albumin, high blood urea nitrogen and serum creatinine, and high alkaline phosphatase are predictors of mortality. Other electrolyte abnormalities linked with mortality include hypercalcemia and raised serum lactate level at the time of presentation [16].

Treatment of Fournier's gangrene is quite intensive to minimize morbidity and mortality. Initial resuscitation with fluid and electrolyte, and restoration of cardiopulmonary function to normal in patients presenting with septic shock is very important at the time of presentation. Aggressive surgical debridement of all devitalized tissues and proper drainage is important to stop the progress of the infection and simultaneous elimination of systemic effects of toxins and bacteria [7]. This is done with administration of broad spectrum antibiotics which may be modified after obtaining the culture and sensitivity report. Administration of analgesics, antipyretics and close monitoring for early signs of renal failure, as well as detection and early treatment of other possible complications is very essential. Multiple surgical debridement may be required to achieve adequate local control of infection. Initial twice daily wet dressings and topical application of povidone iodine may suffice to be followed with daily dry dressing. With adequate surgical debridement, local wound care, and antibiotic therapy, healthy granulation tissue will appear, and primary wound closure can be done. With multiple debridements, there may be resultant significant skin and soft tissue loss in genitalia and perineum causing a large defect which can lead to high morbidity. This can be salvaged by reconstructive surgery with adequate tissue coverage [4,17].

Conclusion

Fournier's gangrene is a surgical emergency with a high mortality rate. However, with improved diagnostic modalities, surgical technique, potent antibiotics, and critical care, the morbidity and mortality has reduced tremendously. The two cases reported in this case report were from rural areas with delayed presentation to the hospital. Though both cases have different associated factors, yet their recovery were satisfactory without any significant postoperative morbidity with case 2 having protracted hospital stay.

In our experience, rural dwellers report late to the hospital and are prone to complications. Fournier's gangrene with diabetes mellitus always poses a greater challenge in reducing morbidity and mortality. The successful management of the two patients followed a similar protocol. It is recommended that each institution adopts a reliable protocol in the management of Fournier's gangrene to achieve a low morbidity and mortality, especially in presence of the comorbidity like diabetes mellitus.

Ethical considerations

Permission was obtained from the patients and the Bethesda Family Hospital authority before these case reports were published.

References

1. Yanar H, Taviloglu K., Ertekin C., Guloglu R, Zorba U, Cabioglu N. et al., "Fournier's gangrene: risk factors and strategies for management," *World Journal of Surgery*, 2006;30(9): 1750–1754.
2. Chernyadyev SA, Ufimtseva MA, Vishnevskaya IF, Bochkarev YM, Ushakov AA, Beresneva TA, Galimzyanov FV, Khodakov VV. Fournier's Gangrene: Literature Review and Clinical Cases. *Urol Int*. 2018;101(1):91-97.
3. Fajdic J, Bukovic D, Hrgovic Z et al: Management of Fournier's gangrene. Report of 7 cases and review of the literature. *Eur J Med Res*, 2007; 12: 169–72
4. Chennamsetty A, Khourdaji I, Burks F, Killinger KA: Contemporary diagnosis and management of Fournier's gangrene. *Ther Adv Urol*, 2015; 7(4): 203–15.
5. KUZAKA B, Wróblewska MM, Borkowski T, Kawecki D, Kuzaka P, Młynarczyk G, Radziszewski P. Fournier's Gangrene: Clinical Presentation of 13 Cases. *Med Sci Monit*. 2018;24:548-555.
6. Papaconstantinou I, Yiallourou AI, Dafnios N, Grapsa I, Polymeneas G, Voros D. Successful Treatment of a Severe Case of Fournier's Gangrene Complicating a Perianal Abscess. *Case Rep Med*. 2011;2011:702429. doi: 10.1155/2011/702429.
7. Czymek R, Hildebrand P, Kleemann M, Roblick U, Hoffmann M, Jungbluth T, Bürk C, Bruch HP, Kujath P. New insights into the epidemiology and etiology of Fournier's gangrene: a review of 33 patients. *Infection*. 2009;37(4):306-12.
8. Lewis GD, Majeed M, Olang CA, Patel A, Gorantla VR, Davis N, Gluschitz S. Fournier's Gangrene Diagnosis and Treatment: A Systematic Review. *Cureus*. 2021;13(10):e18948. doi: 10.7759/cureus.18948.
9. Thwaini A, Khan A, Malik A, Cherian J, Barua J, Shergill I, Mammen K. Fournier's gangrene and its emergency management. *Postgrad Med J*. 2006;82(970):516-9.
10. Hota PK. Fournier's Gangrene: Report of 2 Cases. *Case Rep Emerg Med*. 2012;2012:984195. doi: 10.1155/2012/984195.
11. D'Arena G, Pietrantuono G, Buccino E, Pacifico G, Musto P. Fournier's Gangrene Complicating Hematologic Malignancies: a Case Report and Review of Literature. *Mediterr J Hematol Infect Dis*. 2013;5(1):e2013067. doi: 10.4084/MJHID.2013.067.
12. García Marín A, Turégano Fuentes F, Cuadrado Ayuso M, Andueza Lillo JA, Cano Ballesteros JC, Pérez López M. Predictive factors for mortality in Fournier' gangrene: a series of 59 cases. *Cir Esp*. 2015;93(1):12-7.
13. Yaghan RJ, Al-Jaberi TM, Bani-Hani I. Fournier's gangrene: changing face of the disease. *Dis Colon Rectum*. 2000;43(9):1300-8.

14. Murray JL, Connell JL, Stacy A, Turner KH, Whiteley M. Mechanisms of synergy in polymicrobial infections. *J Microbiol.* 2014;52(3):188-99.
15. Ballard DH, Mazaheri P, Raptis CA, Lubner MG, Menias CO, Pickhardt PJ, Mellnick VM. Fournier Gangrene in Men and Women: Appearance on CT, Ultrasound, and MRI and What the Surgeon Wants to Know. *Can Assoc Radiol J.* 2020;71(1):30-39.
16. Corcoran A. T, Smaldone M. C, Gibbons E. P, Walsh T. J, Davies B. J. "Validation of the fournier's gangrene severity index in a large contemporary series," *Journal of Urology*, 2008; 180(3): 944–948.
17. Black PC, Friedrich JB, Engrav LH, Wessells H. Meshed unexpanded split-thickness skin grafting for reconstruction of penile skin loss. *J Urol.* 2004 Sep;172(3):976-9.

UNDER PEER REVIEW