

Endovascular Management of Anterior Communicating Artery Aneurysms

ABSTRACT

Background: Intracranial aneurysms are potentially life threatening or disabling vascular lesions. The majority of aneurysms are located at branching points along the proximal arterial tree, suggesting that haemodynamic factors play significant role in aneurysms formation, **Aim:** The aim of the work was to evaluate the efficacy, safety, clinical and radiological outcome of endovascular management of anterior communicating artery aneurysms. **Patients and Methods:** This study was a prospective study conducted on 20 patients with anterior communicating artery aneurysms at Neurosurgery Departments – Tanta University hospitals between February 2021 and April 2022. **Results:** Successful EVT was achieved in 19 patients. 17 patients had good recovery (GOS 5), 1 patient had moderate disability (GOS 4), no patients severely disabled (GOS 3), and 1 patient died (GOS 1). According to Hunt and Hess grading (5 patients before EVT), 10 patients with grade 1, 5 patients with grade 2 and 5 patients with grade 3 and all patients were with the same grading after EVT without deterioration. **Conclusion:** In this thesis, EVT was an effective and safe technique for treatment without any treatment related morbidity or mortality. Despite our good angiographic and clinical outcome either postoperatively or during early follow up period, still longer angiographic and clinical follow up is mandatory in all cases since initial total obliteration is not a guarantee for permanent obliteration.

Key Words: Endovascular; Anterior Communicating Artery; Aneurysms; Intracranial; vascular lesions.

Introduction

Intracranial aneurysms are potentially life threatening or disabling vascular lesions. The majority of aneurysms are located at branching points along the proximal arterial tree, suggesting that haemodynamic factors play significant role in aneurysms formation (1).

Aneurysms of anterior circulation represent 85% and those of posterior circulation represent 15% of intracranial aneurysms. The most common location of anterior circulation aneurysms is the anterior communicating artery (35%) followed by Posterior communicating (Pcom) artery (25%) and then middle cerebral artery aneurysms (20%) (2).

Outcome studies of aneurysmal SAH show that 10-15% of patients die before reaching medical care, 30-day mortality rate was 46% in one series, and in others over half the patients died within 2 weeks of their SAH (3).

The history of endovascular intervention started by two neurosurgeons, Luessenhop and Velasquez in Georgetown University Hospital in Washington who did the first catheterization of cerebral vessels in 1964. In 1971, Dr. Fedor A. Serbinenko (N.N.Burdenko Neurosurgery Institute – Moscow), described a series of 300 patients treated using detachable and non-detachable balloons. In 1991, Italian Dr. Guido Guglielmi, described the practical use of detachable coils (4).

Since the introduction of coil embolization for intracranial aneurysms, endovascular treatment has become a valid and increasingly utilized alternative to surgical clipping. However, recurrence after coiling is not infrequent (5).

The aim of the work was to evaluate the efficacy, safety, clinical and radiological outcome of endovascular management of anterior communicating artery aneurysms.

Patients and Methods

This study was a prospective study conducted on 20 patients with anterior communicating artery aneurysms at Neurosurgery Departments – Tanta University hospitals between February 2021 and April 2022.

Inclusion criteria: All patients with anterior communicating artery aneurysms.

Exclusion criteria: Patients with impaired renal and hepatic functions
Pregnancy and Patients with coagulation disorders

Patient Evaluation and Management

Our initial step in the evaluation of a patient with suspected SAH focuses on brief history, airway evaluation. This is followed by evaluation of vital signs and initial resuscitation. Initial clinical grading was performed according to Hunt and Hess scale. Early non contrast CT imaging is done and bleeding on the CT scan was quantified by using the Fisher scale. In case the CT shows SAH, the patients do CTA immediately in the same study.

Our patients are given initial medical treatment, and this is in the form of:

Fluids which is given by continuous infusion of normal saline at a rate 100ml/hr. starting from the first day which is guided by cardiac function. Antiepileptic medications, levetiracetam. Antacid medications. Nimodipine, oral 2 tab "60mg "\4hrs or IV 1-2 ml\hr. Analgesics, Paracetamol 1000mg\8hrs or Tramadol 100mg amp\12hr. Other medications are given according to each case.

Patient must be kept in hypertensive side to guard against vasospasm.

All patients after initial medical management and resuscitation are subjected to history taking and clinical examination (general and neurological). Also, routine laboratory investigations are done with special concern to coagulation profile, hepatic and renal functions. Serial assessment of neurological function is done, and preparation for angiography.

In all our cases we do CTA immediately at the same study if the CT shows SAH. Conventional catheter angiography remains the gold standard for detection of intracranial aneurysms and it is performed either as part of therapeutic angiography or in case CTA is not conclusive, in cases with negative CT and high suspicious for intracranial aneurysm, lumbar puncture and CSF xanthochrome level must be considered in diagnosis.

Angiographic Outcome: Angiographic outcome at final control angiogram was evaluated according Raymond classification (6).

Class 1 (complete obliteration): total opacification of the aneurysmal sac and neck without any defect at parent arterial wall.

Class 2 (subtotal obliteration or neck remnant): persistence of any portion of the original defect of the arterial wall as seen on any projection but without opacification of the aneurysmal sac.

Class 3 (incomplete obliteration): any opacification of aneurysmal sac.

Clinical Outcome: Clinical evaluation at hospital discharge was performed with Glasgow Outcome Scale (GOS).

Grade 5: good recovery without neurologic deficits.

Grade 4: moderate disability - patient is independent but disabled.

Grade 3: severe disability - patient is dependent.

Grade 2: vegetative state.

Grade 1: death.

Angiographic Follow up: Immediate post CT brain obtained postoperative in all patients, MRA at 3 to 6 months to ensure stable occlusion, Follow up DSA obtained in selected cases of ruptured aneurysms as post interventional diagnostic and therapeutic tools in cases presented with vasospasm.

Clinical Follow up: Clinical follow up for patients was decided according each patient status. Patients are followed on weekly basis for the first month and then monthly for the next 3 months and then every two months in first year.

Results

From february 2021 to april 2022, 20 cases presented with SAH and admitted to Tanta University Hospitals. We had 20patients, (22 aneurysms), 8 male, and 12 females. Age range from 26 to 60 years old, with the mean age in our study group was 44.43 years old.

Risk factors include cigarette smoking in 5 patients, hypertension in 5 patients, DM in 3 patients, and there wasn't any patient with evident family history of SAH.

Table (1) Patient characteristics in the study group

Characteristics of patient population	Number of patients	Percentage
Age		
Range	26 -60	
Mean	44.43	
Sex		
Male	8	40 %
Female	12	60%
Risk factor		
DM	3	15%
HTN	5	25 %
Smoker	5	25%

Endovascular coiling was done successfully in 19 cases, it was aborted in one cases. it was due to spontaneous thrombosis of aneurysm .

Table (2): number of successful cases vs failed cases

	Number of cases	Percentage
Total	20	100%
Successful	19	95%
Failed	1	5%

17 patients in our series had single aneurysm, two cases hade multiple aneurysms and one patient had AcomA aneurysm associated with AVM. Endovascular treatment (EVT) was planned for all patients. For the patient with multiple aneurysms, a conventional angiography was done. In the case of the AcomA which associated with AVM the patient was presented by SAH from the rupture of the aneurysm, so coiling was done to secure **the** aneurysm and to prevent the rebleeding.then the patient was referred for Gamma knife unit as AVM was on elequant brain and had no endovascular management.

Table (3): Association of the aneurysm

Character	Number of cases	Percentage
Single aneurysm	17	85%
Associated with AVM	1	5%

Multiple aneurysms	2	10%
---------------------------	---	-----

Regarding size of the aneurysms, 2 aneurysms were baby (less than or equal 2mm) 12 aneurysms were small (3-10 mm), 6 aneurysms were large (11-24 mm), and no giant aneurysms (more than or equal 25 mm).

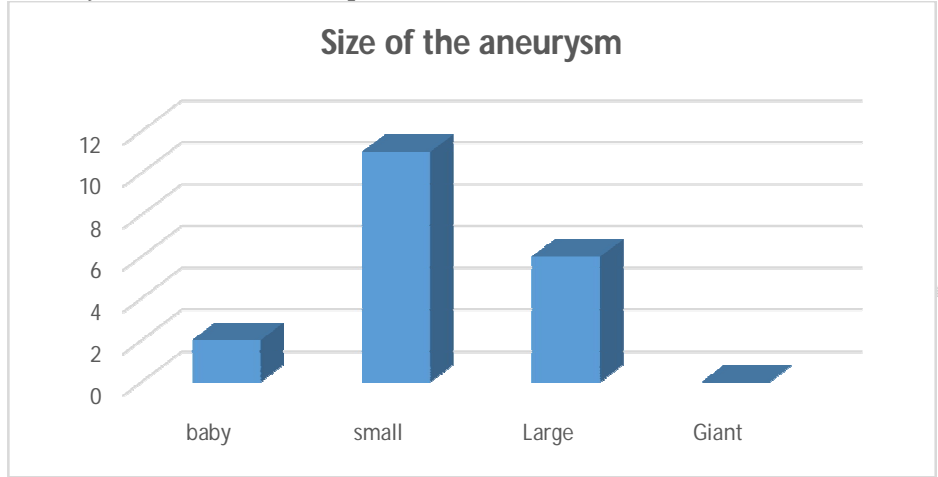


Chart (1) Size of the aneurysm

Successful EVT was achieved in 19 patients. 17 patients had good recovery (GOS 5), 1 patient had moderate disability (GOS 4), no patients severely disabled (GOS 3), and 1 patient died (GOS 1). According to hunt and hess grading (patients before EVT), 10 patients with grade 1 , 5 patients with grade 2 and 5 patients with grade 3 and all patients were with the same grading after ETV without deterioration .

Table (4): Clinical outcome

Clinical outcome	Number of patients	Percentage
Class 5	17	85%
Class 4	1	5%
Class 1	1	5%

In our study 14 aneurysms out of 19 coiled aneurysms were Class 1, and 4 aneurysms out of 19 aneurysms were class 2, and 1 aneurysm out of 19 aneurysms was class 3.

Table (5): Angiographic outcome

Angiographic outcome	Number of aneurysms	Percentage
Class 1	14	70%
Class 2	4	20%
Class 3	1	5%

In our series there no operation related morbidity or mortality we had 4 complicated cases, two cases of vasospasm, and one case of groin hematoma and one case of dissection of femoral artery .

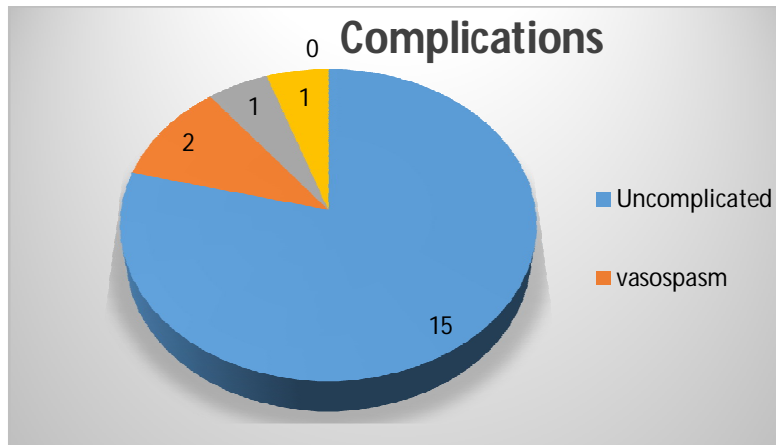
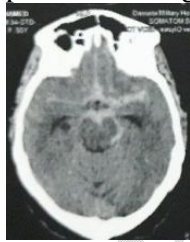

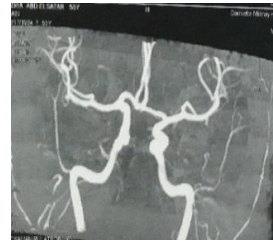Chart (2) Complications of EVT

Case (1)

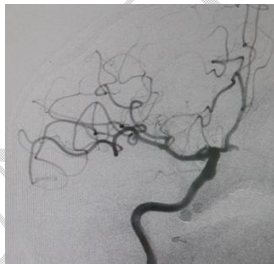Female patient, 58 years old, Diabetic and hypertensive. Presented by acute severe headache, recurrent vomiting, and neck rigidity. Hunt and Hess grade 1, CT brain showed SAH (fisher grade 3). MRA was unremarkable. DSA showed small AcomA aneurysm, and RT MCA micro aneurysm. Coiling of AcomA aneurysm was done using single micro coil. It was decided to follow up MCA aneurysm, specially it was not the source of SAH. Bilateral femoral punctures were used, and bilateral catheter injecting dye from both sides were used to visualize both A2 segments before and after coiling, patient discharged with (GOS grade 5)



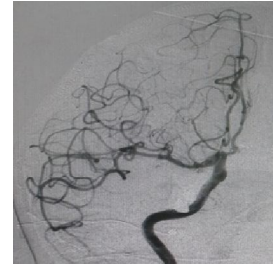CT brain



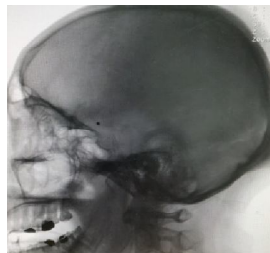
MRA brain



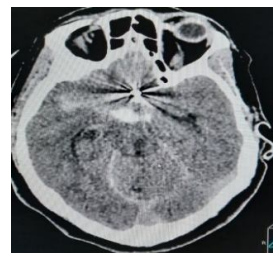ICA angiogram, pre-coiling



ICA angiogram, post-coiling



Fluoroscopic images, lateral view, showing coil mass



CT brain, post coiling

Figure 1: CT scan and MRI images

Discussion

Results of the ISAT have shown that there is a 7.4% (95% confidence interval) absolute reduction in the risk of death or dependency at 1 year and a 24% (95% confidence interval) relative risk reduction on modified Rankin scale in endovascular group when compared to surgical group. Thus, short-term safety and efficacy of the technique have been proven to a grade I evidence level (7).

In our study according to Sex 8 male (40%), 12 females (60%). age range (26-60) years, and the mean (44.43) years.

Compared to other studies, VANZIN (in his series 2012) reported that 68.3% of patients were women, and 31.7% of patients were men. Also VANZIN reported that age range was (16-90) years and the mean was (48) years (8).

Raymond (in his series 2003) reported The mean age was 54.2 years, and 74% of patients were females, and 26% were males (6).

In our study 5 patients were smoker (25%), 5 patients were hypertensive (25%), and 3 patients were Diabetic (15%).

Elewa (in his series 2018) reported that Smoking (38.7%), Hypertension (41.9%), Diabetes mellitus type II (12.9%) (9).

In our study 17 (85%) patients has single aneurysm with 2 multiple aneurysms (10%) and one case with AVM (5%).

Raymond (in his series 2003) reported that Patients had multiple aneurysms in 35.6% of cases (6).

VANZIN (in his series 2012) reported that Patients had multiple aneurysms in 29.4% of cases (8).

In our study 2 (10%) aneurysms were baby size (less than or equal 2 mm), 12 (60%) aneurysms were small (3-10 mm), 6 (30%) aneurysms were large (11-24 mm), and 0 (0%) aneurysms were giant (≥ 25 mm).

Raymond (in his series 2003) reported that (21.3%) aneurysms were small (3-9mm), (50.6%) aneurysms were ≥ 10 mm (6).

In our study 15 (75%) aneurysms had narrow neck (≤ 4 mm), 5(25%) aneurysms had wide neck (≥ 4 mm).

Raymond (in his series 2003) reported that (23.7%) of aneurysms had narrow neck (≤ 4 mm), while (52.2%) of aneurysms had wide neck (≥ 4 mm) (6).

In our study total obliteration was achieved in 14 (70%) aneurysms, Subtotal obliteration was achieved in 4 (20%) aneurysms and incomplete obliteration was achieved in 1 (5%) aneurysms.

Gonzalez reported complete obliteration in 55.9%, neck remnants in 32.2% and incomplete obliteration in 1.2% (10). Cognard reported complete obliteration in 57% neck remnants in 37% and incomplete obliteration in 6% (10).

Renowden reported complete obliteration in 62%, neck remnants in 33% and incomplete obliteration in 5% (11).

Hasan et al reported complete obliteration in 63.4%, neck remnant in 30.8% and aneurysmal filling in 5.8% (12).

Cognard reported re bleeding in 0.8% of patients in aneurysms with incomplete obliteration during early follow up period for ruptured aneurysms in his series (13).

Renowden reported re bleeding in 2.4% with most of them occurred during first month after treatment (11).

Outcome after re hemorrhage was poor, with a 62.5% mortality rate, concurrent with another series reporting high mortality rates after early re rupture (14).

Different results were shown by investigators in the Cerebral Aneurysm re rupture After Treatment study on predictors of re hemorrhage after treatment of ruptured intracranial aneurysms, who found the degree of aneurysm occlusion to be highly predictive of the risk for re rupture, which increased progressively as the packing attenuation decreased (15).

Angiographic follow up was achieved in 10 out of 20 (50%) treated case. 7 cases had an MRA follow up imaging and 3 cases had conventional angiography. The average period of follow up was ranging from 6 to 10 months. In our series all cases underwent imaging follow up were stable with no re canalization detected.

Several clinical, technical, and anatomical factors are implicated in the recanalization rate observed after cerebral aneurysm coiling. The aneurysm diameter (>10 mm) and neck width (>4 mm) are the main factors determining the final degree of occlusion achieved (16).

Grunwald et al. demonstrated that only 12.7% of completely occluded aneurysms re canalized compared with 40% of those with initial 80% to 95% occlusion (17), and Raymond et al. demonstrated recanalization rates of 20.0% in completely occluded aneurysms vs 40.1% recanalization of aneurysms with neck remnants and 51.1% recanalization of aneurysms with body remnants (11).

VANZIN reported that Recurrences were found in a total of 122 among the 445 cases (26.8%) of treated aneurysms with a mean of 21 ± 15.7 months of follow-up. Most cases of recurrence occurred in the first 6 months of follow-up (8).

Conclusion

In this thesis, EVT was an effective and safe technique for treatment without any treatment related morbidity or mortality. Despite our good angiographic and clinical outcome either postoperatively or during early follow up period, still longer angiographic and clinical follow up is mandatory in all cases since initial total obliteration is not a guarantee for permanent obliteration.

References

1. Rhoney DH, McAllen K, Liu-DeRyke X. (2010). Current and future treatment considerations in the management of aneurysmal subarachnoid hemorrhage. *J Pharm Pract.*; 23(5): 408-424.
2. Wadd IH, Haroon A, Habibullah, Ansari S, Mukhtar S, Umair R, et al. (2015). Aneurysmal subarachnoid hemorrhage: outcome of aneurysm clipping versus coiling in anterior circulation aneurysm. *Jcsp.*; 25(11): 798-801.
3. Greenberg, M. (2020). *Handbook Of Neurosurgery.* , Thieme Medical Publishers, Inc, New York, NY: 1244-1248.
4. Fotakopoulos, G., Tsianaka, E., Fountas, K., Makris, D., Spyrou, M., Hernesniemi, J. (2017). Clipping Versus Coiling in Anterior Circulation Ruptured Intracranial Aneurysms: A Meta-Analysis. *World Neurosurgery*, 104, 482-488.
5. Petr O., Waleed Brinjikji & Claudius Thomé. (2015). Safety and efficacy of microsurgical treatment of previously coiled aneurysms: a systematic review and meta-analysis. *Acta Neurochir*, 157:1623–1632.
6. Raymond J, Guilbert F, Weill A, Georganos SA, Juravsky L, Lambert A. (2003). Long-term angiographic recurrences after selective endovascular treatment of aneurysms with detachable coils. *Stroke*. 34(6): 1398-1403.

7. Molyneux, A. J. (2015). The durability of endovascular coiling versus neurosurgical clipping of ruptured cerebral aneurysms: 18 year follow-up of the UK cohort of the International Subarachnoid Aneurysm Trial (ISAT). *385(9969)*: 691-697.
8. Vanzin, J.R., Mounayer, C., Abud, D.G., Annes, R.D.A. and Moret. (2012). Angiographic results in intracranial aneurysms treated with inert platinum coils. *Interventional Neuroradiology*, 18(4), pp.391-400.
9. Elewa, M.K., (2018). Endovascular coiling for cerebral aneurysm: single-center experience in Egypt. *The Egyptian journal of neurology, psychiatry and neurosurgery*, 54(1), p.33.
10. Gonzalez N, Murayama Y, Nien YL. (2004): Treatment of unruptured aneurysms with GDCs: clinical experience with 247 aneurysms. *Am J Neuroradiol*; 25(4):577-583
11. Renowden SA, Benes V, Bradley M, Molyneux AJ. (2009). Detachable coil embolization of ruptured intracranial aneurysms: a single center study, a decade experience. *Clin Neurol Neurosurg*; 111(2):179-188.
12. Hasan M. Halil O, Ahmet S, Ertuğrul C, Gurkan G, Kayhan K. (2013). Coil embolization in 481 ruptured intracranial aneurysms: angiographic and clinical results. *Diagn Interv Radiol*; 19:165–172.
13. Cognard C, Weill A, Castaings L. (1998). Intracranial berry aneurysms: angiographic and clinical results after endovascular treatment. *Radiology*; 206(2):499-510.
14. Holmin S., Krings T., Ozanne A., Alt J., Claes A., Zhao W., et al. (2005). Intradural Saccular Aneurysms Treated by Guglielmi Detachable Bare Coils at a Single Institution Between 1993 and 2005. *Stroke*. 39, (8):1244-35.
15. Johnston SC, Dowd CF, Higashida RT. (2008). Predictors of rehemorrhage after treatment of ruptured intracranial aneurysms: The Cerebral Aneurysm Rerupture After Treatment (CARAT) study. *Stroke*;39:120–25
16. Henkes H, Fischer S, Weber W. (2004). Endovascular coil occlusion of 1811 intracranial aneurysms: early angiographic and clinical results. *Neurosurgery*; 54(2):268-280.
17. Grunwald IQ, Papanagiotou P, Struffert T. (2007). Recanalization after endovascular treatment of intracerebral aneurysms. *Neuroradiology*; 49:41–47.