

Complex Odontoma impeding eruption of Permanent Maxillary Central Incisor: A Case Report

ABSTRACT:

Odontomas are benign odontogenic tumours made up of epithelial and mesenchymal cells. They are mostly associated with disorders of tooth eruption, causing impaction and/or delayed tooth eruption, and sometimes accidental findings on routine radiological examination. The purpose of this article is to present and discuss the case of a 21-year-old male patient who complained of obstructing the eruption of the right maxillary permanent central incisor. Radio-opaque calcified masses were revealed on a radiograph and masses were surgically removed.

Keywords- Complex, Odontoma, Impeding, Central incisor, Maxilla, Eruption

INTRODUCTION:

“Odontoma represents a hamartomatous malformation rather than a true neoplasm and they constitute 22% of all odontogenic tumors of the jaw. This lesion is composed of more than one type of tissue and therefore has been called a composite odontoma”¹.

“On the basis of histopathology, Odontoma can be divided into 2 groups Complex Odontoma and Compound Odontoma. Odontomas whose structures resemble to the anatomic structure of normal teeth, except that they are often smaller than typical teeth and have been termed compound composite odontomas”². “On the contrary, when the calcified dental tissues are simply an irregular mass bearing no morphologic similarity even to rudimentary teeth, the term complex composite odontoma is used. The Compound form of an odontoma is more common than the Complex type”³.

This article discusses a case of an unerupted right maxillary permanent central incisor due to the presence of complex odontoma in a young patient with its clinical presentation, radiographic features, histopathological features, and its treatment plan.

CASE REPORT:

A 21-year-old male patient reported to the department of Oral and Maxillofacial Pathology at Government dental college and hospital, Aurangabad, Maharashtra on 10th march 2021 with a complaint of a missing tooth in the upper front region of the jaw. Medical history was noncontributory and there was no hereditary disease in antecedents. Extra-orally there was no facial asymmetry. Intraoral examination revealed a permanent dentition with missing 11. On inspection erupting 11 was seen on the palatal aspect and mesially tilted fully erupted 12 was present (Fig. 1a).

On radiographic examination, Cone beam computed tomography revealed a radiopaque mass present in the region of 11 obstructing its eruption. (Fig 1 c&d).

Based on clinical and radiographic findings, the case was provisionally diagnosed as odontoma.

After discussing all possible lines of treatments and consultation with the orthodontist, probable outcomes were explained to the patient and informed consent was signed by the patient's legal guardian. The patient was prescribed preoperative antibiotics. Surgical removal of the bony lesion together with exposure of the crown of the right maxillary central incisor under local

anesthesia was planned. After following all the COVID-19 safety protocols and maintaining an aseptic environment, the lesion was approached intraorally by reflecting the mucoperiosteal flap on the palatal surface. The bony lesion was excised with minimal bone removal using a surgical bur and saline irrigation as a coolant. The lesion was completely excised and after that thorough curettage was done. Hemostasis was achieved with the palatal flap repositioned and sutured using silk suture. Proper postoperative instructions and medications were given to the patient. A 7-day follow-up was recommended to exclude any postoperative complications. The specimen was transported for histopathological examination in 10% formalin. (Fig. 1b). Gross pathological examination showed 2-3 irregular hard calcified masses along with 11.

Microscopically, the hematoxylin and eosin-stained (H&E) section showed structures exhibiting an irregular arrangement of dentin, mesenchymal tissue resembling pulp (Fig.2 a&b), and a small basophilic area of cementum-like material (Fig.2 c&d). Hence correlating clinical and histopathological features the final diagnosis was given as 'Complex Odontoma'.

DISCUSSION

"In clinical settings, dentists often encounter the problem of tooth impaction, which has been defined as a situation where a tooth fails to erupt into a normal functional position by the expected times. For tooth impaction, numerous local etiologic factors have been described. These include odontomas, odontogenic tumors, ankylosis, trauma, and dentigerous cysts. Among these pathological factors, odontoma is the most common etiological factor"⁴.

"In a broad sense, Odontoma is a mixed odontogenic tumor exhibiting complete differentiation of ameloblasts and odontoblasts which forms enamel and dentin. These hard structures are usually laid down in an abnormal pattern because the organization of odontogenic cells failed to reach the normal state of morpho-differentiation. The term Odontoma was given by Paul Broca in 1867"⁵.

Hisatomi et al suggested that "odontomas are inherited or mutagenic interference in the genetic control of tooth development"⁷. However, Raghavendra M Shetty et al suggested that "trauma and infection may lead to the development of such a lesion"⁸. In our case, the most likely etiology appeared to be local trauma. additionally resulting in a displacement of tooth germ and subsequent tooth malformation and impaction.

"Extraneous odontogenic epithelial cells are responsible for the histogenesis of odontoma. When odontogenic buds are divided into several particles, they may develop individually to become numerous, closely positioned malformed teeth or tooth-like structures. When the buds develop without such uncommon division and consist of haphazard conglomerates of dental tissues, they may develop into complex odontomas. The tooth-like structures impacted in our case did not radiographically resemble a permanent maxillary central incisor"⁹.

The histo-morpho differentiation of the Odontoma can follow sequelae from Ameloblastic fibroma which leads to an Ameloblastic fibroodontome. It consists of varying amounts of calcified dental tissue and dental papilla-like tissue. The ameloblastic fibro-odontome is considered as an immature precursor of complex odontoma. The exact etiology of the odontoma is unknown.

According to WHO classification (2017), "odontomas can be divided into two groups based on pathogenesis":⁶

1. Complex odontoma: When the calcified dental tissues are simply arranged in an irregular mass bearing no morphologic similarity to rudimentary teeth.
2. Compound odontoma: Composed of all odontogenic tissues in an orderly pattern that results in many teethlike structures but without morphologic resemblance to normal teeth.

“Complex odontomas constitute about 5 to 30% of all odontogenic tumors. They are usually detected in 1st and 2nd decade of life and the mean age at the time of diagnosis is 14 years. In our case Complex odontoma was diagnosed at the age of 21 years. The majority of odontomas are asymptomatic and rarely cause swelling, pain, suppuration, bony expansion, and displacement of teeth. These lesions are commonly small, seldom larger than a tooth. Odontomas are accidental findings on routine radiographic examination in dental treatment”⁷. An odontoma is essentially a benign lesion, but often causes disturbances in the eruption of its associated tooth. The finding of our case is in accordance with the mentioned literature.

Moreover, it was also slightly exposed to the oral cavity which contributed to its rarity. Erupted odontomas are quite infrequent accounting for only 1.6% of cases and are mostly associated with impacted teeth.

“Compound odontomas are twice as common as complex odontomas. Particularly, the compound variant is more frequently found in the maxillary anterior region while the complex variant is more often present in the posterior region of the mandible”^{2,11 12}. “In our case, the lesion was identified as a complex odontoma and was found in the anterior maxilla” which is in accordance with RM Shetty et al and Shukla A. et al case report.

“Radiographically Complex odontoma shows an irregular mass of calcified material with the radiodensity of tooth structures having no anatomical similarity to tooth and is surrounded by a narrow radiolucent margin. It is differentiated from Ossifying fibroma and Osteoblastoma wherein Ossifying fibroma shows regular radio-opaque mass devoid of radiolucent rim & Osteoblastoma is not associated with the tooth-bearing area”⁵. In our case radiographic finding is favored with the above literature.

“On histopathological examination Complex Odontoma illustrates haphazardly arranged structures of enamel matrix, dentin, cementum, and pulp tissues”⁵. Also, In our case histopathologically irregular arrangement of dentin, mesenchymal tissue resembling pulp, and a small area of the basophilic component which resembles to cementum-like material. It is differentiated from the Ameloblastic fibro-odontoma which shows condensation of the mesenchymal component with the Ameloblastic follicle.

“Surgical removal of an odontoma is the only sole treatment of choice till now. In our case also the same line of treatment was followed”¹⁰.

CONCLUSION:

Radiographic examination of all patients that present clinical evidence of delayed permanent tooth eruption or temporary tooth displacement, with or without history of previous dental trauma should be performed. Early detection of odontomes allows for the use of a less complex and less expensive treatment, as well as the normal eruption pattern of permanent teeth that would otherwise be impacted.

CONSENT:

As per international standards or university standards, patient(s) written consent has been collected and preserved by the author(s).

ETHICAL APPROVAL:

As per international standards or university standards are written ethical approval has been collected and preserved by the author(s).

COMPETING INTERESTS:

The authors have declared that no competing interests exist.

REFERENCE :

- 1) Siddhartha SV, Freny K. Complex odontome: a review & case report. *Int J Adv Health Sci.* 2014 Jul;1(3):21-5.
- 2) Satish V, Prabhadevi MC, Sharma R. Odontome: a brief overview. *International journal of clinical pediatric dentistry.* 2011 Sep;4(3):177.
- 3) Patekar D, Kheur S, Gupta AA. Odontoma-A brief overview. *Journal of Oral Disease Markers.* 2018;2:23-5.
- 4) Shukla A, Rai B, Gupta H, Gadhiya V, Patel K. A complex odontoma of the anterior maxilla associated with an unerupted maxillary central incisor: A rare entity. *Journal of Medical Society.* 2022 May 1;36(2):88.
- 5) Dutta SR, Passi D, Sharma S, Singh P, Ahmed M. Erupted large anterior maxillary complex odontoma: A Rare dental hamartoma. *Journal of Clinical and Diagnostic Research: JCDR.* 2016 Sep;10(9):ZJ01.
- 6) Soluk-Tekkesin M, Wright JM. The World Health Organization Classification of Odontogenic Lesions: A Summary of the Changes of the 2022 (5 th) Edition. *Turkish Journal of Pathology.* 2022 Jan 1;38(2):168-84.
- 7) Hisatomi et al Complex Odontome associated with Maxillary Impacted Permanent Central Incisor: A Case Report *International Journal of Clinical Pediatric Dentistry, January-April 2013;6(1):58-61 61 IJCPD*
- 8) Shetty RM, Halawar S, Reddy H, Rath S, Shetty S, Deoghare A. Complex odontome associated with maxillary impacted permanent central incisor: A case report. *International journal of clinical pediatric dentistry.* 2013 Jan;6(1):58.
- 9) Singh G, Singh RK, Das S. Large Complex Odontome of Maxilla: Report of a Case and Literature Review. *Oral & Maxillofacial Pathology Journal.* 2015 Jan 1(1).
- 10) Bueno NP, Bergamini ML, Elias FM, Braz-Silva PH, Ferraz EP. Unusual giant complex odontoma: A case report. *Journal of Stomatology, Oral and Maxillofacial Surgery.* 2020 Nov 1;121(5):604-7.
- 11) Abang ZA, Venkiteswaran IA, Nor WN, Reduwan H. The Unique Case of Rapid Developing Compound Odontomes Following Fibrous Tissue Removal Around Impacted Tooth. *J Pediatr.* 2021;7(3):173-7.
- 12) Choudhary PJ, Gharote HP, Hegde K, Gangwal P. Compound odontoma associated with impacted teeth: a case report. *IJSS Case Rep Rev.* 2014 Aug;1(3):12-5.

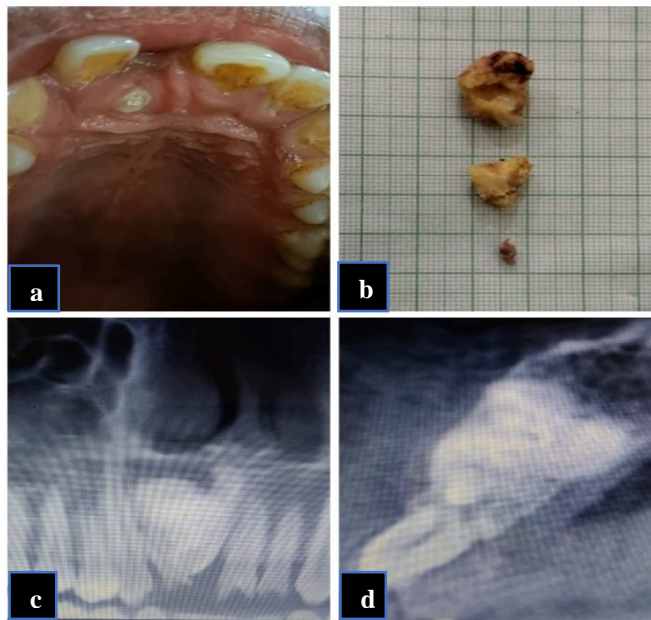


Fig. 1 a: Erupting 11 on palatal aspect. b: Grossing of the specimen showing two calcified irregular masses. C: Radio-opaque structure obstructing eruption of 11. d: Lateral aspect of tooth

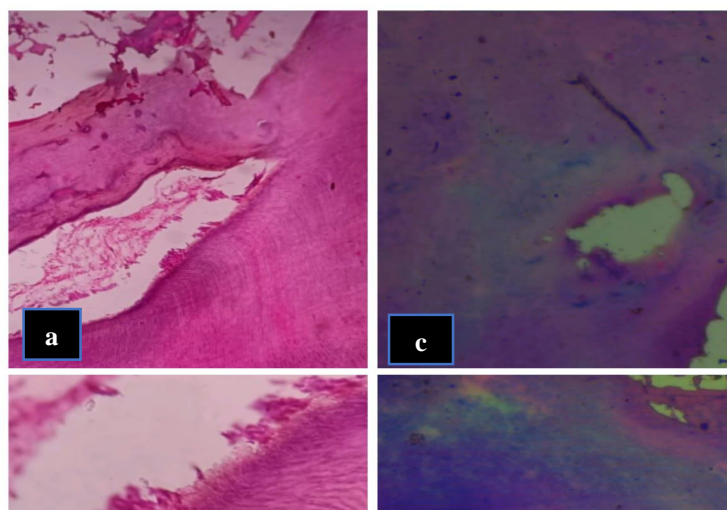


Fig 2 a: 10X Photomicrograph showing an irregular arrangement of dentin, mesenchymal tissue resembling pulp.

b: 40X Photomicrograph showing an odontoblastic layer with irregular arrangement of dentin.

c: Photomicrograph showing a eosinophilic area comprising basophilic material 10X.

d: Photomicrograph showing basophilic area resembling cementum under 40 X