

Case study

Two Cases Of Primary Reshaped Hydatid Cysts Mimicking Digestive Solid Cystic Masses : Surgical Case Reports

Abstract

Introduction

Hydatidosis is a zoonotic parasitosis that affect humans accidentally, localising in the lungs and the liver in 90% of cases. Nevertheless, any organ can be affected. Peritoneal hydatidosis affect 5-16% of the patients. The clinical aspects are very diverse and paraclinical exams can be misleading.

Surgery remains the main radical solution and prevention measures are put to protect susceptible populations.

Presentation of cases

First, we report the case of a 25 y-o fit male, presenting a 3 years history of right flank heaviness-like pain, whom clinical examination found a 6cm firm mass straddling between the right hypochondrium and the right flank, and CT exam showed a 6cm solido-cystic mass on the right flank which may be related to a digestive duplication. Blood investigations were correct.

Surgery revealed a mass of the right hypochondrium adhering to the underside of the greater omentum, transverse colon and posterior parietal peritoneum, that was resected. Anatomopathological examination resulted in a remodeled hydatid cyst.

Secondarily, we report the case of a 28 y-o fit shepherd male, presenting a 1 year history of epigastrium heaviness-like pain, whom clinical examination found a 8cm

firm mass straddling between epigastrium and the umbilicus, and CT exam showed a 7.5cm periumbilical solido-cystic mass. Blood investigations were correct.

Surgery revealed a periumbilical cystic mass adhering to the underside of the greater omentum and transverse colon, that was resected. Anatomopathological examination resulted in a remodeled hydatid cyst.

Discussion

The primary form of peritoneal hydatidosis is rare, though theoretically that it is due to blood-forming damage by the arterial route. It can be retained only if the patient has no other hydatid localisation. The clinical presentation can be very polymorphic, going from noisy symptomatology (peritonitis or febrile occlusive syndrome) to less noisy ones.

However, differential diagnosis can be made with other cystic or pseudo-cystic masses of the peritoneum. Hydatid serology, one of the main complementary investigations in the diagnosis of hydatid cysts, is losing its interest due to its delay diagnosis in relation to the emergency of the therapeutic decision. However, its results confirm the diagnosis of hydatidosis retrospectively and serve as a monitoring tool.[6]

Conventional surgery and celiosurgery are the therapeutic options mainly suggested, with an inclination to open surgery. Cystectomy, pericystectomy, pericystectomy and omentectomy are the techniques described frequently but the resection of the protruding dome is the technique of choice whenever the location is delicate that can expose to dreadful post-operative complications.

Without forgetting the risk of recurrences that are frequent.

Albendazole's efficiency as a medical treatment adjuvant to surgical treatment has been described also.

Distant follow-up based on clinical, serological and ultrasound check-ups spread over 5 years has proved its leverage. every 3 months in the first year and every 6 months for the next 2 years.

Conclusion

Due to its confusing symptomatology and rare localization, peritoneal hydatidosis remains a confusing diagnosis. The primary localization of the hydatid cyst in the peritoneum is rare, its clinical symptomatology is confusing.

Preoperative diagnosis of peritoneal hydatidosis is sometimes difficult.

Surgery is always the treatment of choice and re-infestation is possible, that is why preventive actions aimed to interrupt the parasite's life cycle are implemented.

Keywords

Hydatidosis, parasitosis, cyst, peritoneum, visceral surgery, case report.

1. Introduction

Hydatid parasitosis is a severe pathology endemic in North Africa. Although the pulmonary and hepatic localizations represent 90% of the localizations, the hydatid cyst can affect any organ[1]. Hydatid cysts with peritoneal location are among the misleading cases. The clinical aspects of the hydatid cyst of the liver are very diverse. No clinical sign is pathognomonic. Abdominal ultrasound is the method of choice for the diagnosis of hepatic hydatidosis, CT scan is not essential for diagnosis, but it is indicated in case of diagnostic difficulties.[2][3]

Its radical treatment is surgical and antiparasitic drug treatment prevents recurrences.[4]

We report a new case of reshaped hydatid cyst mimicking a digestive solid cystic mass which seemed interesting to us to document .

2. Observation

Case 1:

A 25-year-old male , previously fit and healthy presented to our department with a 3 years history of paroxysmal heaviness like pain in the right hypochondrium and right flank, without notion of vomiting or signs of cholestasis, nor notion of contact with dogs or living in a rural environment, all evolving in a context of conservation of the general state. On examination he looked well and healthy (performance status 0), BMI at 25kg/m². Flexible abdomen with the presence of a firm mass straddling the right hypochondrium and the right flank measuring 6cm mobile with respect to the superficial plane. CT scan abdomen showed the presence of a solido-cystic mass on the right flank with a long axis of 61 mm which may be related to a digestive duplication with cellular debris within it, appendicular mucocele or peritoneal pseudomyxoma remain less likely, the liver is of normal volume, of homogeneous density and regular contours, absence of anomaly of the intra or extra hepatic bile ducts, the spleen and the pancreas are of normal CT

appearance, the kidneys are of normal morphological and functional appearance, absence of deep adenopathy, absence of peritoneal effusion (Figure 1,2). Blood investigations revealed negative tumor markers, a correct cholestasis check-up and a good prothrombin value (93.6%). The patient underwent open surgery, discovering a mass of the right hypochondrium adhering to the underside of the greater omentum, transverse colon and posterior parietal peritoneum, the appendix is macroscopically normal, so proceeded to the release of the mass then its resection after vascular control, no drainage was needed (Figure 3). Pathological examination revealed a remodeled hydatid cyst. Postoperatively, follow-up care was unremarkable.

Patient was declared discharged after 3 postoperative days. At 1 year follow up, patient was without evidence of recurrence.

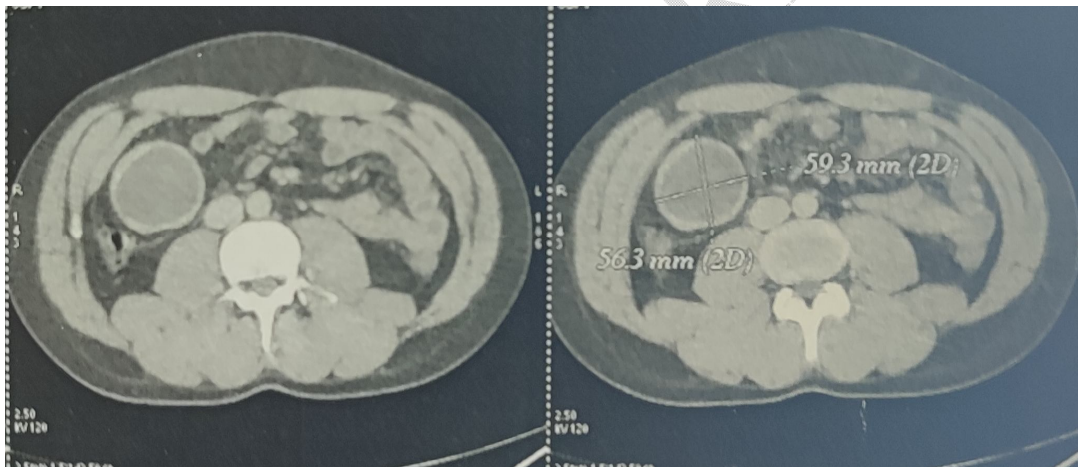


Figure 1: Axial scan section showing the solido-cystic mass in the right flank

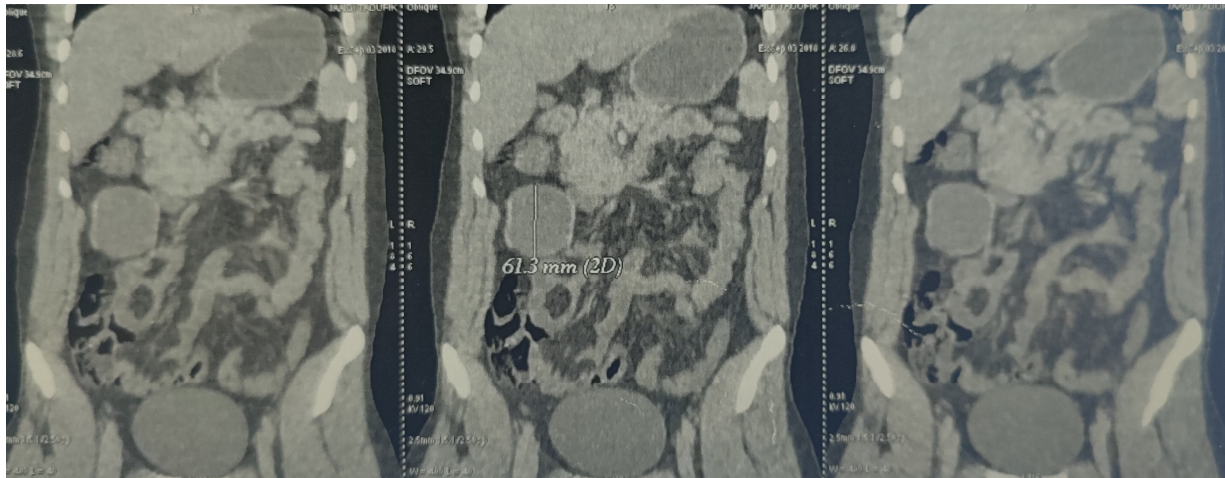


Figure 2: Frontal scan section showing the solido-cystic mass in the right flank

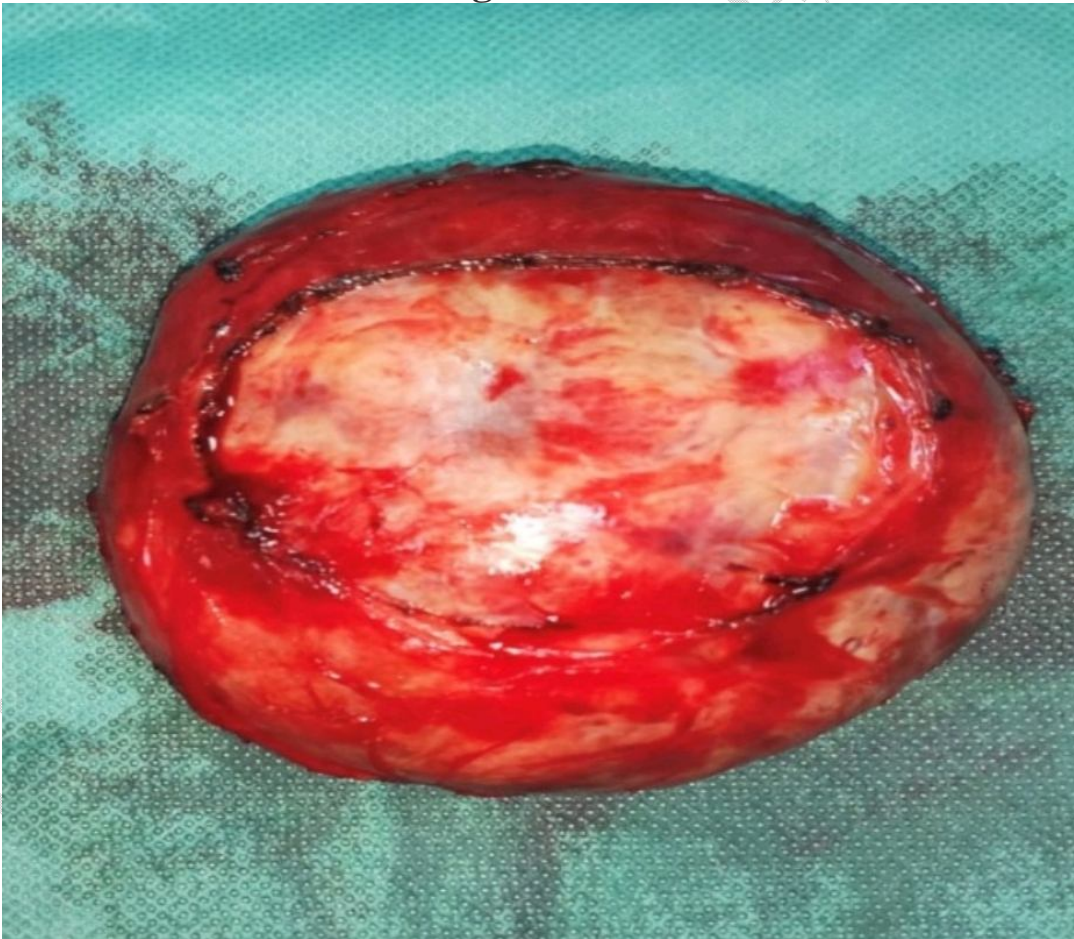

Figure 3: Surgical specimen

Case 2:

A 28-year-old male, working a shepherd and living a rural environment, previously fit and healthy presented to our department with a 1 year history of heaviness like pain in the epigastrium and in the umbilicus, without notion of vomiting or signs of cholestasis, all evolving in a context of conservation of the general state. On examination he looked well and healthy (performance status 0), BMI at 21.5 kg/m². Flexible abdomen with the presence of a firm mass straddling the epigastrium and the umbilicus measuring 8cm mobile with respect to the superficial plane. CT scan abdomen showed the presence of a periumbilical solidocystic mass with a long axis of 75mm which may be related likely to a cystic mass of the peritoneum, the liver is of normal volume, of homogeneous density and regular contours, absence of anomaly of the intra or extra hepatic bile ducts, absence of deep adenopathy, absence of peritoneal effusion (Figure 4). Blood investigations revealed negative tumor markers. The patient underwent open surgery, discovering a periumbilical cystic mass adhering to the underside of the greater omentum and transverse colon, the appendix is macroscopically normal, se proceeded to the release of the mass then its resection after vascular control, no drainage was needed (Figure 5). Pathological examination revealed a remodeled hydatid cyst. Postoperatively, follow-up care was unremarkable.

Patient was declared discharged after 5 postoperative days. At 1 year follow up, patient was without evidence of recurrence.

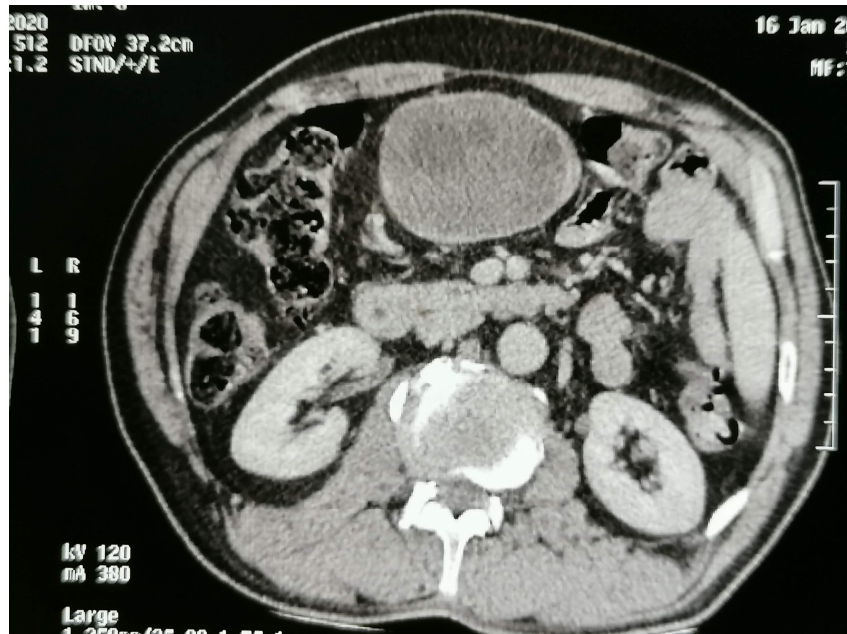


Figure 4 : Axial scan section showing the periumbilical solido-cystic mass

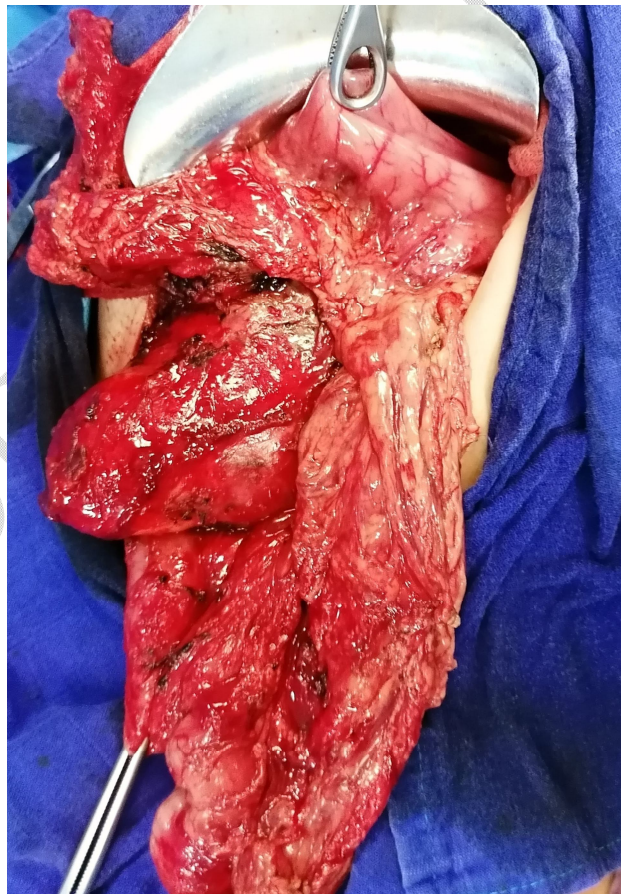

Figure 5: Per operative image

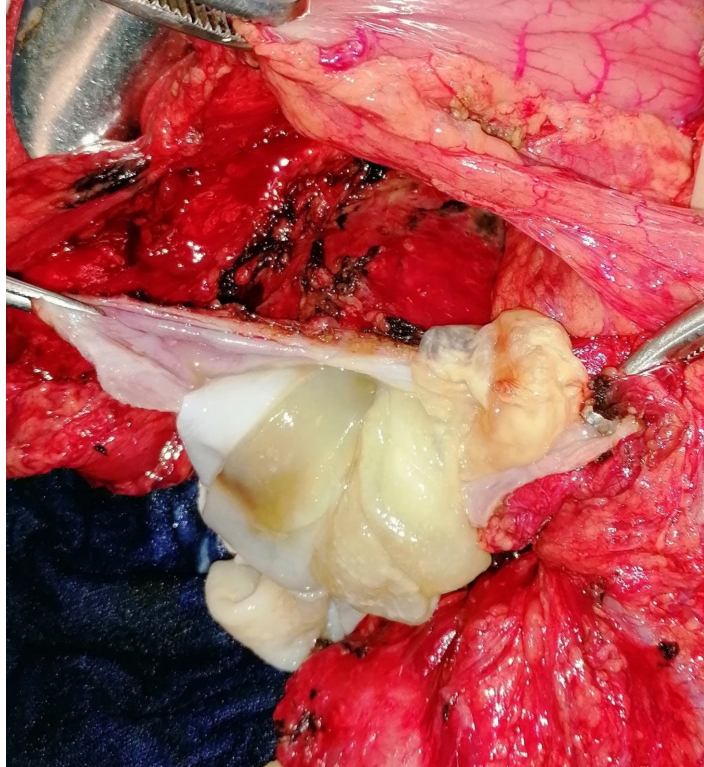


Figure 6: Per operative image

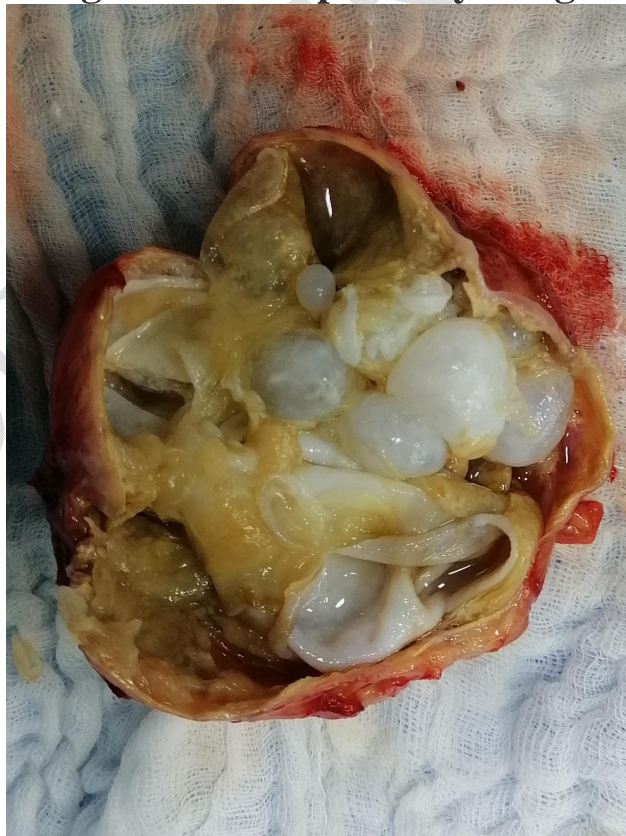

Figure 7: Surgical specimen

3. Discussion

Hydratic disease is common in north africa, where it is endemic. It is located in any point of the body, as soon as the liver and lung filters are exceeded.[1]

Peritoneal hydatidosis accounts for 5-16% of hydatidosis. It is almost always secondary to hepatic hydatidosis, acute rupture of hydatid cyst in the peritoneum is a rare complication, its frequency varies from 1 to 2%, according to the literature series.[5][6]

However, the primary form is rare and is thought to be due to blood-forming damage by the arterial route, suggesting a rupture of the liver or lung filter by the parasite in order to gain access to the main blood traffic. This form can be retained only if the patient has no other hydatid localisation (liver, lung, splenic...) [5][6]. This was the case for our patients.

The clinical presentation was very polymorphic.

If in our case, the clinical presentation was dominated by paroxysmal heaviness like pain evolving for 3 years (case1) and 1 year(case2), in the series of El Mansari et al., having collected 12 cases of peritoneal hydatidosis, for two patients the condition was latent, the diagnosis was made for the first by an abdominal ultrasound, for the second, during the the surgical treatment of an umbilical hernia. For a third patient, painful symptomatology evolving for one month, wrapped up afterwards by a

febrile occlusive syndrome. On examination, the abdomen was distended and very painful. He was a hydatid peritonitis secondary to a segment I hydatid cyst breakage.

In other patients, symptomatology was less noisy.

Indeed, the finding of abdominal mass is common, found clinically in our patient (94% for Moumen et al., 40% for Haddad et al., 50% for El Mansari et al.).[6][7][10]

Ultrasound is the essential examination. Diagnostic reliability is estimated at 96%.CT would allow for easy and more accurate diagnosis than ultrasound, especially in peritoneal localization. It has been very little evaluated in the literature. Jouini et al. emphasize his interest in a single case in the diagnosis of intraperitoneal breakage of a liver hydatid cyst. The MRI would provide diagnostic support in cases where cysts are not characteristic for ultrasound and scanning.[8]

The advantages of CT over ultrasound are better identification of non-specific ultrasound aspects; easy study of all or part of calcified hydatid cysts; the determination of the exact size of the cyst and its relationship to neighboring organs; the detection of complications, in particular superinfection by the detection of intra-cystic gas in post-operative settings; the study of post-operative complications, especially in obese and multioperated patients; the diagnosis of recidivism.[11][12]

Differential diagnosis can be made with other cystic or pseudo-cystic masses of the peritoneum: tuberculosis, gelatinous disease, serous cyst and cystic lymphangioma.[14]

Hydratic serology, one of the main complementary investigations in the diagnosis of hydatid cysts, is losing its interest due to its delay diagnosis in relation to the emergency of the therapeutic decision. However, its results confirm the diagnosis of hydatidosis retrospectively and serve as a monitoring tool.[6]

Conventional surgery remains the best therapeutic option for the moment, if is referred to as the GOLD STANDARD. Celiosurgery retains its specific indications.

The treatment of peritoneal hydatid cyst can be cystectomy, the technique performed for our patient, pericystectomy, pericystectomy and omentectomy whenever possible. The resection of the protruding dome is the technique of choice whenever the cyst is deep, in contact with the vicinity viscera or vessels. However, partial or subtotal cystectomy may be performed for avoid injury to neighboring organs and vessels. [1][6]

On the other hand, the resection of the protruding dome exposes to dreadful post-operative complications, dominated mainly by a suppuration of the residual cavity (nine cases in the series by Moumen et al. , three cases in the series of El Mansari et al.) .

In addition, péritonéal hydatidic cysts recurrences are common (39% in the series of Moumen and al.).

For our patients, there was no recurrence, but the number of patients is smaller and so is the retreat.

Medical treatment would be an useful adjuvant to surgical treatment. The efficacy of albendazole has been emphasized by some authors as a lone treatment or complementary to surgery, it would prevent secondary peritoneal echinococcosis. [9]

In our study, our patients had not been treated by albendazole post-operatively.

Distant follow-up is based on clinical, serological and ultrasound checks every 3 months in the first year and every 6 months for the next 2 years. Finally every year until the 5th year. If, at that date, the paraclinical assessment remains negative, monitoring may be stopped[15]. In case of clinical, ultrasound and serological discrepancy, CT scan should be requested. This surveillance strategy is hampered by the non-cooperation of patients, who are often of modest socio-economic levels. We emphasize the importance of patient information and awareness and the value of long-term follow-up given the potential risk of recurrence.

4. Conclusion

The primary localization of the hydatidic cyst in the peritoneum is rare, its clinical symptomatology is confusing.

Preoperative diagnosis of peritoneal hydatidosis is sometimes difficult. Diagnosis should be discussed in front of any process that takes place in the intra peritoneal area, especially in a country where the disease is endemic, after having eliminated a malignant origin.

Surgery is the treatment of choice.

Re-infestation is possible, the need for preventive actions aimed to interrupt the parasites life cycle through hygiene measures and veterinary control of slaughterings.

References

- 1- J. Sakhri (1), A. Ben Ali (2) The hydatid cyst of the liver, development
(1) General and Digestive Surgery Department, Surgery Research Unit UR/17/02, CHU Farhat Hached - Sousse (Tunisia).
- 2- Jamal Bouihi et Al, Primary pelvic hydatid cyst: about a case, Pan Afr Med J. 2016; 25:239.
- 3- Lamrani, Y.A., Alami, B., Souiki, T. et al. Hydatid cyst. J Afr Hepato Gastroenterol 8, 230–232 (2014). <https://doi.org/10.1007/s12157-014-0548-6>
- 4- Gharaba Safae, Fouad Hamid, P181 - Peritoneal hydatidosis. About 27 cases. SNFGE
- 5- Prousalidis J, Tzardinoglou K, Sgouradis L, Katsohis C, Aletras H. Uncommon sites of hydatid disease. World J Surg 1998; 22:7-22.
- 6- Moumen M, El Alaoui ME, El Mansouri A, Mokhtari A, Elfares F. Peritoneal echinococcosis. Diagnostic and therapeutic problems apropos of 34 cases. Surgery 1991; 117: 854-9

- 7- O. El Mansari, A. Zentar, K. Sair, F. Sakit, A. Bounaim, I.M. Janati. Peritoneal hydatidosis. About 12 cases. *Ann Chir* 2000; 125: 353–7
- 8- Severino ADM, Giancarlo CC, Franco AN, Gianpiero PA, Sebastiano GM, Paolo MC. Hydatid disease: MR imaging study. *Radiology* 1990; 175:701-6.
- 9- Saimot AG, Meulemans A, Cremieux AC, Giovanangeli MD, Hay JM, Delaitre B, et al. Albendazole as a potential treatment for human hydatidosis. *Lancet* 1983; 2:652-6.
- 10- Haddad N, Tabbane S, Elouze N. Clinical aspects and diagnostic problems of echinococcosis of the peritoneum. *Medical Tunisia*. 1976; 54: 753-64.
- 11- Khiari A, Mzali R, Ouali M, Kharrat M, Kchaou MS, Beyrouiti MI. Hydatid cyst of the pancreas. About 7 cases. *Ann Gastroenterol Hepatol (Paris)*. 1994 May-Jun;30(3):87-91.
- 12- Caremani M, Benci A, Maestrini R, Rossi G, Manchetti D. Abdominal cystic hydatid disease: classification of sonographic appearance and response to treatment. *J Clin Ultrasound*. 1996 Nov-Dec;24(9):491-500.
- 13- Gharbi HA, Hassine W, Brauner MW, Dupuch K. Ultrasound examination of hydatid liver. *Radiology* 1981;139:459-463..
- 14- S. BENAMR, E. MOHAMMADINE, A. ESSADEL, K. LAHLOU, A. TAGHY, B. CHAD, A. ZIZI, A. BELMAHI. , SECONDARY PERITONEAL HYDATIDOSIS. FOCUS ON A SERIES OF 50 CASES, *Médecine du Maghreb* 2000 n°82
- 15- Jung G, Krug B, Zieren HU, Hemme A, Lackner K. Postoperative follow-up in hepatic echinococcosis. *Dtsch Med Wochenschr*. 1996; 121:611-16.