

Case study

Corneal abscess on mini-scleral contact lens : clinical case

Abstract:

Mini-scleral **lens'are** large diameter rigid lenses that are used to rehabilitate vision when the corneal shape is distorted from disease, scarring or after a corneal graft procedure, however, there are relatively few reports regarding their potential complications, in this case we describe the case of a corneal abscess in a mini-scleral lens wearer with keratoconus in order to determine whether this type of contact lens presents an increased risk of infection.

Keywords:

mini-scleral contact lens, Corneal abscess, keratoconus.

Introduction

When normal gas permeable contact lenses are no longer adapted, scleral contact lenses are used to ensure good eyesight in patients with high or irregular astigmatism, such as in keratoconus or following keratoplasty.

With the exception of Acanthamoeba keratitis, infectious problems in patients wearing scleral contact lenses are extremely rare, but there are no published reports on the development of bacterial abscesses while wearing mini-scleral contact lenses.

The purpose of our study was to report a scleral lens wearer with keratoconus who developed a corneal abscess in order to ascertain whether this form of contact lens has an elevated risk of infection.

Case Study

A 22-year-old female patient, wearing mini-scleral lenses since 2017 for bilateral keratoconus; having undergone transfixing Keratoplasty of the left eye in 2019, presents with redness, tearing, photophobia and decreased visual acuity in her right eye for a week.

Best corrected visual acuity (BCVA) was 0,2 right eye with contact lens, and 0,7 on left eye with contact lens.

Slit lamp examination showed on the right eye a conjunctival hyperemia corneal abscesses central with stromal infiltrates positive fluorescein staining without anterior chamber cells, figure:1, Intraocular pressure (measured with Air-puff tonometer) and dilated fundus examination were normal. The left eye appeared normal.

The patient was wearing wide scleral lenses, with the following parameters: OD: A44 TE plane L+1OG: A51 TP +5.25. Worn for 18 hours daily. she was using Regard K RGP solution (Advanced Eyecare Research, Horus Pharma, France) for disinfection and each morning one vial of Celluvisc (Allergan, France) was placed into each lens at insertion. The affected lens was one months old. Corneal topography showed keratoconus with a central nipple cone appearance (pachy430um ; Km 68.4) figure:2 . a corneal scraping was carried out, the contact lenses, the case, the removal plunger, the saline solution and the polyvalent solution for contact lenses were also put in culture for cytobacteriological and parasitic study which objectified the presence of Gram-positive bacteria of streptococcus epidermidis type.

Management consisted of cessation of right contact lens wear, hourly eye drops of fortified antibiotics ceftazidime + vancomycin, daily eye washes with saline, healing eye drops, cycloplegic eye drops.

An improvement was observed from the 4th day with reepithelialization of the surface of the infiltrate, regression of the conjunctival inflammation, recovery of a visual acuity of 10/10f (OD) figure 3 .

This pleads in favor of a bacterial origin of the ulcer.

Discussion

Mini scleral lenses do not touch the cornea because they create a space between the cornea and the lens that is filled with sterile saline solution. These lenses are used for improving vision in patients with high or irregular astigmatism such as keratoconus, pellucid marginal degeneration, keratoglobus, and post-keratoplasty astigmatism. The other indication for these lenses is in patients having ocular surface disease such as Stevens–Johnson syndrome, dry eyes, graft-vs-host disease, and ocular cicatricial pemphigoid [1][2].

There aren't many publications about abscesses or infectious keratitis linked to scleral lenses; the sole one that has been documented in the literature is an amoebic infection with *Acanthamoeba* [3].

The main infectious risk factors for people who wear scleral contact lenses include hypoxic changes to the corneal epithelium because of the large diameter and minimal tear exchange, overnight storage of the scleral lens in saline rather than multipurpose contact lens solutions, not rubbing the contact lens during cleaning, and the space between the cornea and the back surface of the scleral lens, which may act as a fluid reservoir and a bacterial growth environment [4]. If the lens is highly contaminated with germs, Holden and colleagues have demonstrated that an ocular reaction for soft lenses can happen within eight hours of closed eye usage. This mechanism may help explain how acute infiltrative keratitis can potentially occur with a scleral lens if the lens is dirty, and if it is not well fitted. [5]

The occurrence of keratitis is most often associated with prolonged soft contact lens wear.

Bacteria that cause an acute red eye reaction are adherent to the contact lens rather than colonizing the ocular surface or eye lids, which is consistent with the observation that symptoms rapidly subside once the lens is removed [6]. Both Gram-negative *Haemophilus influenzae* bacteria and Gram-positive *Streptococcus pneumoniae* organisms have been iso-lated from the lenses of patients with acute red eye in extended wear [7] [8]. *Serratia marcescens* and *Pseudomonas aeruginosa* are two more Gram-negative bacteria that have been found in the lenses and solutions of patients with acute red eyes [9].

The contact lens casing is frequently polluted, and contamination of the lens itself is also known to be linked to it. [10]

Acute non-ulcerative keratitis is a rare complication of daily wear and extended wear of gas permeable lenses and does not appear to have been previously reported in association with scleral lenses.

Conclusion

In conclusion, corneal abscesses on scleral lenses are uncommon infections that are primarily parasitic and infrequently bacterial. They have a variety of risk factors and can evolve differently depending on the type of germ involved.

Patients who use scleral contact lenses need to be firmly advised to take preventative precautions.

References

- [1] V.M. Rathi, P.S. Mandatharam, M. Taneja, V.S. Dumpati Sangwan, Scleral lens for keratoconus: technology update, *Clin Ophthalmol* 9 (2015) 2013–2018.
- [2] Jackson AJ, Sinton JE, Frazer DG, Morrison E. Therapeutic contact lenses and their use in the management of anterior segment pathology. *JBrContact Lens Assoc* 1996
- [3] Sticca, M. P., Carrijo-Carvalho, L. C., Silva, I. M. B., Vieira, L. A., Souza, L. B., Junior, R. B., Freitas, D. (2018). Acanthamoeba keratitis in patients wearing scleral contact lenses. *Contact Lens and Anterior Eye*, 41(3), 307–310. doi:10.1016/j.clae.2017.12.00
- [4] Sticca MP, Carrijo-Carvalho LC, Silva IMB, Vieira LA, Souza LB, Junior RB, Carvalho FRS, Freitas D. Acanthamoeba keratitis in patients wearing scleral contact lenses. *Cont Lens Anterior Eye*. 2018 Jun;41(3):307-310. doi: 10.1016/j.clae.2017.12.004. Epub 2017 Dec 6. PMID: 29221710.
- [5] Holden BA, La Hood D, Grant T, Newton-Howes J, Baleriola-Lucas C, Willcox MD, Sweeney DF. Gram-negative bacteria can induce contact lens related acute red eye (CLARE) responses. *CLAO J* 1996; 22: 47– 52.
- [6] Bruce AS, Loughnan MS. *Anterior Eye Disease and Therapeutics A-Z*. 2nd edn. Sydney: Elsevier, 2011. p 72–73.
- [7]. Sankaridurg PR, Willcox MDP, Sharma S, Gopi-nathan U, Janakiraman D, Hickson S, Vuppala N et al. Haemophilus influenzae adherent to contact lenses associated with production of acute ocular inflammation. *J Clin Microbiol* 1996; 34: 2426–2431.

[8]. Sankaridurg PR, Sharma S, Willcox M, Sweeney DF, Naduvilath TJ, Holden BA, Rao GN. Colonization of hydrogel lenses with *Streptococcus pneumoniae*: risk of development of corneal infiltrates. *Cornea* 1999; 18: 289–295.

[9]. Holden BA, La Hood D, Grant T, Newton-Howes J, Baleriola-Lucas C, Willcox MD, Sweeney DF. Gram-negative bacteria can induce contact lens related acute red eye (CLARE) responses. *CLAO J* 1996; 22:47–52

[10] Boost MV, Cho P. Microbial Flora of tears of orthokeratology patients, and microbial contamination of contact lenses and contact lens accessories. *Optom Vis Sci* 2005; 82: 451–458

Figures

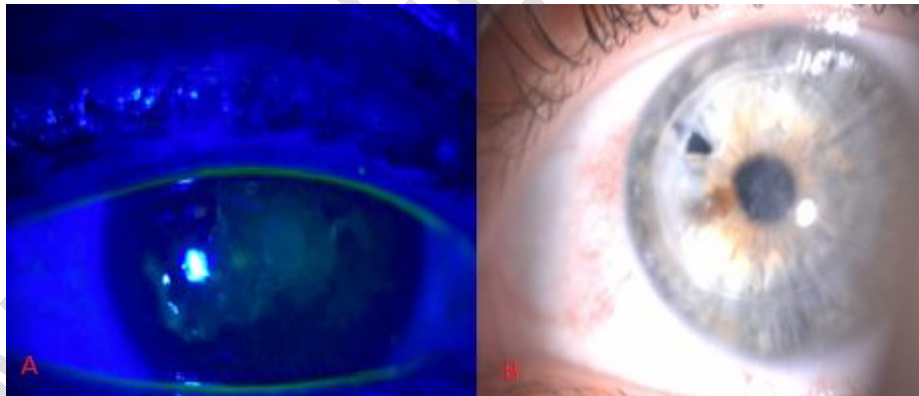


Figure.1: A: .Clinical image of fluorescein staining of cornea

B: .left eye with corneal graft appeared normal

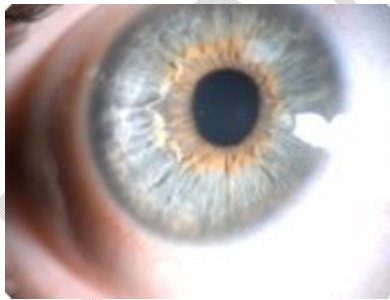

Figure 3 : favorable evolution under antibiotic therapy