

**Achalasia in human immunodeficiency virus-  
tuberculosis co-infected adolescent: A case  
report**

---

**ABSTRACT**

**Aims:** To sensitize clinicians on the need to consider achalasia when confronted with dysphagia in human immunodeficiency virus (HIV) infected children.

**Presentation of case:** A 14-year-old HIV-infected boy presented with 4 years of progressive worsening difficulty and painful swallowing, initially to solid food and gradually including liquid diet and water. There were associated intermittent vomiting, weight loss, and recurrent fever. Examination revealed a stunted and chronically ill-looking boy, weighed 22.5Kg and measured 139cm in height, 48.3% and 86.3% of the expected for age respectively. He had generalized lymphadenopathy and whitish patches on the tongue. Initial assessments were oesophageal candidiasis, pulmonary tuberculosis, and achalasia. Chest X-ray and stool gene Xpert confirmed *Mycobacterium tuberculosis*. The cluster of differentiation (CD) 4 count was 380 cells/ml. Barium swallow and upper gastrointestinal endoscopy were not done because of financial constraints. He had anti-Koch's drugs and oral fluconazole for 6 months and 8 weeks respectively, and later highly active antiretroviral therapy. Despite the completion of the fluconazole, the presented symptoms got worsened and the patient could

not even take his medications, and his weight dropped to 15kg. Barium swallow and upper GI endoscopy done later confirmed achalasia. He had a successfully modified Heller's myotomy procedure after which he could eat, drink and take his medications. He was discharged and kept his regular clinic appointments with appreciable weight gain.

**CONCLUSION:** Achalasia could occur in HIV-infected children when presented with dysphagia and therefore, a high index of suspicion is needed to make a timely diagnosis to avoid complications and death.

*Keywords: Achalasia, HIV, Tuberculosis, Infection, Adolescent*

## 1. INTRODUCTION

The primary function of the oesophagus is for the transportation of food and water including medications from the mouth to the stomach through a wave of muscular contractions called peristalsis.<sup>1</sup> The oesophagus plays an essential role in the digestive system and as a result, any abnormality be it congenital or acquired: infectious or non-infectious is capable of causing marked morbidity and /or mortality.<sup>1</sup>

With their attendant signs and symptoms, Oesophageal diseases are not uncommon in children infected with the human immunodeficiency virus (HIV).<sup>2</sup> Many times, they have the characteristics of being opportunistic (for example, oesophageal tuberculosis) and they may present with odynophagia, dysphagia, and retrosternal pain.<sup>3</sup> These symptoms are in fact the most common gastrointestinal complaints among people living with HIV.<sup>4</sup> About 40 percent of patients with acquired immunodeficiency virus syndrome (AIDS) may develop symptoms of oesophageal diseases.<sup>5</sup>

Achalasia is an uncommon oesophageal motility disorder characterized by aperistalsis and impaired lower oesophageal sphincter relaxation resulting in dysphagia, impaired emptying of food into the stomach, and poor quality of life.<sup>6,7</sup> It cuts across ages, races, and sex, with its incidence among paediatric population amounting to 0.18/100,000 per year in the United Kingdom (UK).<sup>8</sup> It is additional morbidity that if not nip in the bud could worsen HIV care.<sup>1</sup>

We report this case of achalasia in a 14-year-old HIV/TB co-infected male adolescent because of its rarity and to sensitize clinicians to the need to consider achalasia when confronted with dysphagia in HIV-infected children. Also to highlight achalasia diagnostic challenge in resource-limited-settings, and share the lessons learned.

## 2. PRESENTATION OF CASE

A 14-year-old boy presented at the Paediatric antiretroviral clinic in our facility with progressive worsening difficulty and painful swallowing noticed initially with solid food and gradually including liquid diet and water, and intermittent vomiting of 4 years duration. There was associated weight loss and recurrent fever. He was diagnosed HIV positive at a private facility and was referred to our facility because of his HIV status. He is the 7<sup>th</sup> child of a mother who is HIV seronegative and a petty trader. Father is deceased.

Examination revealed a stunted and chronically ill-looking boy with a weight of 22.5kg and a height of 139cm, which were 48.3% and 86.3% of the expected for his age respectively. He had generalized lymphadenopathy and whitish patches on the tongue. Other systems were essentially normal. An assessment of oesophageal candidiasis in an HIV-infected adolescent with suspected pulmonary tuberculosis and Achalasia was made.

The problems identified at the initial presentation were: dysphagia, odynophagia, stunted growth, and generalized lymphadenopathy. The following investigations were ordered: chest

X-ray, which revealed features suggestive of pulmonary tuberculosis (see Figure 1), stool gene Xpert that showed the presence of *Mycobacterium tuberculosis*, and a cluster of differentiation (CD) 4 count of 380 cells per microlitre of blood. Barium swallow, upper gastrointestinal (GI) endoscopy, complete blood count, liver function test, serum electrolyte, urea, and creatinine were also ordered but could not be done because the mother was financially constrained. He was commenced on anti-Koch's drugs and oral fluconazole for 6 months and 8 weeks respectively. Two weeks after, he commenced highly active antiretroviral therapy (HAART).

Despite the completion of the fluconazole, dysphagia, and odynophagia persisted and became even worsened; he could no longer eat, drink or take his medications, and his weight had dropped to 15kg with extreme weakness. Achalasia, as a diagnosis, was strongly upheld and Barium swallow and upper GI endoscopy among other investigations were carried out through the support received from the hospital management and a non-governmental organization (NGO). Barium swallows revealed features consistent with achalasia. Upper GI endoscopy also showed features in keeping with achalasia. No varices or oesophagitis or malignancy features were seen.

He had a successfully modified Heller's myotomy procedure done and he was able to eat, drink well, and take his medications without hindrance or vomiting. He was discharged home and has been coming for his regular clinic visits. He gained 11Kg within 14 weeks after his surgery. At his last clinic visit, he weighed 26Kg.

### 3. DISCUSSION

Achalasia was first described by Sir Thomas Willis more than 500years ago (1674)(Reviewer's note: its not 500 years ago!)as a disease that occurs due to the absence

of normal inhibition in the lower part of the oesophagus.<sup>9</sup> It was coined “achalasia” by Sir Arthur Hurst in 1929.<sup>9</sup>

It has often been described as a disease of unknown aetiology in some quarters. However, it has been reported to be associated with some disorders including; Down syndrome, Familial dysautonomia, congenital hypoventilation, and AAA syndrome (Achalasia, Alacrima, and Adrenocorticotrophic hormone deficiency).<sup>9,10</sup> Achalasia patients have been shown to have about 3.6 times more tendency to have autoimmune diseases such as uveitis, systemic lupus erythematosus, and type one diabetes mellitus.<sup>11</sup> Infectious agents including parasites and viruses have been documented to cause or found to be associated with achalasia. *Trypanosoma cruzi* is the only infectious agent whose role in the pathogenesis of achalasia has not been queried.<sup>12</sup> Some studies have also hypothesized that some neurotropic viruses such as *Cytomegalovirus* (CMV), *Varicella-zoster virus* (VZV), *Measles virus*, *Herpes simplex virus* (HSV) and *Bornavirus* played important roles in the aetiology of achalasia by causing some inflammatory response in the myenteric network though not without some conflicting inferences.<sup>7,12</sup>

Few works in the literature have documented the possibility of HIV playing a role in the pathogenesis of achalasia because of its neurotropic characteristics too.<sup>12,13</sup> More so Batman et al<sup>14</sup> had demonstrated the denervation of automatic cells within the jejunum of homosexual men living with HIV. The fundamental mechanism in the development of achalasia in susceptible individuals is believed to be a result of the selective loss of inhibitory neurons in the Auerbach's plexus located between the longitudinal and circular muscles layers of the oesophagus and lower oesophageal sphincter. This loss results in the disequilibrium/ imbalance in the activities of the excitatory and inhibitory neurones with the equation tilting towards the former. Acetylcholine is the excitatory neurotransmitter while the vasoactive intestinal peptides (VIP) and nitric oxide (NO) are the inhibitory ones. The

localized reduction in the amount of VIP and NO released with unopposed acetylcholine activities results in the inability of the lower oesophageal sphincter to relax efficiently.<sup>9,15</sup>

Interestingly, the progressive dysphagia to solid and liquid, intermittent vomiting, and the progressive weight loss coupled with the oral thrust, raised the suspicion of HIV infection and its eventual diagnosis in this case. The rarity of achalasia in children and the inability to adequately investigate the patient as a result of financial constraints prevented the diagnosis of achalasia to be made early. The initial consideration was oesophageal candidiasis as the cause of dysphagia, with achalasia as a differential diagnosis in the context of HIV care. This is not unusual as achalasia in children is often misdiagnosed probably because of its rarity and the similarity of its symptoms with other disease entities. Many of these children would have been treated for one or more of these disease entities before the diagnosis of achalasia would be made, just as it played out in this case.<sup>16</sup>

The persistence of the presenting symptoms despite the complete treatment of oesophageal candidiasis strengthened the suspicion of achalasia. Achalasia is diagnosed using a barium swallow study and may be confirmed by oesophageal manometry.<sup>10</sup> We deployed the use of barium swallow to make the diagnosis in this case, and it showed the typical “bird’s beak-like” appearance which was due to tapering of the distal oesophagus (see Figure 2). Oesophageal manometry was not done because of the paucity of funds. Diagnostic findings often demonstrated with this investigation include absent or reduce peristalsis, non-relaxing lower oesophageal sphincter, and a raised resting lower oesophageal pressure.<sup>1,9</sup> Upper GI endoscopy is usually done to demonstrate the presence or absence of associated morbidities such as oesophagitis and oesophageal carcinoma. The incidence of oesophageal cancer is significantly increased in patients with achalasia.<sup>17</sup>

Treatment modalities for the management could be grouped into two: (i) medical and (ii) surgical. The medical management options include the use of calcium channel- blockers

such as Nifedipine which has been used among adults. It inhibits the movement of calcium into the smooth muscles ultimately resulting in smooth muscle relaxation. This has not been readily deployed in paediatric management.<sup>9,10</sup> Use of botulinum toxin has also been documented. It relieves the symptoms temporarily for about 4 months and it has to be repeated multiple times for sustenance though not without side effects.<sup>9,10</sup>

Surgery remains the definitive approach to care, and it includes Heller's myotomy with or without fundoplication. One of the complications of this procedure is the risk of recurrence of dysphagia hence routine follow-up is needed.<sup>9,10</sup> Pneumatic dilation is another surgical approach that has been utilized in adults and children. It is less costly and recovery time is quick however it can be complicated by oesophageal perforation, pneumonia, and gastroesophageal reflux disease.<sup>9,10</sup> Per oral endoscopic myotomy (POEM) is a newer surgical method that has been found to be effective in both adults and children. Its use in paediatric management is still not well known.<sup>9,10</sup>

#### **4. CONCLUSION**

Effective and successful care for HIV patients and the related problems or challenges in the resources-limited setting need concerted efforts of government, non-governmental organizations, and well-to-do individuals in society. Clinicians need a high index of suspicion for achalasia when attending to HIV-infected children presenting with dysphagia. The failure or delay in diagnosis of achalasia could negatively impact HIV-infected patients' nutrition causing malnutrition among other complications which may lead to the rapid progression of HIV infection to acquired immunodeficiency syndrome (AIDS). It is therefore pertinent that all hands must be on deck to eliminate or reduce further morbidity and mortality among people living with HIV.

## CONSENT

All authors declare that written informed consent was obtained from the mother of the patient for the publication of this case. A copy of the written consent is available for review by the Editorial office/Chief Editor/Editorial Board members of this journal.

## ETHICAL APPROVAL

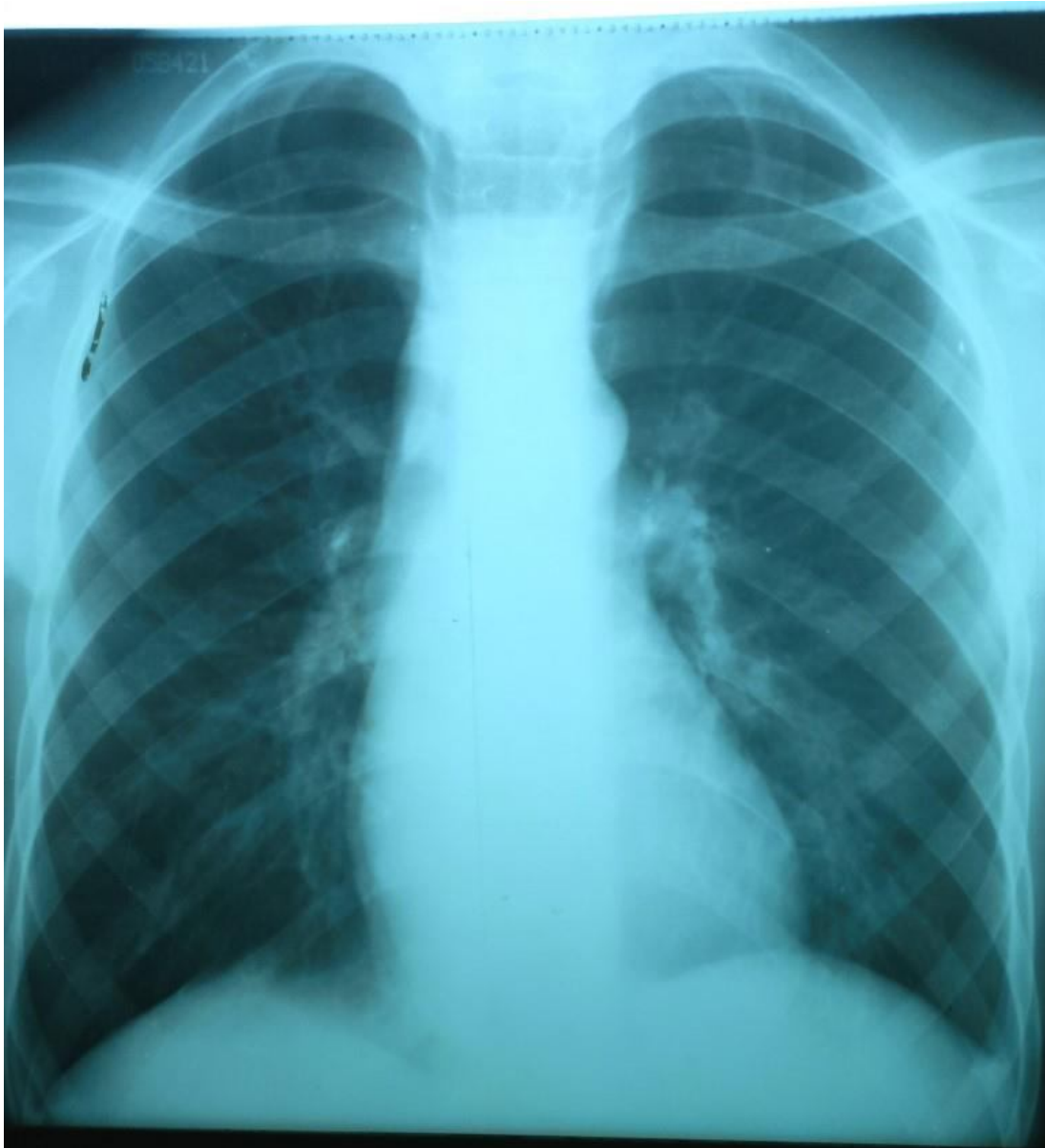
Ethical approval is not applicable.

## REFERENCES

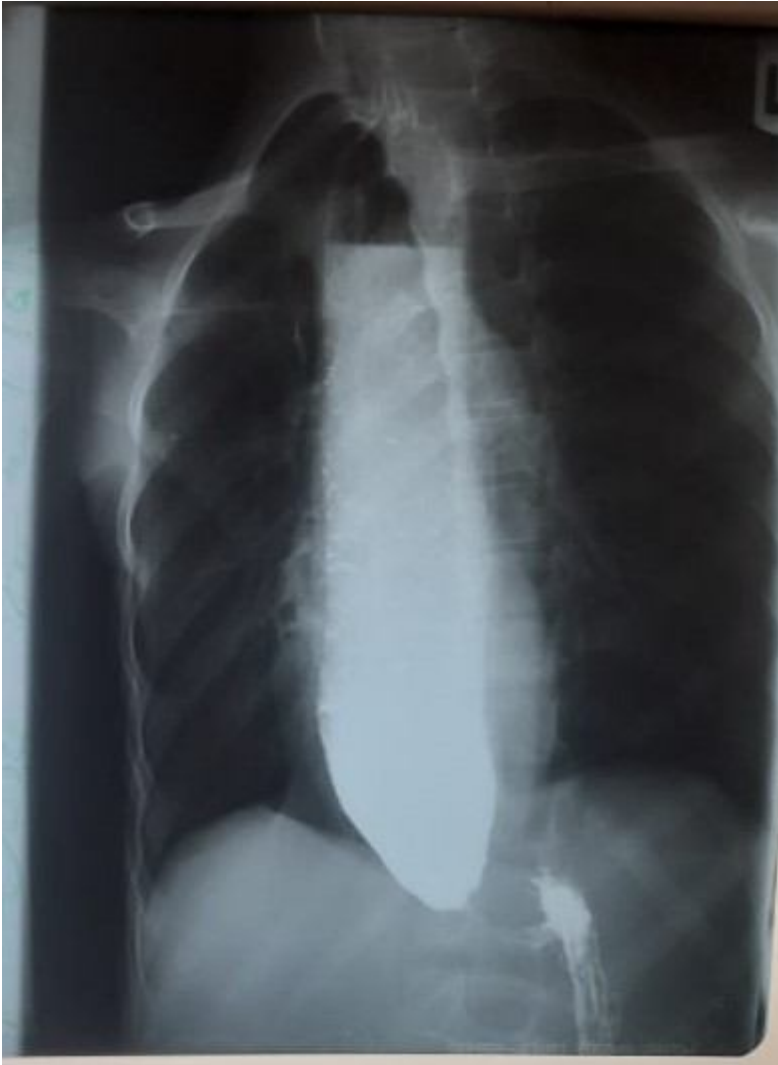1. Bradford A. Esophagus: Facts, functions and diseases. Live Science. 2016; 3:5. Accessed on 19 August 2022. Available at <https://www.livescience.com/52045-esophagus.html>.
2. Varsky CG, Yahni VD, Freire MC, Patriozio E, Balbo V. Esophageal pathology in patients with AIDS virus: etiology and diagnosis. Acta Gastroenterol Latinoam. 1991; 21:67-83.
3. Roufman JP. Odynophagia/dysphagia in AIDS. Gastroenterol Clin Med North Am 1988. 17:599-614.
4. Bonacini M, Laine LA. Esophageal diseases in patients with AIDS: diagnosis and treatment. Gastrointestinal endoscopy Clin North Am. 1998; 8:811-823.
5. Laine LA. Esophageal diseases in Human Immunodeficiency virus infection. Arch Inter Med. 1994; 154: 1577-1582.

6. Farrokhi F, Vaezi MF. Idiopathic (primary) achalasia. *Orphanet J Rare Dis.* 2007; 2:38.
7. Moradi A, Fazlollahi N, Eshraghi A, Gholipour M, Khoshnia M, Javid N. Is there any evidence for a viral cause of achalasia? *Middle East J Dig Dis.*2018;10:169-173.
8. Marlais M, Fishman JR, Fell JME, Haddad MJ, Rawat DJ. UK incidence of achalasia: an 11-year national epidemiological study. *Arch Dis Child.* 2010; 96:192-194.
9. Patel DA, Lappas BM, Vaezi MF. An overview of achalasia and its subtypes. *Gastroenterol Hepatol.*2017;13:411-421.
10. Khan N, Liebenbery C, Suleiman F. Achalasia cardia in children: a report of two cases. *S Afr J CH.* 2015; 9:65-66.
11. Booy JD, Takara J, Tomlison G, Urbach DR. The prevalence of autoimmune diseases in patients with esophageal achalasia. *Dis Esophagus.* 2012; 25:209-213. doi: 10.1111/j.1442-2050.2011.01249.x
12. Barrow PH, Mahomed A, Karlsson KA. HIV and achalasia. *AIDS.*2005;19:1709-1710.
13. Elkhoully MA, Attar BM, Mutneja H, Demetria MV. Achalasia in a patient newly diagnosed with HIV. *Am J Gastroenterol* 2018; 3111: S1673.
14. Batman PA, Miller AR, Sedwick PM, Griffin GE. Autonomic denervation in Jejunal mucosa of homosexual men infected with HIV. *AIDS.* 1991; 5:1247-1252.
15. Mearin F, Mourelle M, Guarner F. Patients with achalasia lack nitric oxide synthase in the gastroesophageal junction. *Eur J Clin Invest.* 1993; 23: 724-728.
16. Lee CW, Kay DW, Chen MR, Islam S. Outcomes of treatment of childhood achalasia. *J Pediatr Surg.* 2010; 45:1173-1177.
17. National Organization for Rare Diseases (NORD). Achalasia. NORD. 2017; 7:2  
Accessed on 19 August 2022. .Available:<https://rare diseases.org/rare-diseases/achalasia/>.

APPENDIX



*Figure1: Chest X-ray showing reticular shadows*



***Figure 2: Barium swallows showing the tapering of the distal oesophagus - “a typical bird’s beak-like appearance”***