

## DENTIST 'AN ARSENAL' IN THE JOURNEY OF 'TOOTH IN THE EYE'-THE OSTEO ODONTO KERATO PROSTHESIS [OOKP]

Abstract:

**Background:** Global blindness is mainly due to Cataract, after this Corneal disease is the major cause. For end stage corneal disease, the only successful treatment is by providing Osteo-Odonto-Kerato-Prosthesis (OOKP). The dental surgeon will play a vital role in this surgeon. After extracting a canine tooth from the patient, the dental surgeon places the acrylic lamina in the centre of the dentine (Dental Lamina) which acts like an ocular lens, later the Ophthalmic surgeon will place the same in the patient's blind eye to get vision.

**Review results:** After electronic search was done on the role of dental surgeon and OOKP , through PubMed, Scopus, Web of Science, Wiley Online, Science Direct Ebscohost and Google Scholar for articles published from 1960 to July 2022, using the Key words, Osteo-Odonto-KeratoProsthesis (OOKP), Modified Osteo-Odonto-Kerato Prosthesis (MOOKP), Osteo-Odonto-Alveolar Lamina, Corneal Disease Tooth-in-Eye, and Poly Methyl Meth Acrylate (PMMA) Cylinder, finally 14 articles were found to be relevant for the present research topic

**Conclusion:** Studies shows OOKP is providing vision and the success rate more than 85%. Not a single study mentioned the importance of a dental surgeon in OOKP surgery.

**Clinical Significance:** Though the dental curriculum not mentioned directly about the role of a dentist in in the OOKP surgery, but all the dental surgeons should have knowledge on OOOKP Surgery.

**Key Words:** Osteo-Odonto-KeratoProsthesis (OOKP), Modified Osteo-Odonto-Kerato Prosthesis, Osteo-Odonto-Alveolar Lamina, Corneal Disease, Tooth-in-Eye, Poly Methyl Methacrylate (PMMA) Cylinder.

BODY OF THE MANUSCRIPT

### INTRODUCTION:

Corneal diseases are among the major causes of blindness globally, secondary to cataract. If a person is born blind, his life becomes miserable, and if somebody loses their vision after some time in their life due to some reason like inflammatory corneal diseases, then none can imagine their plight for the rest of life. In such situations, the only hope is the Osteo-Odonto KeratoProsthesis (OOKP). In this procedure a portion of patient's tooth along with bone is used to support an optical cylinder to restore vision. The Osteo-Odonto-KeratoProsthesis (OOKP) is a corneal prosthesis with a biological haptic that was designed by Benedetto Strampelli,<sup>1</sup> and later, modified (MOOKP) by Prof.Giancarlo Falcinelli<sup>2</sup> as a last resort which was successful. Thus, it is a process of utmost importance which aids in providing the patient with eyesight.

Many studies suggest that the triumph of OOKP's procedure depends upon the identification of the desired tooth. The role of dentist is set in motion in the beginning of the procedure itself contributing to the treatment outcome.<sup>1-4</sup> Dental Surgeon performs the dental examination including examination of hard and soft tissues of the oral cavity. A single root tooth should be selected, ideally a canine.<sup>5,6</sup> Imaging techniques, such as orthopantomography, X-ray, and cone-beam CT help to evaluate and select the appropriate tooth.<sup>2,4,6</sup> Only one eye should be rehabilitated with OOKP, if at all any failure occurs then the spare eye can be used again for the same procedure. Very less is known in dentistry about the role of

dentist in the field of ophthalmology. <sup>7</sup> OOKP is an intricate process in which, it is believed that an ophthalmologist plays a major role and gets the entire credit for the outcome. Appropriate selection and obtaining tooth and buccal mucosa to pass it on to the ophthalmologist is a dentist's job, else the operation could fail. Despite playing such an imperative role, dentists are given trivial credit. A dentist, who plays a vital part is rewarded with little or no credits for his role. However, it is a disconsolate fact that an infinitesimal number of dentists in the world of dentistry are aware of their importance in the OOKP procedure. Hence this review research is aimed to highlight a Dentist's role in the OOKP treatment.

**Methodology:** An electronic search was done for biomedical literature on OOKP and role of Dental surgeon, through Medline via PubMed, Scopus, Web of Science, Wiley Online, Science Direct Ebscohost and Google Scholar for articles published from 1960 to July 2022, using the Key words, Osteo-Odonto-KeratoProsthesis (OOKP), Modified Osteo-Odonto-Kerato Prosthesis (MOOKP), Osteo-Odonto-Alveolar Lamina, Tooth-in-Eye, Corneal Disease and Poly Methyl Meth Acrylate (PMMA) Cylinder.

**Results:**

A total of 64 articles were found. Out of these 50 articles were not related to present search and excluded from the study. Only full text articles and articles published in the English language only were included in the study. Abstracts and website materials were excluded from the study. Finally, 14 articles were found to be relevant for the present search. (PRISMA- Flow Chart). No study results highlighted the role of a dentist, but mentioned the importance of proper oral examination, selection of the suitable tooth and preparation of the dental lamina.

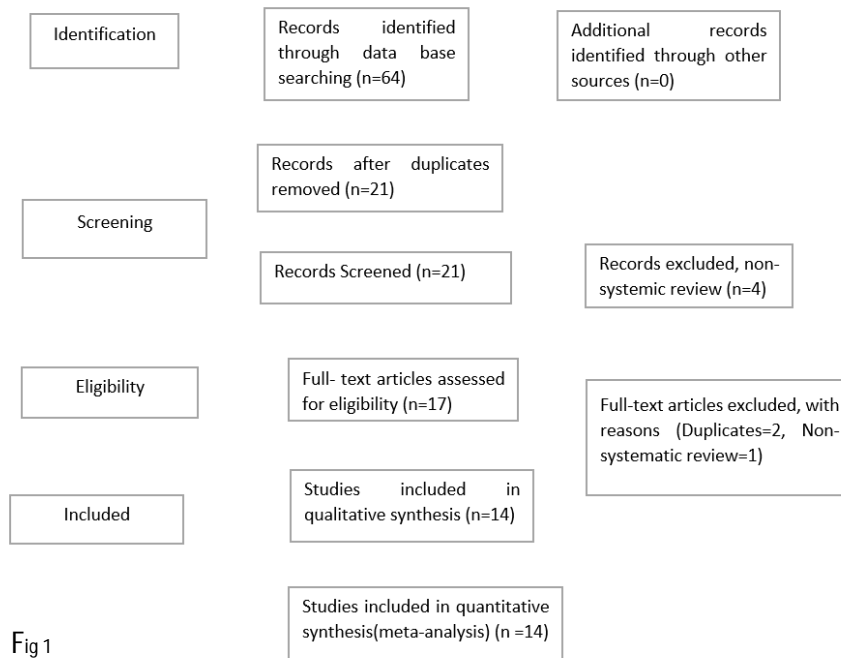


Fig 1

SMA Flow Chart- Describing process of articles being reviewed and selected.

The outcomes and characteristics of the included articles were summarized. [Table-1]

Table-1: Outcomes of included studies:

<p>1. Ricci R et al., in 1992<sup>15</sup></p>	<p>investigate the preservation status of the osteodental laminae after prolonged periods in three prostheses.</p>	<p>They found that in case 1: due to usage of small incisor tooth, the visual acuity was 1/10 but the alveolar-dental ligament was intact after 20 years, In the case 2: Due to ocular inflammation the dental lamina was removed. In the case 3: Due to acute inflammation of the periprosthetic tissues the OOKP was removed.</p>
<p>2. Giancarlo Falcinelli et al., in 2005<sup>4</sup></p>	<p>Assessed the long-term outcomes after 18 years from 181 cases of corneal blindness treated with OOKP</p>	<p>They found that the intact OOKP was seen in 85% patients and only 6.07% cases anatomical complications observed. They concluded that: Modified OOKP surgery for corneal blindness of different etiologies may provide, in the long term, anatomically stable corneal prosthesis as well as an effective, rehabilitating recovery in visual acuity.</p>
<p>3. Liu C et al., in 2005<sup>5</sup></p>	<p>Reviewed the patient assessment for surgery; stage I and Stage II surgical techniques and complications</p>	<p>They suggested to identify any complications and to address them a lifelong follow-up is necessary.</p>
<p>4. Hille K et al., in 2006<sup>16</sup></p>	<p>Discussed on different Kerato Prostheses from their personal experience on 35 different Kerato Prosthesis used by them.</p>	<p>They experienced no difference among different prostheses. They concluded that the prosthesis which utilized the root portion of the patient tooth shown good results.</p>
<p>5. Tay ABG et al., in 2007<sup>6</sup></p>	<p>They did a retrospective study in Singapore, to describe the oral procedures used in Osteo-Odonto-Kerato Prosthesis (OOKP) surgery in 21 patients</p>	<p>They found that 12 patients were suitable for OOKP surgery, 8 were at risk of complication or failure and 1 had no usable teeth. Fourteen patients have undergone unilateral OOKP Stage 1 surgery successfully. They explained different complications of both hard and soft tissues of oral cavity.</p>
<p>6. Fukuda M et al., in 2008<sup>18</sup></p>	<p>They revealed their experiences and success of the OOKP in 4 patients with their modified technique of artificial buccal mucosa for end stage SJS and OCP diseases.</p>	<p>They found that in case 1- the visual acuity was 0.5 and worked for 4 years and 8 months, in case 2 : 0.04 and 3 years 10 months, case 3: acuity was 0.1 and 3 years 2 months where as in case 4: 0.04 and 1 year 3 months. They concluded that that OOKP is useful for visual in severe ocular surface diseases.</p>
<p>7. Tan DTH in 2008<sup>20</sup></p>	<p>Did a prospective noncomparative case series evaluated the efficacy of</p>	<p>They observed in 19.1 month follow up period in 15 cases some complications such as fracture of tooth, oroantral fistula,</p>

	safety in OOKP surgeries for end stage corneal diseases in 15 cases and establishing multidisciplinary surgical programme in Asia	haemorrhage but the anatomical stability was maintained in all the cases. They concluded that, establishment of OOKP program reveals that OOKP surgery has the potential to restore good vision to the most severe cases of corneal blindness in an Asian setting.
8.Iyer G et al., in 2010	Studied the results of modified OOKP surgery in the bilateral end- stage ocular diseases in 50 cases in 15.38 months of follow up period in the Indian sub-continent.	They found that 96% of anatomic success and functional acuity in 66%. Along with they experienced complications range from 2-8%. They concluded that in Indian sub-continent set up the OOKP shows very useful results.
9.Narayanan V et al., in 2012 <sup>17</sup>	Did a retrospective analysis of 26 patient records who went OOKP surgery between 2007 and 2011 and explained the complications oral and oral and maxillofacial aspects.	They shared about the available teeth such as max. canines in 22 patients: mandibular canines in 02 patients and maxi. first premolars in 02 patients. They also found oroantral fistula in 04 cases in 12 patients roots of adjacent teeth were exposed and 19 patients visually got rehabilitated.
10.Tan A in 2012 <sup>19</sup>	They did a retrospective study on 181 cases from 1950-2011 on indications, visual acuity and complications.	They found that the most indicated cases were suffering with Steven Jonson syndrome and Chemical injuries. They revealed that 87.8% was the anatomical survival rate in 5 years and 81% in 20years, whereas visual acuity was 6/18 in 52%. The most long-term complication they observed was glaucoma. They concluded that for end stage corneal disease situation OOKP is very reliable option
11.Kaur J in 2018 <sup>7</sup>	Did a review on the role of periodontium in the field of ophthalmology and discussed about the indications, contra indications of OOKP surgery, its techniques, and the role of oral structures in the success of OOKP.	Concluded that though the results are promising simultaneously OOKP becoming burden on the patient as well on relatives. With the usage of tooth as an eye implant may lead to inspire the future inter professionals approaches to ophthalmic practice to provide the best care of the patients.
12.Ortiz-Morales G et al., in 2022. <sup>3</sup>	Did an analytical review from world literature on modified OOKP till 2022, on the reliability and prognosis of long term OOKP.	They found that the most indication for OOKP is autoimmune disease followed by chemical injury. The post operative complications involved more with dental lamina followed by oral mucosa then secondary glaucoma.
13.Iannetti L, in 2023 <sup>21</sup>	From 30 years follow up period they did a	They found that the most common reason for blindness is chemical injuries (71%),

	retrospective study in 59 cases of OOKP surgery using the original Strampelli technique	with the maximum complication of Glaucoma (31%). They concluded that original OOKP still standing as the first choice
14.Mohamed B. Goweida in 2023	Evaluated the preliminary results of OOKP in 6 eyes with end-stage cicatrizing conjunctivitis, in Egypt.	He found only in one eye the visual improvement was not seen. He concluded that for end stage corneal blindness, OOKP provides a promising result.

The OOKP treatment is a two-stage procedure. The Dentist's role is crucial principally in the stage I procedure which includes preparation of Dental Lamina/OOKP Lamina/Keratoprosthesis Lamina/Biointegrated Prosthetic Unit and selection and collection of suitable buccal mucous membrane. For the preparation of dental lamina, single rooted firm tooth is required. The dental surgeon plays a crucial role in the selection of appropriate tooth, extraction of that tooth along with alveolar bone, identifying the suitable buccal mucous membrane as well as in the preparation of the OOKP lamina/keratoprosthesis/dental lamina/ biointegrated prosthetic unite. After preparation of the lamina by the dental surgeon, the ophthalmic surgeon places the lamina beneath the orbicularis oculi muscle of the contralateral eye for the formation of fibrovascular covering over the lamina.

Most suitable tooth is the maxillary canine due to its longest and largest root with greatest quality of alveolar bone. Preference of the upper or lower canine depends on proximity of maxillary sinus and mental foramen respectively. Other single-rooted teeth can be used in the absence of a canine. In case of no suitable tooth available or if patient is completely edentulous then allograft is considered from the donors includes either kids or siblings.

Step by step OOKP surgical procedure:

OOKP surgery is usually carried out in only one eye. The other eye, if existing, should be kept as a 'spare' eye.<sup>8</sup>

Stage 1

After careful examination the suitable canine tooth should be extracted along with some portion of the surrounding healthy alveolar bone. (Fig 2) Then using the crown portion as handle and slit the root portion vertically, carefully removing the pulp portion of the root, the dentine portion should be trimmed to achieve desired thickness, with carefully preserving the periosteum adjacent to the root. (Fig 3 & 3a)

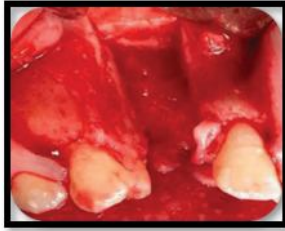


Figure 2: Extraction of Canine tooth along with adjacent alveolar bone.

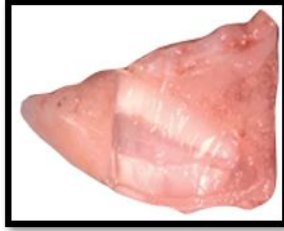

Figure 3. Sectioning of Canine tooth root

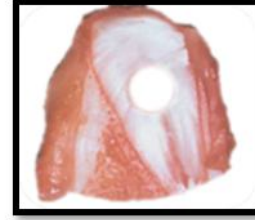


Figure 3a: Prepared hole in the Centre of root to accommodate Optical Cylinder

[ Source: Picture 2: Tay A.B.G et al. Osteo-odonto-keratoprosthesis surgery: a combined ocular–oral procedure for ocular blindness. Int J Oral Maxillofac Surgery 2007]; [Pictures 3, 3a: Falcinelli Giancarlo et al. Modified osteo-odonto-keratoprosthesis for treatment of corneal blindness: long-term anatomical and functional outcomes in 181 cases. Arch Ophthalmol 2005]

To accommodate the Poly Methyl Meth Acrylate (PMMA) optical cylinder (Fig 4), a hole should be drilled carefully in the center of the dentine. Later the optical cylinder will be fitted into the hole and stabilized with bone cement. (Fig 5).



Figure 4. PMMA Optical Cylinder

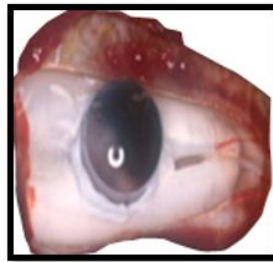


Figure 5. Completed Osteo-Dental Lamina

[ Source: Picture 4&5: Tay A.B.G et al. . Osteo-odonto-keratoprosthesis surgery: a combined ocular–oral procedure for ocular blindness. Int J Oral Maxillofac Surgery 2007]

This entire unit is called Osteo-Odonto lamina or Dental lamina or OOKP lamina. This is then harvested in the ‘sub-muscular pocket (Orbito zygomatic pocket) which is created under Orbicularis Oculi muscle in the lower eyelid of the contralateral eye for approximately 2-4 months to get soft tissue cover around the lamina. <sup>9,10</sup>

Stage I surgery also includes the selection and preparation of a buccal mucosal graft. dental surgeon selects the appropriate site of buccal mucosa (Fig 6) excises the membrane. The fat should be cleaned carefully from it and handed over to the ophthalmologist. He will place the same in the patient eye covering the ocular surface stabilizing it with sutures. (Fig7) The grafted buccal mucosa is left for 2-3

months, it will be vascularized, and later the same will provide blood supply to the alveolar bone of Osteo-Odonto lamina.<sup>11</sup>

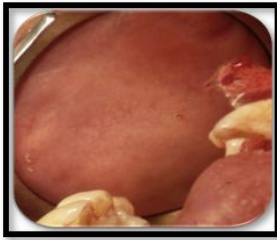


Figure 6. Selection of Buccal Mucosa

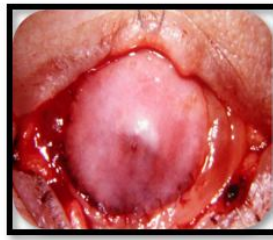

Figure 7. Buccal Mucosa covering the Ocular Surface

[Source: Picture 6 & 7 Narayanan V et al. Osteo-odonto-keratoprosthesis e A maxillofacial perspective. J Craniomaxillofac Surg 2012 ]

The OOKP optical cylinder comes in two different diameter sizes (3.5 and 4.0 mm) and a standard length of 8.75 mm; a wider diameter offers the benefit of a wider Osteo-Odonto lamina. The ideal lamina should be of a size measuring 12 mm × 6 mm × 3 mm as per Tay ABG and his colleagues.<sup>6</sup>

Stage 2:

Once the surgery is complete, should wait for 2-4 months to allow the growth of soft tissue over the dental lamina and vascularity of the mucous membrane. Retrieval from the submuscular pocket created below the contra lateral eye the dental lamina is the first step in the stage of surgery. (Fig 8) The alveolar bone surface is cleaned properly to remove the excess tissue. The dentine surface should be free of soft tissue. The buccal mucosal graft is reflected to allow access to the cornea. Then the center of the cornea is marked, and a small hole is created, which can accommodate the size of the posterior part of the optical cylinder. (Fig 9) Through the central hole the optical lamina is inserted, and the lamina is sutured to the sclera and cornea. The intraocular pressure maintenance is very important. To maintain the intra ocular pressure, the eye should be inflated with filtered air. Later the protrusive portion of the anterior part of the optical cylinder is exposed by cutting a hole in the mucosal flap. (Fig 10) The intra ocular pressure should be maintained for at least a week. Patients regain their vision immediately and a clear view will get in a short period.<sup>4,7,9,10</sup> Cosmetic point of view, after 1month post-surgical period, a prosthesis can be given to cover the ocular surface.<sup>4</sup> (Fig 11)

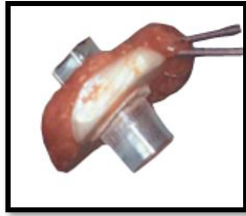


Figure 8. Retrieved Dental Lamina from the submuscular pocket.

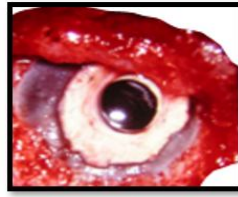


Figure 9. Placement of optical Cylinder in the center of Cornea

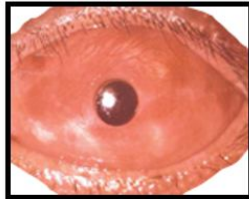


Figure 10. Final placement of Dental Lamina in the Eye.

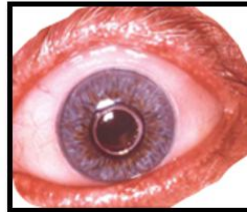

Figure 11. Prosthesis covering the ocular surface.

[Source: Falcinelli Giancarlo et al. Modified osteo-odonto-keratoprosthesis for treatment of corneal blindness: long-term anatomical and functional outcomes in 181 cases. Arch Ophthalmol 2005]

At the follow-up visit, a slit lamp examination should be carried out to assess the vascularization of the mucous membrane. An ultrasound-B scan is also useful to check for any retinal detachment. The usage of Snellen's chart is mandatory to assess vision.<sup>12</sup>

### Discussion:

In the 21<sup>st</sup> century the OOKP procedures witnessed a big number compared to the previous century performed in many countries including India. The intraocular lens and the OOKP design have some similarities which includes a haptic and an optic. The central part of OOKP consisting of optic portion which will be culpable for viewing and the PMMA cylinder establishes as an optical clear window.

The maxillary canine tooth is the most suitable one to prepare dental lamina, because it has a single root with ideal length, shape, strength, and a good amount of quality alveolar bone which fulfils all the norms for OOKP surgery.<sup>13</sup> Whether to select maxillary canine or mandibular canine, the dental surgeon will decide considering the distance of maxillary antrum to the upper canine tooth as well as the mental foramen for the lower canine. Though the harvesting of the lower canine is easy, it has some disadvantages as the thin buccal plate and is difficult to preserve the lingual mucoperiosteum. Whereas maxillary canine shows thick palatal bone and occasionally may peril the misdemeanor of the maxillary antrum. Another advantage of maxillary canine is the harvesting is uncomplicated.<sup>14</sup> If canine teeth are not available, then the second preference can be given to other single root teeth such as premolars. The third option is if the patient is edentulous or single rooted teeth are not available then, the suitable canine tooth may be selected

from the donor of the patient's siblings or patient's children. But there is a problem with this, the patient should be lifelong on immunosuppressive drugs .<sup>14</sup>

As per Holzle F et al.,<sup>15</sup> dentin is responsible for the long-term survival of OOKP. According to them, the dentin shows a sluggish metabolic exchange rate, very hard material and avascular. Hence dentine restrains the creation of retroprosthetic membrane as well as furnishing bolsters to the optical cylinder. The buccal mucosa membrane is a physiological covering, having a proliferating capability, resistant to high bacterial load and providing blood supply to the bony part of the lamina. <sup>9</sup> According to Holzle et al., <sup>15</sup> and Narayanan V et al., <sup>9</sup> the buccal mucosa has stem cells which aid to cater for the limiting of infection due to an easy approach with fewer issues in the donor site. The lamina propria of the buccal mucosa is highly vascularised and thick, elastic in nature with non-keratinized property which provides an exemplary environment for reconstruction surgery. Hence the buccal mucosa membrane is the favored graft for OOKP surgery. As per the experience of Falcinelli G and his colleagues <sup>4</sup> the buccal mucosa will be revascularized by the time of Stage 2 surgery and will subsequently provide the blood supply to the bony part of the OOKP lamina.

As per Liu C et al.,<sup>5</sup> the alveolar bone, which is attached to the root portion of the tooth is porous in nature which can aid in the stabilization of supporting structures of the OOKP, and it also shares some credit for the success of OOKP surgery along with the periodontal ligament. The perfect periodontal ligament will prevent excess growth of epithelium between corners of the OOKP and mucosal surface. <sup>6</sup> The patients should not have habits of smoking and betel nut chewing since it may compromise tissue healing. The severe scarring of the oral mucosa may also compromise the successful harvest.<sup>2-6</sup>

The OOKP optical cylinders are commercially available in the market, in two different diameters (3.5 and 4.0 mm) and a standard length of 8.75 mm; a wider diameter offers the benefit of a wider Osteo-Odonto Lamina. The ideal lamina should be measuring 12 mm × 6 mm × 3 mm, <sup>6</sup> which is less than the dimensions of the canine tooth, hence after fixing this cylinder in the dentin there will still be some excess tooth material. If the OOKP lamina is smaller and the optical cylinder is difficult to insert, then two teeth can be used to prepare the suitable lamina. <sup>4</sup>

There is a hand full of research evidence available on the success of Dental lamina. Ricci et al.,<sup>16</sup> drew conclusions from their research study on clinical and histological long-term features of three (03) prostheses, that preservation of the alveolar-dental ligament plays a definitive role in the maintenance of the prosthesis. Another medium-term research follow-up for 5 years period revealed by Hille et al.,<sup>17</sup> shows results that there was 100% retention of OOKP lamina. Indian experience about modified OOKP procedure with a follow up period of 15 months shared by Iyer et al.,<sup>18</sup> on the results of first 50 cases treated claimed that a mesmerizing percentage (96%) success rate of OOKP lamina was observed.

A Major percentage of literature witnesses the success story of OOKP surgery. Many long-standing retrospective studies are accomplishing desirable OOKP results. As per Giancarlo Falcinelli et al., <sup>4</sup> the results from a total of 181 patients, showed by the modified OOKP treatment was highly successful with

85% of stability both functionally as well as anatomically. According to Liu C and his colleagues, after a follow up for 18 years, there was a huge percentage (85%) of success rate reported by OOKP procedure in the corneal blind cases. Herold J and his colleagues<sup>5</sup> expressed 80% of patients achieved improvement of vision from the modified OOKP surgery. Fukuda M et al.,<sup>19</sup> announced that in Japan the modified OOKP surgery journey is going in a successful path with 75% of visual acuity and 85% of OOKP lamina stability for a period of 18 years. The conclusions drawn from their retrospective study, Tay ABG et al.,<sup>6</sup> claimed that the autologous buccal mucosal graft stabilizes the artificial cornea and same was supported by Rao Lakshmana B et al.,<sup>10</sup> in their review research.

On the surgical outcomes and complications of OOKP, Tan A and his co-workers revealed the outstanding abiding results of visual outcomes shown by the OOKP in the treatment of severe, end-stage cicatricial, or ocular surface inflammatory diseases.<sup>20</sup> These results were on concurrence with the results of Tan DT et al.,<sup>21</sup> in severe cases of corneal blindness, the most successful treatment by which the patient regains the vision by means of OOKP procedure only.

The latest published global information has been made available in an analytical review conducted on 37 published clinical case reports & case series and a total of 958 patients by Ortiz-Morales G et al.,<sup>3</sup> which has revealed that very impressive and lion head share (more than 90%) success rate of OOKP procedures. Iannetti L et al.,<sup>22</sup> in 2022 from their 30-year retrospective study on 82 eyes, has drawn the conclusions that there is a major percentage (94%) of anatomical survival rate resulted from Strampelli original technique. OOKP has shown excellent long-term anatomic and functional success rates. The largest case series included 181 patients and showed a 93.9% anatomic success rate.<sup>4</sup> After 18 years of follow-up, there was an 85% probability of anatomic success of 95% .

#### **Conclusion:**

The selection of a tooth and its extraction along with periodontal ligament with surrounding alveolar bone, sectioning of the tooth, removal of pulp from the root, identification of good buccal mucosa and removal of the graft can be performed in a better way by the dental surgeon than anybody else. Every dentist must have knowledge about the OOKP procedure. Because there's a saying in Sanskrit that goes – “Sarvendriyanam Nayanam Pradhanam” which means out of all the sense organs, eyes will occupy the paramount position. Dentists play a key role in OOKP team to provide eyesight to the patient.

**Clinical Significance:** Dental surgeon will be the better judge for selection of an appropriate tooth and buccal mucosa and can perform proper surgical removal of the tooth as well as the buccal mucosa. Hence every dentist should have knowledge on OOKP procedure about the role of a dental surgeon.

#### **References:**

1. Strampelli B. Osteo-odontokeratoprosthesis. *Ann Ottalmol Clin Ocul* 1963;89:1039–1044.

2. Hille K, Grabner G, Liu C, Colliardo P, Falcinelli G, Taloni M, Falcinelli G. Standards for modified osteo-odonto-keratoprosthesis (OOKP) surgery according to Strampelli and Falcinelli: the Rome-Vienna Protocol. *Cornea* 2005;24:895–9082.
3. Ortiz-Morales G, Loya-Garcia D, Colorado-Zavala MF, Gomez-Elizondo DE, Soifer M, Srinivasan B et al. The evolution of the modified osteo-odonto-keratoprosthesis, its reliability, and long-term visual rehabilitation prognosis: An analytical review. *Ocul Surf* 2022 ; 24:129-144.
4. Falcinelli G, Falsini B, Taloni M, Colliardo P, Falcinelli G (2005) Modified osteo-odonto-keratoprosthesis for treatment of corneal blindness: long-term anatomical and functional outcomes in 181 cases. *Arch Ophthalmol* 123:1319–1329.
5. Liu C, Paul B, Tandon R, et al . The Osteo-Odonto-Keratoprosthesis (OOKP). *Seminars in Ophthalmology* 2005; 20:113–128.
6. Tay ABG, Tan DTH, Lye KW, Theng J, Parthasarathy A, Por Y-M (2007) Osteo-odonto-keratoprosthesis surgery: a combined ocular–oral procedure for ocular blindness. *Int J Oral Maxillofac Surgery* 36:807–813.
7. Kaur J. Osteo-odonto keratoprosthesis: Innovative dental and ophthalmic blending. *J Indian Prosthodont Soc* 2018; 18:89-95.
8. Goma A, Comyn O, Liu C. Keratoprosthesis in clinical practice-a review. *Clin Exp Ophthalmol* 2010 ;38(2):211-24.
9. Narayanan V, Nirvikalpa N, Rao S K. Osteo-odonto-keratoprosthesis e A maxillofacial perspective. *J Craniomaxillofac Surg* 2012;40 (8): e426-31.
10. Rao Lakshmana B, Rajashekar Sangur, Mahajan Tanu, Mishra Prabhat, and Singhal Parul. A Tooth for an Eye: The Osteo-Odonto-Keratoprosthesis (OOKP) - A Review. *Research and Reviews: J Dent Sci (RRJDS)* 2013; 1(2):13-7
11. Goweida MB. Osteo-Odonto keratoprosthesis in Egypt: a case series. *Delta J Ophthalmol* 2020; 159-166.
12. Casey TA. Osteo-odonto-keratoprosthesis. *Proc R Soc Med* 1966;59(6):530-31.
13. Shetty L, Gupta A, Shah N, Shah U. A new vision through combined osteo-odonto-keratoplasty: A review. *Med J DY Patil Univ* 2014; 7:272-77.

14. Hölzle F, Mitchell DA, Rau A, Palisaar J, Loeffelbein DJ, Noldus J, et al: Assessment of the perfusion and morbidity of the buccal mucosal donor site for grafting of urethral strictures. *J Craniomaxillofacial Surg* 2012; 40: 47-50.
15. Ricci R, Pecorella I, Ciardi A, Della Rocca C, Di Tondo U, Marchi V, et al. Strampelli's osteo-odonto-keratoprosthesis. Clinical and histological long-term features of three prostheses. *Br J Oral Maxillofac Surg* 1992;76:232-4.
16. Hille K, Hille A, Ruprecht KW. Medium term results in keratoprotheses with biocompatible and biological haptic. *Graefes Arch Clin Ophthalmol* 2006;244 (6) : 696-704.
17. Iyer G, Pillai VS, Srinivasan B, Falcinelli G, Padmanabhan P, Guruswami S, et al. Modified osteo-odonto keratoprosthesis – The Indian experience – Results of the first 50 cases. *Cornea* 2010; 29:771-6.
18. Fukuda M, Hamada S, Liu C, Shimomura Y. Osteo-odonto-keratoprosthesis in Japan. *Cornea* 2008 ;27 Suppl 1:56-61.
19. Tan A, Tan DT, Tan XW, Mehta JS. Osteo-odonto keratoprosthesis: Systematic review of surgical outcomes and complication rates. *Ocul Surf* 2012; 10:15-25.
20. Tan DT, Tan AB, Theng JT, Lye KW, Parthasarathy A, Por YM et al. Keratoprosthesis surgery for end-stage corneal blindness in Asian eyes. *Ophthalmology* 2008;115(3):503-10.
21. Iannetti L, Liberali M, Armentano M, Alisi L, Visioli G, Mastromarino D, et al. "Osteo-odonto-keratoprosthesis according to Strampelli original technique: A retrospective study with up to 30 years of follow-up". *Am J Ophthalmol* 2022; 242:56-68.