

OBSERVED ORAL CANDIDIASIS DURING HUMAN IMMUNODEFICIENCY VIRUS (HIV) INFECTION: A Review.

ABSTRACT

Oral cavity is one of the manifestations that results from HIV infection. Some of these lesions are suggestive whilst others are specific. However, the oral candidiasis that was observed during HIV infection is specific in terms of its severity and resistance to the usual treatment. Therefore, it is important for all practitioners to know it well in order to be able to make the diagnosis and propose an adequate treatment. During HIV infection, 95% of HIV-positive people have one or more lesions in the oral cavity during their illness. Moreover, oral candidiasis is classified among these lesions. We will describe the different types of candidiasis and their treatment.

Key words: Candidiasis, HIV, AIDS, Infection

1. INTRODUCTION

AIDS or Acquired Immune Deficiency Syndrome is the most progressive form of Human Immunodeficiency Virus (HIV) infection. It is a disease that was first discovered in the United States in 1981 [1], and whose epidemic has since taken on global proportions. Most manifestations of HIV infection result in lesions in the oral cavity. Patients infected with HIV, present one or more clinical manifestations in the oral cavity. Some of these lesions are suggestive of this infection, whilst others are pathognomonic [2, 3, and 4].

Oral candidiasis is the lesion that is most frequently encountered in HIV-infected individuals [5, 6, and 7]. Schiødt and Pindborg (1987) observed that 35% of HIV-positive patients and 75% of those with proven AIDS have signs of oral candidiasis [8]. Those different clinical aspects and treatment protocols are further presented in this review.

2. CLASSIFICATION OF ORAL CANDIDIASIS

The lesions caused by HIV infection may be diffuse, nearly reaching the entire oral mucosa, or limited to circumscribed foci. All eventualities are possible between these two extremes. Oral candidiasis is one of the most common manifestations of HIV infection. Its clinical forms, which could be acute or chronic, are classified into: [6, 7, 8, and 9]

- Erythematous or atrophic candidiasis
- Pseudomembranous candidiasis
- Hyperplastic candidiasis
- The black hairy tongue
- Perleche
- Cheilitis

3. CLINICAL SIGNS OF DIFFERENT FORMS OF ORAL CANDIDIASIS

Despite the overall deficit of cell-mediated immunity, which is one of the major consequences of HIV infection, only a small number of fungi frequently encounter it in HIV patients. Some fungal infections are superficial, cutaneous and/or mucous membranes, and generally benign. Fungal secondary infections can reveal the HIV infection by their unexpected occurrence, their resistance to treatment, or recurrence [6].

Candida albicans is responsible for almost all cases of oral candidiasis [8]. The diagnosis of candidiasis of the oral mucosa should be made after a clinical stage, and an equally essential mycological stage [6].

Erythematous or atrophic Candidiasis (Figure 1): This form is observed in 30% of seropositive patients [8], most often in the form of an erythema located at the level of the palate or the dorsal surface of the tongue, without a whitish film. The tongue appears smooth, glazed, and sometimes dry. The affected areas of the tongue are usually depapillated. This is the most frequent aspect corresponding to the classic "tongue of antibiotics". Some patients complain of pain on ingesting acidic dishes. In the case of HIV infection, erythematous candidiasis is often chronic.

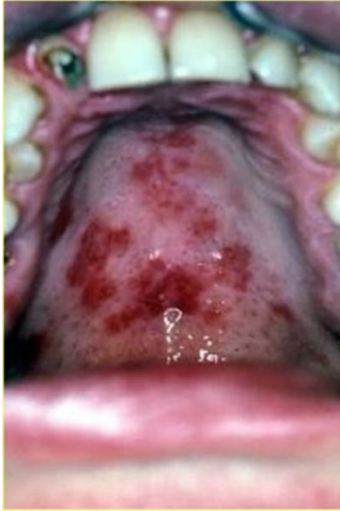

Figure 1: Acute erythematous candidiasis of the palate in an HIV-positive homosexual.

-Pseudomembranous candidiasis or thrush (Figure 2): Clinically, this candidiasis is characterized by the presence of whitish or yellowish plaques on an erythematous mucosa. The whitish plaque can be removed by scraping to make way for a bloody surface. This type of candidiasis is most often observed in the palate, the labial and cheek mucous membranes, and the dorsal surface of the tongue.

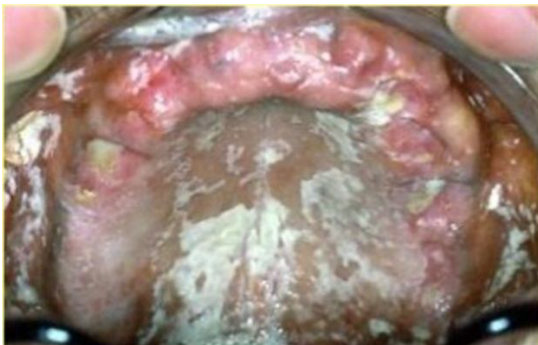

Figure 2: Diffuse pseudomembranous candidiasis of the palate and tongue.

-Hyperplastic candidiasis (Figure 3): It is observed as a white, raised, and adherent keratotic lesion. The whitish plaques are very difficult to be removed by scraping. Its clinical appearance varies from a vaguely reticulated white network, having the appearance of lichen planus, to that of a homogeneous white plaque.

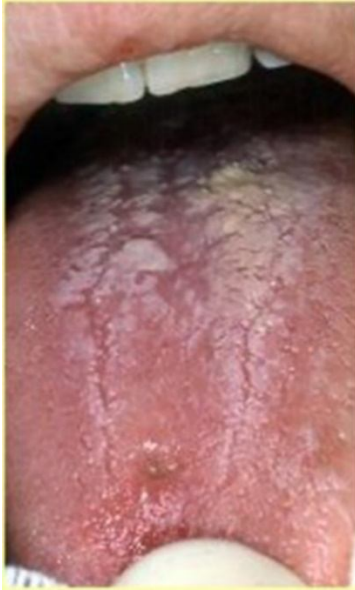

Figure 3: Hyperplastic candidiasis of the tongue in an HIV-positive drug addict.

-The black hairy tongue (Figure 4): In some situations, the tongue turns brown and then black. The associated papillary hypertrophy can reach several millimeters and give the appearance of a hairy or villous tongue. The black color is attributed to the oxidation of keratin.

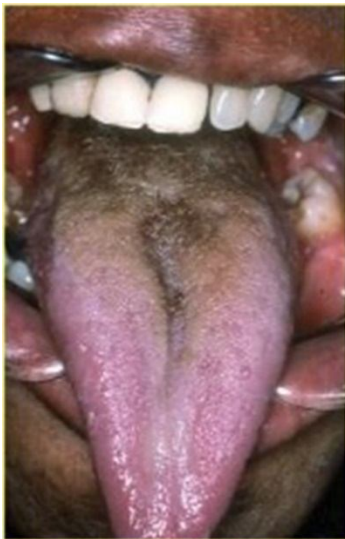

Figure 4: A black hairy tongue.

Angular cheilitis (Figure 5): It is observed in children, diabetics, cirrhotic alcoholics, Asians, immunodepressed, and in poorly fitted toothless jaws. Moreover, it is mainly due to *Candida albicans* and superinfection with frequent streptococcus. Perleche is an intertrigo of the commissure of the lips; it is also called angular cheilitis. The lesion is uni- or bilateral, erosive, bright red, and sometimes crusty, sitting at

the commissures in the form of a fan-shaped epidermal erosion. The folds of the commissure are marked, pinker, with a little damp [9]. Internal oral candidiasis makes the etiological diagnosis easy. Sometimes there is an extension of the lesion on the retro-commissural mucous surface of the cheek.

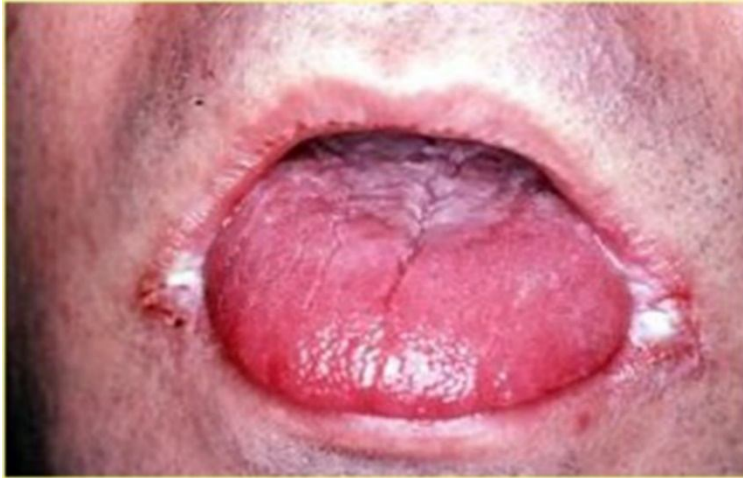

Figure 5: A unilateral Perleche.

- Cheilitis (Figure 6): *Candida albicans* lip infection is rare, and it includes a pattern of erosive lesions on an inflamed and enlarged lip. In any case, these candidiasis in HIV-positive subjects are often a sign of the development of AIDS.

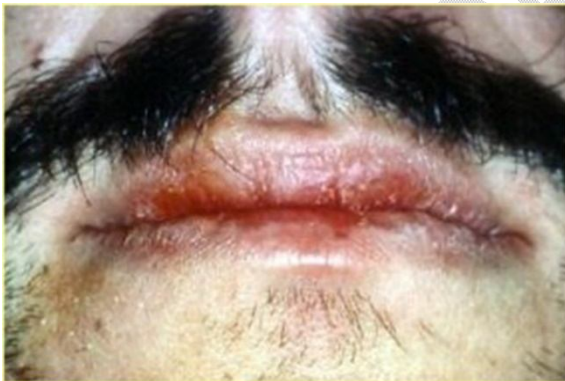

Figure 6. Angular Cheilitis in an HIV-positive homosexual.

4. ORAL CANDIDIASIS CAUSING PATHOGEN

Candida albicans (formerly called *Monilia albicans*, *Oidium albicans*) is usually the pathogen causing oral candidiasis [10]. In the saprophytic state, it is a yeast reproducing by budding (blastospores), whilst in the

parasitic state, it forms filaments (pseudo and mycelium) (Figure 7). Among the 34 other species of *Candida*, only few are occasionally pathogenic including *C. tropicalis*, *C. pseudotropicalis*, *C. guilliermondii*, *C. krusei*, *C. brumptii*... [4, 6, 10, and 11].

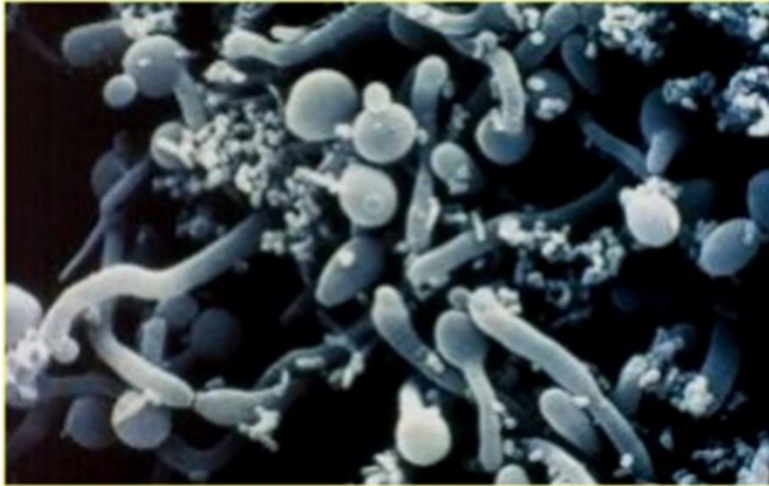


Figure 7: *Candida albicans* in the form of filaments and bacterial flora.

5. MYCOLOGICAL EXAMINATION OF ORAL CANDIDIASIS

Oral diagnosis is based on clinical examination complemented by mycological examination. Moreover, it is based on the identification of fungal elements based on direct examination and cultivation in different places. The samples guided by the clinical lesions will be either swab smears or scrapings at the level of the observed lesions. However, it is necessary to know the elective points, including the corner of the lips, cheek wall, behind the commissure, posterior median part of the back of the tongue, and the palate, where there is the greatest chance of finding yeasts. Each of these points should be sampled separately.

The presence of candida on the smears revealed, by direct examination, its appearance in the form of oval or rounded elements, budding or not, and more or less regular mycelial filaments [12]. It is important to note the abundance of fungal elements on direct examination. Nevertheless, cultivation in specific environments (Sabouraud, Microstix) allows a more precise diagnosis. *Candida albicans* in the form of spore, or more rarely in the form of filaments, is a part of the normal oral flora; hence it should be emphasized that the presence of candida in the mouth does not have any pathological value. In addition, to make the diagnosis of candidiasis, there must be a large number of colonies (in cultivation) or filaments (on smears) [6, 12, and 13].

6. TREATMENT

Candida infection is often slow to disappear; so, treatment should be of long-term duration. The treatment must be preceded by a mycological sample, and should be associated with the search for predisposing and suppressing/eliminating factors [14]. In immune-compromised people, the combination of antifungal treatment with other drugs should be monitored. Treatment can be local or systemic. However, it is often effective but recurrence is common due to immunosuppression.

6.1. LOCAL TREATMENT

Local treatment can be based on an oral suspension, ointment, or gel in the case of angular cheilitis and cheilitis. The most common used treatment includes mouthwashes with sodium bicarbonate combined with NYSTATIN, AMPHOTERICIN B, MICONAZOLE, or KETOCONAZOLE. [6, 13, 14, and 15].

6.2. GENERAL TREATMENT

General treatment includes the following:

- AMPHOTERICIN B in tablets 10 to 100 mg/6 hours.
- MICONAZOLE in tablets 250mg/6 hours.
- KETOCONAZOLE in tablets 200 to 400 mg/day.
- FLUCONAZOLE in tablets 50 to 100 mg/day.

Failures have been observed during treatment with KETOCONAZOLE. Its side effects are not negligible and liver damage is frequent [15, 16]. Moreover, it seems that FLUCONAZOLE is the best tolerated in HIV-positive patients. Its effectiveness is superior to other antifungals because it is better absorbed at the intestinal level. Moreover, it was found that the lifespan is longer with minimal side effects and that a single dose of 150 mg per week is sufficient for prophylactic treatments. In addition, it was found that it does not alter taste and above all its salivary level is identical to the serum level, hence its effectiveness against oral candidiasis [16-18 and 19].

7. CONCLUSION

Odontologist plays a significant role in the epidemiology of this disease. In most cases, the first signs of HIV infection can appear in the mouth, highlighting the need of identifying the oral mucosa and carrying out an in-depth clinical examination.

The finding of oral candidiasis in young adults, its resistance to antifungal treatments, and its persistence beyond six weeks, is doubtful when the other responsible causes have been eliminated, such as antibiotic treatment, corticosteroid therapy, antidepressants, radiotherapy, and poor oral hygiene in dentures wearers... [13].

Today, our profession is facing a new pathological entity; about 95% of patients infected with HIV have one or more lesions in the oral cavity. Practitioners should know the oral manifestations associated with HIV infection.

Odontologist will have to treat the oral lesions observed during this disease. This requires a deep knowledge of the medical problem of the patients. The purpose of this treatment will be not only to relieve the pain of those HIV patients, but also to provide them with a certain physical and psychological comfort and to improve the quality of their way of life.

CONSENT

None

ETHICAL APPROVAL

None

REFERENCES

1. Shiels MS, Engels EA. Evolving epidemiology of HIV-associated malignancies. *Curr Opin HIV AIDS*. 2017 Jan; 12(1):6-11. doi: 10.1097/COH.0000000000000327. PMID: 27749369; PMCID: PMC5240042.
2. Brady LJ, Walker C, Oxford GE, Stewart C, Magnusson I, McArthur W. Oral diseases, mycology and periodontal microbiology of HIV-1-infected women. *Oral Microbiol Immunol*. 1996 Dec; 11(6):371-80. doi: 10.1111/j.1399-302x.1996.tb00198.x. PMID: 9467369.
3. Peacock ME, Arce RM, Cutler CW. Periodontal and other oral manifestations of immunodeficiency diseases. *Oral Dis*. 2017 Oct; 23(7):866-888. doi: 10.1111/odi.12584. Epub 2016 Oct 10. PMID: 27630012; PMCID: PMC5352551.

4. Khademi F, Yousefi-Avarvand A, Sahebkar A, Ghanbari F, Vaez H. Bacterial Co-infections in HIV/AIDS-positive Subjects: A Systematic Review and Meta-analysis. *Folia Med (Plovdiv)*. 2018 Sep 1; 60(3):339-350. doi: 10.2478/folmed-2018-0007. PMID: 30355845.
5. Moosazadeh M, Shafaroudi AM, Gorji NE, Barzegari S, Nasiri P. Prevalence of oral lesions in patients with AIDS: a systematic review and meta-analysis. *Evid Based Dent*. 2021 Nov 17. doi: 10.1038/s41432-021-0209-8. Epub ahead of print. Erratum in: *Evid Based Dent*. 2022 Mar; 23(1):5. PMID: 34795396.
6. Erfaninejad M, Zarei Mahmoudabadi A, Maraghi E, Hashemzadeh M, Fatahinia M. Epidemiology, prevalence, and associated factors of oral candidiasis in HIV patients from southwest Iran in post-highly active antiretroviral therapy era. *Front Microbiol*. 2022 Sep 2; 13:983348. doi: 10.3389/fmicb.2022.983348. PMID: 36118210; PMCID: PMC9478364.
7. Berberi A, Aoun G. Oral lesions associated with human immunodeficiency virus in 75 adult patients: a clinical study. *J Korean Assoc Oral Maxillofac Surg*. 2017 Dec; 43(6):388-394. doi: 10.5125/jkaoms.2017.43.6.388. Epub 2017 Dec 26. PMID: 29333368; PMCID: PMC5756795.
8. Aškinytė D, Matulionytė R, Rimkevičius A. Oral manifestations of HIV disease: A review. *Stomatologija*. 2015; 17(1):21-8. PMID: 26183854.
9. Lomelí-Martínez SM, González-Hernández LA, Ruiz-Anaya AJ, Lomelí-Martínez MA, Martínez-Salazar SY, Mercado González AE et al. J. Oral Manifestations Associated with HIV/AIDS Patients. *Medicina (Kaunas)*. 2022 Sep 3; 58(9):1214. doi: 10.3390/medicina58091214. PMID: 36143891; PMCID: PMC9504409.
10. De Almeida VL, Lima IFP, Ziegelmann PK, Paranhos LR, and de Matos FR. Impact of highly active antiretroviral therapy on the prevalence of oral lesions in HIV-positive patients: a systematic review and meta-analysis. *Int J Oral Maxillofac Surg*. 2017 Nov; 46(11):1497-1504. doi: 10.1016/j.ijom.2017.06.008. Epub 2017 Jul 3. PMID: 28684301.
11. Ottria L, Lauritano D, Oberti L, Candotto V, Cura F, Tagliabue A, Tettamanti L. Prevalence of HIV-related oral manifestations and their association with HAART and CD4+ T cell count: a review. *J Biol Regul Homeost Agents*. 2018 Jan-Feb; 32(2 Suppl. 1):51-59. PMID: 29460518.
12. Mohamed AA, Lu XL, Mounmin FA. Diagnosis and Treatment of Esophageal Candidiasis: Current Updates. *Can J Gastroenterol Hepatol*. 2019 Oct 20; 2019:3585136. doi: 10.1155/2019/3585136. PMID: 31772927; PMCID: PMC6854261.
13. Kumar S, Mishra P, Warhekar S, Airen B, Jain D, Godha S. Oral Health Status and Oromucosal Lesions in Patients Living with HIV/AIDS in India: A Comparative Study. *AIDS Res Treat*.

2014; 2014:480247. doi: 10.1155/2014/480247. Epub 2014 Aug 20. PMID: 25215229; PMCID: PMC4158162.

14. Prabhu A, Rao AP, Reddy V, Krishnakumar R, Thayumanavan S, Swathi SS. HIV/AIDS knowledge and its implications on dentists. *J Nat Sci Biol Med.* 2014 Jul; 5(2):303-7. doi: 10.4103/0976-9668.136171. PMID: 25097403; PMCID: PMC4121903.
15. Lam-Ubol A, Rungsiyanont S, Vacharotayangul P, Sappayatosok K, Chankanka O. Oral manifestations, salivary flow rates and *Candida* species in Thai HIV-infected patients. *J Clin Exp Dent.* 2019 Feb 1; 11(2):e138-e145. doi: 10.4317/jced.55384. PMID: 30805118; PMCID: PMC6383906.
16. Rafat Z, Sasani E, Salimi Y, Hajimohammadi S, Shenagari M, Roostaei D. The Prevalence, Etiological Agents, Clinical Features, Treatment, and Diagnosis of HIV-Associated Oral Candidiasis in Pediatrics across the World: A Systematic Review and Meta-Analysis. *Front Pediatr.* 2021 Dec 24; 9:805527. doi: 10.3389/fped.2021.805527. PMID: 35004551; PMCID: PMC8740125.
17. Lyu X, Zhao C, Yan ZM, Hua H. Efficacy of nystatin for the treatment of oral candidiasis: a systematic review and meta-analysis. *Drug Des Devel Ther.* 2016 Mar 16; 10:1161-71. doi: 10.2147/DDDT.S100795. PMID: 27042008; PMCID: PMC4801147.
18. Osaigbovo II, Lofor PV, Oladele RO. Fluconazole Resistance among Oral *Candida* Isolates from People Living with HIV/AIDS in a Nigerian Tertiary Hospital. *J Fungi (Basel).* 2017 Dec 8;3(4):69. doi: 10.3390/jof3040069. PMID: 29371583; PMCID: PMC5753171.
19. Goldman M, Cloud GA, Wade KD, Reboli AC, Fichtenbaum CJ, Hafner R, et al. AIDS Clinical Trials Group Study Team 323; Mycoses Study Group Study Team 40. A randomized study of the use of fluconazole in continuous versus episodic therapy in patients with advanced HIV infection and a history of oropharyngeal candidiasis: AIDS Clinical Trials Group Study 323/Mycoses Study Group Study 40. *Clin Infect Dis.* 2005 Nov 15; 41(10):1473-80. doi: 10.1086/497373. Epub 2005 Oct 12. PMID: 16231260.