

Esthetic Root Coverage: Using a modified CAF in combination with PRF, A Case Report

ABSTRACT

Introduction: The multiple gingival recessions can lead to functional and aesthetic problems in patients. Advanced flaps are the simplest, yet are not predictable procedures for managing such conditions. The results of root coverage can be enhanced by combining the coronally advanced flap (CAF) with different regenerative techniques.

Aims: To determine the benefits of platelet-rich fibrin membrane (PRF) along with modified CAF for the treatment of Grade II Multiple gingival recession.

Methodology: A patient with Millers' class II gingival recession in three adjacent anterior teeth having a minimum 3-4 mm width of attached gingiva., Patient was treated by using modified CAF with PRF. The clinical parameters, evaluated were , vertical gingival recession depth (VGRD), gingival recession width (GRW), probing depth (PD), clinical attachment level (CAL), were recorded at baseline, and from 1 month to 3 months

Results: VGRD, GRW, PD, CAL, improved significantly from baseline to 1 month and from 1 month to 3 months

Conclusion: The use of PRF along with modified CAF is beneficial for the treatment of mild to moderate Millers Class II gingival recessions.

Keywords: [coronally advanced flap (CAF), vertical gingival recession depth (VGRD), probing Depth (PD) , Platelet-rich fibrin (PRF)]

1.INTRODUCTION

“Gingival recession is as great an esthetic problem as it is a periodontal concern. It has been clinically related to a higher incidence of root caries, attachment loss, and hypersensitivity”¹. “There are various root coverage procedures which have been successfully performed to correct this common periodontal problem. But, achieving a predictable outcome of such procedures is still challenging for periodontists. Norberg first proposed coronally positioned flap in 1926 as an esthetic surgical procedure for root coverage”.²

“Coronally advanced flap (CAF) have been frequently modified by several clinicians to obtain more predictable results. But , it was then noticed that CAF alone was not the most predictable technique for root coverage. The outcomes of CAF can be increased by combining it or its modified approach with different techniques, that involves the use of, enamel matrix derivative, synthetic allograft, connective tissue graft, platelet-rich plasma, and platelet-rich fibrin (PRF). PRF contains constituents of blood that are favorable for healing and immunity”.³ “It consists of a fibrin matrix polymerized in a tetra-molecular structure with incorporation of platelets, leucocytes, cytokines, and circulating stem cells”.⁴

2.PRESENTATION OF CASE

A 42 years old female patient reports to the Department of Periodontology with a chief complaint of hypersensitivity to cold and unesthetic appearance. There was no systemic/medical history. History of improper brushing habit was noted, On clinical examination, recessions were identified on the right and left maxillary anterior teeth with 3 mm of Miller's Class II with all the maxillary anterior teeth A thorough case history (clinical parameters like Vertical Gingival recession depth VGRD , gingival recession width (GRW), probing depth PD, CAL was taken into consideration), impressions with upper and lower arch was taken at day 1 to fabricate study models, followed by Scaling and root planing , and proper maintenance of oral hygiene was instructed . Patient was recalled after 21 days for assessment of (Vertical Gingival Recession depth (3-4 mm),gingival recession width (GRW) , PD and CAL post SRP) and for investigating the underline bone and teeth , a IOPA was advised with upper right and left anterior teeth , also patient was sent to Department of Endodontics for checking the pulp vitality.

Investigations suggested that, there was mild bone loss seen in upper right and left maxillary anterior teeth in IOPA and the pulp vitality test showed (+ ve test i.e the pulp was vital) because of which endodontic treatment was not done. after explaining the surgical procedure to the patient an informed consent was obtained

2% lignocaine with 1:200,000 adrenaline was used to anesthetize the region to be operated (Figure :1) including mesial and distal papillae a sulcular incision was made at the gingival margin, with two slightly divergent incisions at the end of the sulcular incision which extend into the alveolar mucosa (Figure: 2) the flap was elevated in the coronal-apical direction. A coronal full-thickness flap was elevated up to mucogingival junction followed by apical split thickness flap (Figure :3) All muscle fibers inserted in the flap were eliminated. The root surfaces were planed using Gracey curettes. The flap was coronally placed , so that the marginal portion of the flap seats up to the level of CEJ and the flap was stable in coronal position even without placement of suture (Figure :3)

After preparing the recipient site, 5 ml of venous blood of patient was taken, blood was poured in a test tube without anticoagulant and it was centrifuged immediately for 10 min at 2700 rpm. PRF was then obtained. The membrane was prepared by squeezing the clot between two gauze pieces (Figure: 4)

PRF membrane was placed at the operated site and the flap was adapted at the CEJ , then an aluminium foil was placed for stabilization of the PRF membrane(Figure:5), followed by placement of periodontal dressing . No sutures were placed.

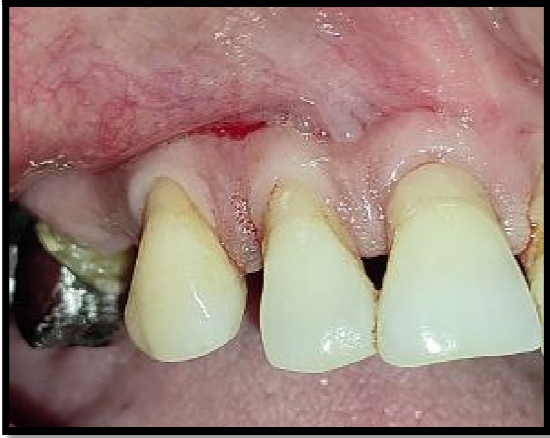

Fig.1. Anesthesia was given in the area to be operated

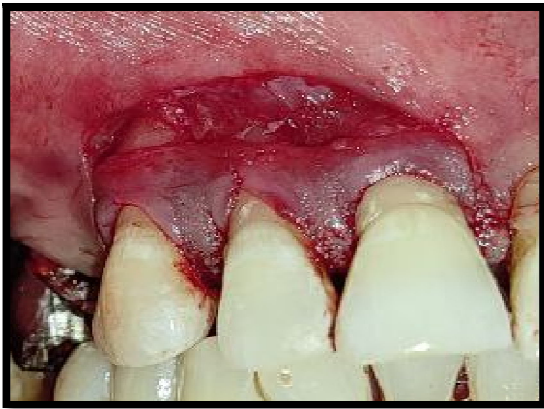

Fig.2. sulcular incision with slight divergent incisions were given

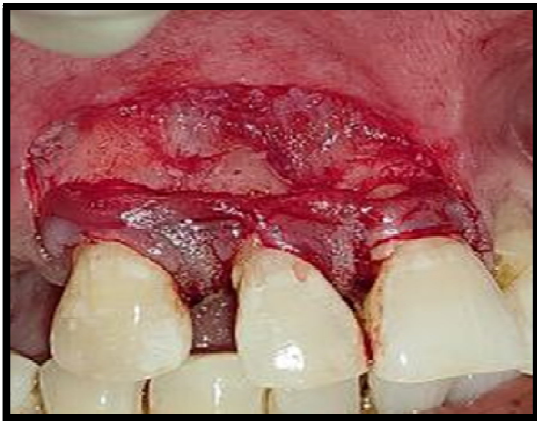

Fig.3. A flap was elevated in the coronal-apical direction.

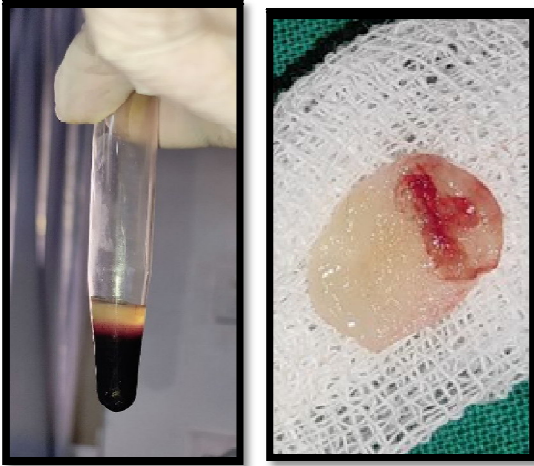


Fig.4. PRF membrane was fabricated by squeezing the PRF between two gauze pieces.

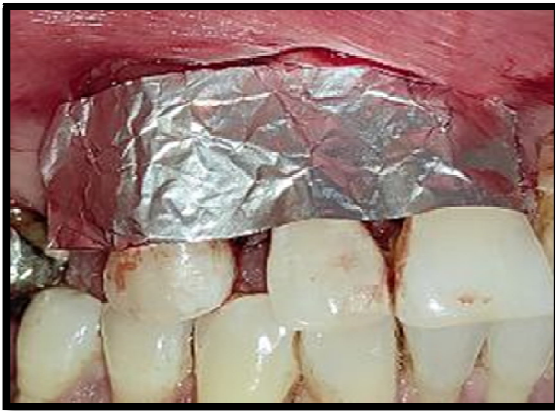

Fig.5. The fabricated PRF membrane was placed at the surgical site and flap was adapted at the CEJ and aluminum foil was placed for stabilization of the PRF membrane. followed by placement of periodontal dressing . No sutures were placed.

The Patients were given post operative instructions and were advised to avoid brushing in the operated area for the next 2 weeks. 0.2% chlorhexidine mouthwash and Zerodol tablets were prescribed twice daily for 1 week. The post surgical healing noticed was uneventful. Patient was recalled after 7 days for followup and for removal of periodontal dressing. The patient was then recalled after 21 days, 6weeks and after 3 months (Figure. 6 and figure 7)

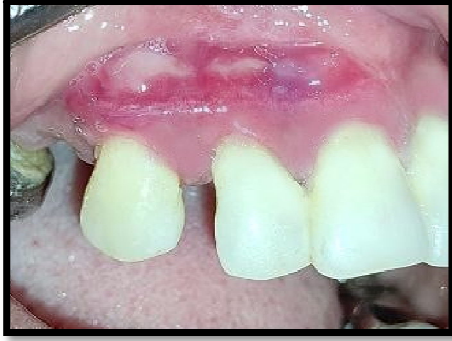

Fig.6. After 1 week

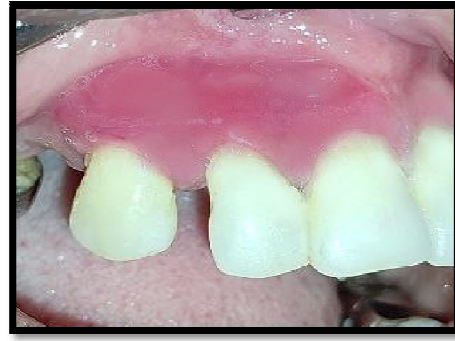

Fig.7. After 3 months

3. DISCUSSION

“CAF is a simple technique for management of gingival recession. Varying outcome of this technique has been reported widely in the literature. The present study showed significant improvement in VGRD, from baseline to 3 months on this patient, similar to many previously reported data”.^{5,6,7} “Gain in CAL also confirms the findings of previous studies”.^{8,9,10,11,12} “Increase in CAL and decrease in VGRD following modified CAF procedures may be attributed to formation of long junctional epithelium”.¹⁶

“However, the histological studies regarding the healing of pedicled grafts (e.g., CAF or rotational flap) have shown mixed results which varied from complete long junctional epithelial attachment to partial connective tissue attachment in the apical part and epithelial adaptation in the coronal part”.¹³

“Combination of full and split flap design has several advantages . Most of the earlier techniques of CAF utilized coronal displacement of flap through periosteal incisions, to eliminate the muscle tension on the flap” .^{9,14} “In the present modified technique, coronal displacement was allowed through elimination of muscle insertions as reported by de Sanctis and Zucchelli”.⁸

“This technique provided simultaneous advantages of eliminating the tension on flap as well as permitting passive displacement of flap till CEJ without sutures because of the absence of the muscle pull, thus achieving the better and stable root coverage”.¹⁶

Ghahroudi et al¹⁵ in a research similar to our study compared “the efficacy of AM and CTG in the management of root exposure. Average root coverage rates after 6 months in the two groups were 67% and 54%, respectively”.

“Results of the present Case for treatment of anterior teeth gingival recessions by CAF indicated that only benefit of the addition of PRF appears to be a significant increase in the thickness of gingiva which may improve the predictability and long-term maintenance of achieved soft tissue root coverage. Clinical significance of this needs to be evaluated in larger patient sample over a longer follow-up period”.¹⁶

4. CONCLUSION

The results obtained with the modified CAF in combination with PRF in the management of Grade II Millers gingival recession were evaluated . The values of all the clinical

parameters i.e Vertical recession depth , PD and CAL improved significantly from day 1 to 3 months. The percentage of root coverage justifies the use of PRF along with modified CAF for the treatment of (grade II acc to MILLERS) multiple gingival recessions. Also there was no secondary surgery required (for the donar site graft), no sutures were used, also this technique is cost-effective and no antegenecity was seen as PRF was used.

Consent

As per international standard or university standard, patient(s) written consent has been collected and preserved by the author(s).

Ethical Approval:

As per international standard or university standard written ethical approval has been collected and preserved by the author(s).

REFERENCES

1. Kassab MM, Cohen RE. The etiology and prevalence of gingival recession. *J Am Dent Assoc* 2003;134:220-5.
2. Maynard JG Jr. Coronal positioning of a previously placed autogenous gingival graft. *J Periodontol* 1977;48:151- 5.
3. Harris RJ, Harris AW. The coronally positioned pedicle graft with inlaid margins: A predictable method of obtaining root coverage of shallow defects. *Int J Periodontics Restorative Dent* 1994;14:228-41.
4. Zucchelli G. Advanced flaps with and without vertical releasing incisions for the treatment of multiple gingival recessions: A comparative controlled mixed clinical trial. *J Periodontol* 2000;80:1083-94.
5. Huang LH, Neiva RE, Soehren SE, Giannobile WV, Wang HL. The effect of platelet-rich plasma on the coronally advanced flap root coverage procedure: A pilot human trial. *J Periodontol* 2005;76:1768-77.
6. Bernimoulin JP, Lüscher B, Mühlemann HR. Coronally repositioned periodontal flap. Clinical evaluation after one year. *J Clin Periodontol* 1975;2:1-3.
7. Pini-Prato G, Franceschi D, Rotundo R, Cairo F, Cortellini P, Nieri M, et al. Long-term 8-year outcomes of coronally advanced flap for root coverage. *J Periodontol* 2012;83:590-4.
8. de Sanctis M, Zucchelli G. Coronally advanced flap: A modified surgical approach for isolated recession-type defects: Three-year results. *J Clin Periodontol* 2007;34:262-8.
9. Allen EP, Miller PD Jr. Coronal positioning of existing gingiva: Short term results in the treatment of shallow marginal tissue recession. *J Periodontol* 1989;60:316-9.
10. Pini Prato GP, Baldi C, Nieri M, Franseschi D, Cortellini P, Clauser C, et al. Coronally advanced flap: The postsurgical position of the gingival margin is an important factor for achieving complete root coverage. *J Periodontol* 2005;76:713-22.
11. Tenenbaum H, Klewansky P, Roth JJ. Clinical evaluation of gingival recession treated by coronally repositioned flap technique. *J Periodontol* 1980;51:686-90.
12. Aroca S, Keglevich T, Barbieri B, Gera I, Etienne D. Clinical evaluation of a modified coronally advanced flap alone or in combination with a platelet-rich fibrin membrane for the treatment of adjacent multiple gingival recessions: A 6-month study. *J Periodontol* 2009;80:244-52.
13. Ainamo J, Talari A. The increase with age of the width of attached gingiva. *J Periodontal Res* 1976;11:182-8.

14. Wennström JL, Zucchelli G. Increased gingival dimensions. A significant factor for successful outcome of root coverage procedures? A 2-year prospective clinical study. *J Clin Periodontol* 1996;23:770-7
15. Ghahroudi AA, Khorsand A, Rokn AR, Sabounchi SS, Shayesteh YS, Soolari A. Comparison of amnion allograft with connective tissue graft for root coverage procedures: a double-blind, randomized, controlled clinical trial. *J Int Acad Periodontol*. 2013;15:101–12
16. Dixit N, Lamba AK, Faraz F, Tandon S, Aggarwal K, Ahad A. Root coverage by modified coronally advanced flap with and without platelet-rich fibrin: A clinical study. *Indian Journal of Dental Research*. 2018 Sep 1;29(5):600.