

Case report

Post COVID-19 Mucormycosis In Mandible- Case Report Of Two Rare Cases

ABSTRACT

Background: Mucormycosis, also known as black fungus, is a fulminant fungal infection that occurs most often in diabetic and immunocompromised individuals. It is a severe, life-threatening, invasive fungal illness. Mucormycosis of the paranasal sinuses and surrounding anatomical structures have been occurring at an unprecedented pace as a result of the widespread use of steroids, an increase in **cytokines**, and in diabetes individuals. People who have COVID-19, a recent pandemic, are also vulnerable to this fungal illness, which frequently affects the maxilla. Rarely does the mandible become involved alone, and there **aren't many** examples that have been documented in the literature. **Method:** In this paper, we have reported two cases of **Post COVID-19 Mucormycosis In the Mandible**. The case report includes a brief literature review and data on the clinical findings, radiographic examinations, and histological results.

Keywords: Mandibular Mucormycosis, Post COVID-19, Mucor, Fungal infection, Black fungus, SARS-CoV2.

INTRODUCTION

The severe acute respiratory syndrome coronavirus type 2 (SARS-CoV2) is the cause of COVID-19, which is most frequently linked to a number of opportunistic bacterial and fungal infections. It may also be linked to pre-existing comorbidities, such as diabetes mellitus, lung disease, or any infections contracted in a hospital.[1] *Aspergillus* and *Candida* are two key microorganisms that are significant coinfections in COVID-19 patients among fungal infections. In addition to these fungi, mucormycosis is a more prevalent illness at the moment, particularly in India, and it is more noticeable in those who have COVID-19.[2] In the compromised host, mucormycosis results from altered immunity in which rapid proliferation and invasion of Mucorales organisms ensue in deeper tissues. As a component of the host's defensive mechanism, phagocytes play a major role in controlling mucormycosis infection. However, when a person is receiving corticosteroid medication, their capacity to inhibit the genesis of fungal spores is diminished.[3] The endothelium is invaded by the fungus' hyphae, which then cause thrombosis and infarctions, which lead to progressive tissue ischaemia and necrosis of the afflicted tissues.

The six accepted clinical types of mucormycosis are as the following.[4]

- (1) Rhinocerebral mucormycosis, often associated with diabetes mellitus.
- (2) Gastrointestinal mucormycosis
- (3) Pulmonary and disseminated mucormycosis
- (4) Burn wound mucormycosis.
- (5) CNS mucormycosis.
- (6) Endocarditis and vascular mucormycosis following cardiac surgery.

The maxilla is the most typical site of mucormycosis, while the mandible is only very rarely affected. The rhinocerebral variety of mucormycosis is life-threatening. In this article, we describe a rare instance of post-COVID mucormycosis in a 45-year-old male mandible.

Comment [HM1]: Why didn't you do any lab or fungal culture "Cultivation of Mucorales" for definitive diagnosis?
(Dalimot, J.J.; Smith, I.M.C.; Gerkrath, J.; Hartmann, S.; Cornely, O.A.; Lee, S.C.; Heitman, J.; Rickerts, V. Identification of Mucormycosis by Fluorescence In Situ Hybridization Targeting Ribosomal RNA in Tissue Samples. *J. Fungi* 2022, 8, 289. <https://doi.org/10.3390/jof8030289>)

CASE DESCRIPTION AND RESULTS

Case report-1

A 50 year old male patient reported to the government dental college & hospital with a chief complaint of pain, pus discharge, and swelling on the lower face region since one month.

Patient has past medical history of covid-19 before 2 years and was under treatment with corticosteroids. He is also having a history of Type 2 diabetes mellitus since 4-5 years, and patient is taking Telmisartan 40 mg (Anti-hypertensive, angiotensin receptor blocker (ARB)) for the same and History history of mandible and maxilla fracture before 6 months was also present reported.

Comment [HM2]: Was your patient taking a medication for diabetes, please mention his method of controlling his disease

Comment [HM3]: Was your patient hypertensive? why are you giving an anti-hypertensive drug?

Comment [HM4]: Mention if the treatment was uneventful

Extraoral examination revealed diffuse swelling on the lower face region with mild tenderness on palpation and normal overlying skin.(Fig-1) Intraoral examination revealed an edentulous mandibular alveolar ridge with exposed necrosed bone in the alveolar crest region extending from 38 to 46.(Fig-2) The exposed bone was soft to firm in consistency. Pus discharge was present and the surround mucosa was inflamed.

Comment [HM5]: surrounding

Radiographic investigation using orthopantomogram (OPG), Revealed-revealed missing all mandible-mandibular teeth, and a generalized decrease in bone density. The mixed radiopaque and radiolucent density of bone was present. Radiodensity with moth-eaten appearance involving the whole mandible with the coronoid and condylar process was seen. On CT-Scan aggressive osteolytic changes with a permeative pattern of bone destruction were evident.(Fig-3)

Based on the history, clinical examination, and radiographic findings a provisional diagnosis of osteomyelitis has arrived provisioned. Grossing of the specimen showed a single hard tissue measuring approximately about 3x2x1.8 cm in size dark brown to black in colour, -with soft to firm in consistency and a few areas with necrotic bone. On histological examination, H&E, as well as PAS staining sections, revealed considerable necrosis with ribbon-like fungal non septate hyphae, some of which branched at 90 degree with sparse inflammatory components in a bony background.(Fig-4) The patient was admitted to the oral maxillofacial surgery department. Full thickness mucoperiosteal flap was reflected and mandible debridement was done along the whole mandible followed by primary closure.(Fig-5) The patient showed better improvement after the treatment and is under regular follow-up.

Comment [HM6]: Why didn't you do any lab or fungal culture "Cultivation of Mucorales" for definitive diagnosis?
(Dalimot, J.J.; Smith, I.M.C.; Gerkrath, J.; Hartmann, S.; Cornely, O.A.; Lee, S.C.; Heitman, J.; Rickerts, V. Identification of Mucormycosis by Fluorescence In Situ Hybridization Targeting Ribosomal RNA in Tissue Samples. J. Fungi 2022, 8, 289. <https://doi.org/10.3390/jof8030289>)

Comment [HM7]: (Periodic Acid-Schiff) add the full term before abbreviation

Comment [HM8]: Please describe your method of closure and the suture material, and whether you put a drain or not?

Comment [HM9]: The fig shows wound dehiscence, did you observe such a complication? If yes please elaborate

Case Report 2

A 52 year old male patient reported to the government dental college & hospital with a chief complaint of pain and pus discharge on the lower face region since one month.

The patient has a past medical history of covid-19, before 1.5 years ago and was under treatment with corticosteroids. He is also having reported a history of Type 2 diabetes mellitus since one year as well. The patient had a previous history of Mucor mycosis in the mandible before one year also and was treated for the same.

The extraoral examination was did not showing any swelling and the overlying skin was normal and no tenderness nor sinus and fistula were there observed.

Intraoral examination showed exposed necrosed bone on both the right and left posterior alveolar ridge.(Fig-6) The exposed bone was soft to firm in consistency. Pus discharge was present and the surrounding mucosa was inflamed.

On CT-Scan examination, there was cortical thickening and bony remodeling noted involving the entire mandible. Osteolytic destruction was noted involving rami, bilateral mandibular canal, body, and left condylar process. The left condylar process appears appeared deformed with lytic destruction and loss of normal curvature. Bony sequestrum was noted involving the ramus on the left side.(Fig-7) Radiological features were suggested suggestive of chronic osteomyelitis. Based on history, clinical examination, and radiographic findings a provisional diagnosis of a recurrent case of Mucor mycosis was achieved. Grossing of the specimen showed multiple hard tissues measuring approximately about 1.5x1.1x1.0 cm to 1.2x1.0x.8 in size dark brown to black in colour. The consistency of bony fragments was firm to hard. On histological examination, H&E revealed considerable necrosis with ribbon-like fungal non septate hyphae, which is was branched branching at 90 degree. Chronic inflammatory cell infiltration was there depicted in the connective tissue.(Fig-8)

Curettage and removal of dead necrotic bone was done under local anesthesia followed by irrigation. The final diagnosis made based on clinical, radiological, and histological examination was a recurrent case of post covid-19 mucor mycosis.

Discussion

The word "mucormycosis" refers to any illness brought on by a fungus. It is typically an opportunistic infection of fungal origin that most frequently affects immunocompromised individuals, uncontrolled diabetes, lymphomas, leukemias, renal failure, organ transplant, corticosteroids, immunosuppressive therapy, and rare in healthy individuals. At present,

Comment [HM10]: what were the results of this treatment?

Comment [HM11]: Did you do any saucerization? if yes please describe the procedure in better details

Comment [HM12]: In both cases
What was the result of the treatment ?
How long was the follow-up?
Did you use any systemic supportive treatment?
Where there any complications?
Please clarify

COVID-19 is also taken into consideration in this list as it either directly or indirectly [causes causing](#) mucormycosis. [5]

The most frequent risk factor in the Indian context is diabetes mellitus, however, in other nations like the US and Europe, the risk factors include hematological cancers and organ transplants.[6] The most common factors that encourage the growth of fungi in COVID-19 patients include hyperglycemia, hypoxia, diabetic ketoacidosis, high iron levels, decreased phagocytic activity, steroid-mediated conditions, and other pre-existing comorbidities. Hyperglycemic status has been reported in individuals affected with COVID-19, SARS-CoV-1, and also in pneumonia unrelated to SARS-CoV-1.[7] Concerning the [present](#) case, the patient is diabetic for the past 5 years and is under [medication](#). Based on this participation, mucormycosis most frequently affects the sinus (39%), lungs (24%), and skin (19%); the transmission method might be either spore inhalation or direct injection. At present, the number of mucormycosis cases reported to affect the mandible is minimal accounting for its rarity.[8] It is also seen in a patient who are under treatment with immunosuppressive drugs (steroids or methotrexate) as stated by Vinh *et al.*[9] and Warris and Henriet.[10] In our case, mucormycosis was present in the mandible with a history of dental treatment post-COVID and underlying history of diabetes, and ~~the patient was under~~ corticosteroids [therapy](#) as a part of the COVID treatment regimen.

Comment [HM13]: first case

Comment [HM14]: which medication?

In H&E staining, mucormycosis histopathology often reveals wide, atypically formed, non septate hyphae with right or obtuse angle branching, although PAS or silver stains make them clearly visible. The organism is usually found near the area of necrosis, especially close to the necrotic vessel walls.[11] PAS and Grocott's methenamine silver stains can be used for further confirmation and usually, they show broad, aseptate, irregular, and ribbon-like folding of fungal organisms and branching at an obtuse angle. PAS staining shows ribbon-like filamentous organisms, and magenta-colored hyphae at obtuse angles.[12] In our case, we performed H&E staining which showed nonseptate, ribbon-like fungal hyphae with 90° branching, whereas PAS staining showed aseptate, magenta-color-stained fungal organisms. Similar features were also reported by Verma *et al.*[13]

CONCLUSIONS

Clinicians occasionally meet additional uncommon types of mucormycosis, such as locally invasive mandibular mucormycosis without any spreading, as in our case, despite rhino-

cerebral mucormycosis being the most prevalent kind. In order to arrest the spread of the infection and lower the mortality rate, a multimodal strategy combining early diagnosis, appropriate clinical examination, radiographic investigation, histological analysis, and comprehensive surgical debridement with antifungal medication would be able to do so.

Comment [HM15]: Did you give your patients any anti fungal agents, if yes mention its name, dose, frequency. If yes you should mention this in the methodology section.
If no you cannot use it in your conclusion statement

REFERENCES

1. Mehta S, Pandey A. Rhino-orbital mucormycosis associated with COVID-19. *Cureus* 2020;12:e10726.
2. Song G, Liang G, Liu W. Fungal co-infections associated with global COVID-19 pandemic: A clinical and diagnostic perspective from China. *Mycopathologia* 2020;185:599-606.
3. Waldorf AR. Pulmonary defense mechanisms against opportunistic fungal pathogens. *Immunol Ser* 1989;47:243-71.
3. L. Eisenberg, T. Wood, and R. Boles, "Mucormycosis," *Laryngoscope*, vol. 87, no. 3, pp. 347-356, 1977.
5. Dimaka K, Mallis A, Naxakis SS, Marangos M, Papadas TA, Stathas T, *et al.* Chronic rhinocerebral mucormycosis: A rare case report and review of the literature. *Mycoses* 2014;57:699-702.
6. Singh AK, Singh R, Joshi SR, Misra A. Mucormycosis in COVID-19: A systematic review of cases reported worldwide and in India. *Diabetes Metab Syndr* 2021;15:102146.
7. Montefusco L, Ben Nasr M, D'Addio F, Loretelli C, Rossi A, Pastore I, *et al.* Acute and long-term disruption of glycometabolic control after SARS-CoV-2 infection. *Nat Metab* 2021;3:774-85.
8. Mishra N, Mutya VS, Thomas A, Rai G, Reddy B, Mohanan AA, *et al.* A case series of invasive mucormycosis in patients with COVID-19 infection. *Int J Otorhinolaryngol Head Neck Surg* 2021;7:867-70.
9. Agarwal S, Anand A, Ranjan P, Meena VP, Ray A, Dutta R, *et al.* Case of mucormycosis of mandible after self-extraction of teeth incidentally detected to have

Formatted: Numbered + Level: 1 +
Numbering Style: 1, 2, 3, ... + Start at: 1 +
Alignment: Left + Aligned at: 0.25" + Indent at: 0.5"

chronic granulomatous disease: Case report and literature review. *Med Mycol Case Rep* 2020;28:55-9.

- 10.** Vinh DC, Freeman AF, Shea YR, Malech HL, Abinun M, Weinberg GA, *et al.* Mucormycosis in chronic granulomatous disease: Association with iatrogenic immunosuppression. *J Allergy Clin Immunol* 2009;123:1411-3.
- 11.** Warris A, Henriet SS. Invasive fungal infections in the child with chronic granulomatous disease. *Curr Fungal Infect Rep* 2014;8:37-44.
- 12.** Aggarwal P, Saxena S, Bansal V. Mucormycosis of maxillary sinus. *J Oral Maxillofac Pathol* 2007;11:66-9.
- 13.** Verma M, Sharma R, Verma N, Verma K. Rhinomaxillary mucormycosis presenting as palatal ulcer: A case report with comprehensive pathophysiology. *J Oral Maxillofac Pathol* 2020;24:558-62.

FIGURES

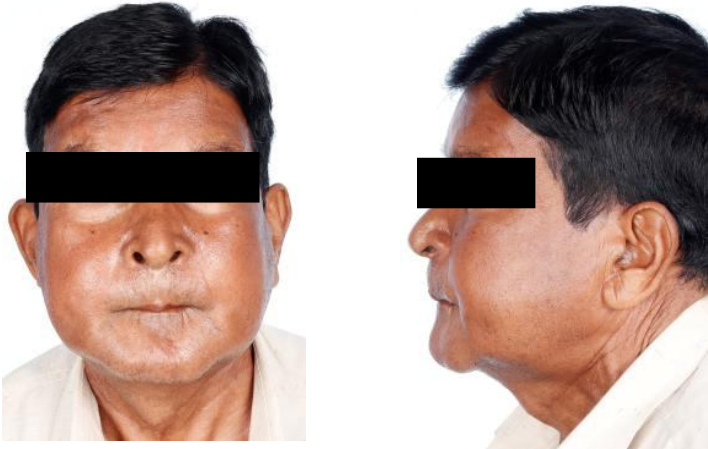

Fig-1 Extraoral swelling

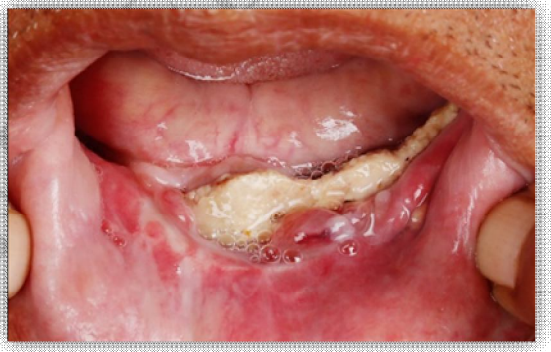

Fig-2 Exposed necrosed mandibular alveolar bone

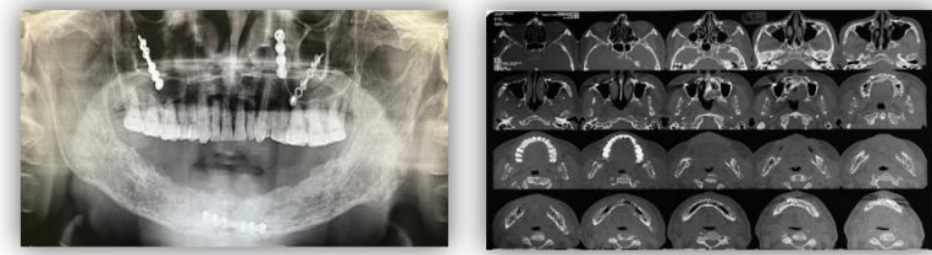


Fig-3 OPG and CBCT showing osteolytic changes

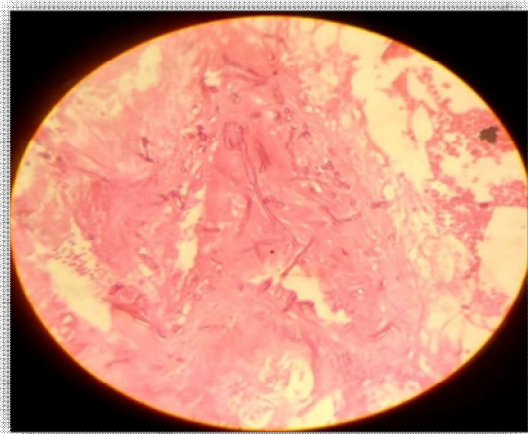


Fig-4 H&E stained section showing ribbon like fungal nonseptate hyphae

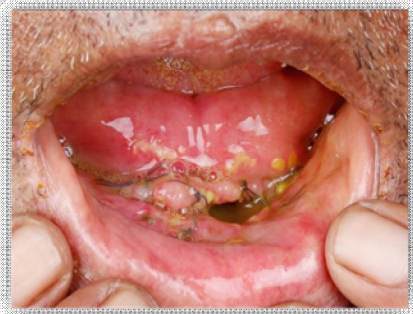

Fig-5 Primary closure after mandible debridement

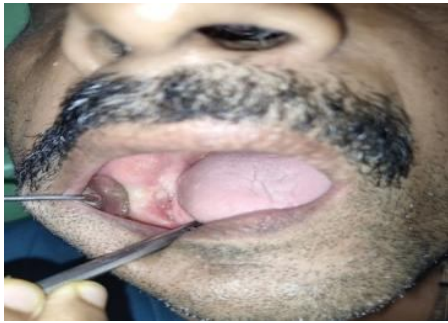

Fig 6 Exposed bone in posterior right mandibular alveolar ridge



Fig-7 Osteolytic destruction noted involving rami, bilateral mandibular canal, body and left condylar process. Left condylar process appears deformed with lytic destruction and loss of normal curvature. Bony sequestrum noted involving ramus on left side.

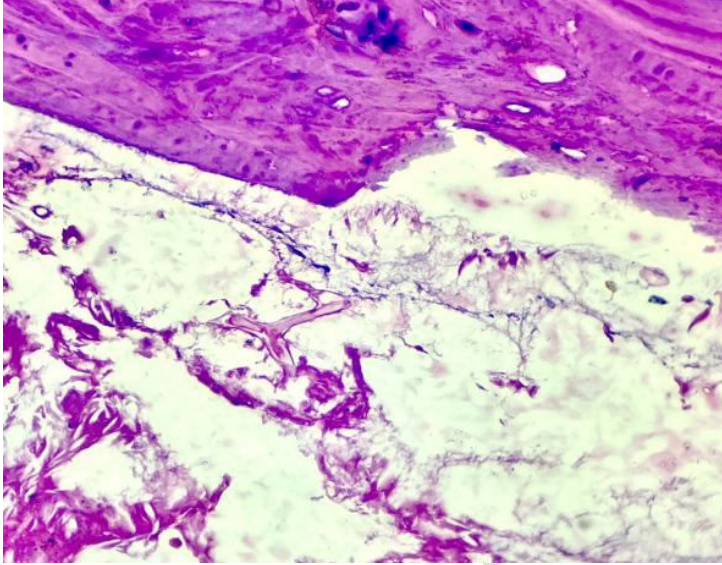


Fig-8 H&E stained section showing ribbon like fungal nonseptate hyphae