

Case report

Left trans-thoracic evisceration of a perforated transverse colon associated to a bilateral penetrating thorax stab wound and a left gastric tear about one case.

Abstract

The authors report here a rare case of transverse colon evisceration through the thorax. The patient is a 31 years old security agent who presented to the emergency 15 minutes after been stabbed on both thorax. The left thoracic wound was the site of evisceration of colon. The 20cm eviscerated colon was perforated on 2cm. The patient was instable. After a 30 minutes stabilisation, they operated him under general anesthesia. A double drainage of the thorax was done, one on each sides. The right thoracic stab wound was then closed in 3 layers. A median laparotomy was performed. They discovered the left colic herniation through the left diaphragmatic area, continuing through the thorax by the evisceration and a gastric tear of 20 centimeters. The colon was washed reduced first through the abdomen by gentle traction. The left parietal wound was then closed in 3 layers. The left lung could be seen through the abdomen, as a perihilar ratatinated mass expanding with inspiration. The left thorax cavity was washed The 20cm diaphragmatic hole was closed in two layers. The left transverse colonic tear was excised and closed in 2 layers. The left sub phrenic area was drained and the Douglas pouch too. The patient had 5 days antibiotics, intraveinuous antalgics (paracetamol and nefopam), a 500cc blood transfusion, oxygen, 2 intraveinuous lines, a nasogastric tube and a urinary catheter, all of wich started in the emergency room. The thoracic drainages and th eurinary catheter were removed after 2 days. On the 5th post operative day in the intensive care unit, the naso gastric tube was removed and he was subsequently admitted in surgery for 10 days. The transit returned at day 3 and we started progressive oral liquid from day 5. The abdominal drainages was removed at day 5 post operation. We had a superficial site infection of the laparotomy wound treated by saline wet dressing for 20 days. After one month hospitalisation, the patient was discharged. At he resumed his work at tree month postoperative and is doing well 12 months postoperative. This case emphasizes on a rare trauma.

Key words : thorax stab wound – evisceration – colon – perforation- emergency thoracophrenolaparotomy

Introduction

Stab wounds are more and more frequent and poorly documented in our environment [1]. The thoracic region is most often affected and diaphragm hernias are reported [2,3]. But we report here a rare case where both thorax were stabbed with a colonic evisceration on the left.

Presentation of case

Mr. X, 31 years old, is a security guard living in Douala, who was the victim of a knife attack on March 2, 2020 in Makepe Missoqué, around 1 p.m.

After being stabbed with a hooked dagger, twice in the left and right basithoracic regions, he was immediately taken by the police by taxi to the emergency room of the Deido district hospital 15 minutes later.

On admission, he was conscious but in shock. His blood pressure was 100/10 mmHg, his respiratory rate was 28 cycles per minute, his heart rate was 100 cycles per minute and his temperature was 37.5°. Arterial blood oxygen saturation was 90%.

The conjunctivae were faintly colored and the chest covered with blood. There was a superficial polypnea, a blowing wound at the right thoracic base and at the left thoracic base a wound with evisceration of a colonic loop which in addition had a wound through which could be seen yellowish and soft stools. The blowing wound on the right thoracic base was 5 centimeters wide and leaked air on inspiration. Vocal vibrations and breath sounds were diminished, and there was eardrums. On the left, the chest wound measured 10 centimeters and was closed by evisceration.

The abdomen was not distended, not very mobile with breathing and tender to palpation. The rest of the exam was unremarkable. Our clinical diagnosis of thoraco-abdominal trauma with a blowing right chest wound and left trans-thoracic evisceration was made on the clinical basis and the indication for surgery. We were unable to do an X-ray or CT scan.

The patient was initially installed in the emergency room in a semi-sitting position, lower limbs elevated, for preoperative resuscitation. We gave him oxygen by face mask at the rate of 6 liters per minute. During the placement of two venous catheters number G18, we did a preoperative laboratory assessment which revealed moderate anemia at 9g/dl. We gave him 1000cc of physiological saline and 1000cc of Ringer's lactate on one of the lines with a perfuser and on the other he received 500cc of blood through a transfuser.

After stabilizing him for 30 minutes, he was transferred to the operating room. We performed general anesthesia with orotracheal intubation before asepsis and draping of the chest and abdomen.

The first stage of surgery was the right chest tube thoracostomy drainage. It was placed at the 5th right intercostal space in the anterior axillary line. The blowing wound was then closed in three planes: 8 separate points of polyglactin 910 (Vicryl®) number 1 on the muscle level, 8 separate points of Vicryl®) number 2 on the aponeurosis and 9 points of Blair Donati on the skin with skin thread number 2/0. The drain was secured by a fixation to the skin with skin suture number 2 and its suction brought back air and 200cc of blood.

The second operation consisted in placing the left chest drain. It was placed at the 5th left intercostal space in the anterior axillary line. This drain was also fixed to the skin with skin suture number 2 and its suction brought back air and 200cc of blood. He brought back air and 300cc of blood.

The third operation consisted of a midline laparotomy first above the umbilical then xyphopubic bypassing the umbilicus on the left. At the opening, we discovered: 100 cc of blood in the abdominal cavity, an aspiration of the transverse colon through the left diaphragmatic dome which continued with the evisceration. We washed the eviscerated and perforated colon before reducing it through the abdomen. The reduction of the diaphragmatic hernia by gentle traction therefore made it possible to reduce the evisceration and to discover a wound of 20cm on the left diaphragmatic dome. Through this wound, we could see the lower lobe of the left lung which was normal on inspection, shrunken in the hilar region and expandable on inspiration. Our drain was also visible as well as the pleural breach.

The left chest wound was closed in three planes : 8 separate points of polyglactin 910 (Vicryl®) number 1 on the muscle level, 8 separate points of Vicryl®) number 2 on the aponeurosis and 9 points of Blair Donati on the skin with skin thread number 2/0.

We then washed the pleural cavity and closed the wound of the left diaphragmatic dome in two planes with continuous suture of Vicryl® number 2, so as to obtain aerostasis. The chest tubes were kept in gentle suction to bring the lungs back to the wall.

In addition, there was a 10cm wound in the anterior aspect of the stomach along the left greater curvature of the stomach.

The gastric wound was also closed with a double continuous suture of Vicryl® number 2. The abdominal cavity was washed with saline.

There was a 2cm colonic wound located on the transverse colon slightly to the left of the midline. It was excised and sutured in two layers using Vicryl® 0.

A double drainage of the abdominal cavity was carried out: a drain towards the Douglas fossa emerged in counter-incision in the right iliac fossa and a drain under the left diaphragmatic dome, emerged in counter-incision in the left iliac fossa.

The laparotomy was closed with a number 2 Vicryl® suture on the aponeurosis and 15 Blair Donati stitches on the skin with a number 2/0 skin suture, followed by dressings.

He also received an analgesic treatment (1g of paracetamol infusion immediately then every 8 hours for 5 days combined with nefopam), antibiotics (Ceftriaxone 2g immediately then daily, Metronidazole 500 mg immediately then every 8 hours , Gentamycin 160 mg immediately then every day for 5 days), a nasogastric tube for 5 days, omeprazole 40 mg per day for 5 days, an anti-tetanus serum, a urinary catheter and dressings.

The drainages of the residual hematomas and eventual liquids was performed for 48 hours (pleural cavity). The nasogastric tube was removed after 5 days (in the morning) and the urinary catheter was removed after 48 hours. The transit returned after 3 days and progressive oral liquid intake started on day 5 in the morning. The abdominal cavity drains were removed in the evening at day 5 post operation.

The postoperative course was simple regarding the thorax, the respiration, the stomach and the colon. We had a superficial site infection of the laparotomy wound treated by wet saline dressings for 10 days and normal dressings for 10 more days. At he resumed his work at three months postoperative and is doing well 12 months postoperative. This case emphasizes on a rare traumatism and on safety measures for security agents.

Discussion

Unilateral chest trauma has been described in the literature unlike bilateral chest trauma [1]. Further more, an association of bilateral chest trauma with colonic evisceration has never been reported, to the best of our knowledge. Cases of herniated omentum have been reported [2]. The frequency of diaphragmatic injury is reported to be low in our environment : a study found 20 cases over 1535 injuries [2] in Dakar (1.3 %) and another found 27 cases in 11 years in Yaounde [5]

Diaphragm rupture is a life-threatening injury [4]. They most often occur as part of a polytrauma [5]. Traumatic diaphragm rupture follows blunt abdominal trauma in 1% to 7% or

an open thoracoabdominal trauma in 10 to 15% [4] [6]. Postoperative mortality for this lesion is between 5% and 18% [7] [8].

Mechanism

Our patient was male, aged in his thirties, and the mechanism was open trauma as reported by several authors [2,3,9]. We had a double open chest trauma. There was a hemopneumothorax as also reported by Al-Koudmani et al. in 2012 [9] after a review of 888 chest traumas over 11 years. We had a left diaphragmatic hernia as is often the case [2,3], the right side being protected by the liver. We had a transthoracic evisceration and Guy Aristide Bang [3] had already mentioned a transthoracic epiplocoele in 2022 in Yaoundé. Ours was colon transthoracic evisceration.

Diagnostic

Contrary to the Dakar [2] and Yaounde studies [3] and, our diagnosis was neither difficult nor delayed because of the visualization upon inspection of the eviscerated colon through the left basithoracic wound. But we could not imagine the associated gastric lesion which was an operative discovery; the surgeon should expect surprises in these laparotomies as suggested in 2022 [11] by Ahmed Shabhay et al. Complementary imaging examinations did not contribute to our diagnosis (not done), which is similar to cases where the diagnosis remains unclear by these examinations when they are performed [2,3] because ultimately it is the clinical reasoning that prime. This is different from the endoscopic successes (thoracoscopy and laparoscopy) reported by Sardorbek et al. in 2022 [10]. It was the colon that was eviscerated in our case, whereas generally it is the omentum or small bowel [11].

Management

We immediately opted for open surgery as found in the study published in 2021 [12] by Brittany Robinson et al. This is contrary to the proposals of endoscopic and interventional radiology, given the initial instability of our patient and the severity of the initial clinical picture. Chest tube thoracostomy was sufficient to manage our thorax stab wounds like in other publications [9,13,14]. Our drains were suctioned as recommended in 2018 [13] by Tim Michael Feenstra et al.

Prognosis

High mortality was reported in 2019 [15] by Aram Baram et al. who studied 107 patients with bilateral chest trauma. Contrary to the poor prognosis associated with these multiple trauma victims [2,3,10,12,17], our patient survived, certainly because of the onset during the day which facilitated the speed of his transport and arrival at the hospital, at a time when the whole team was in place and the operating room free.

Conclusion

This case presents and discusses a rare bilateral chest stab wound, with a left transverse colon trans diaphragmatic evisceration following a stab wound, associated to a gastric and colic tears.

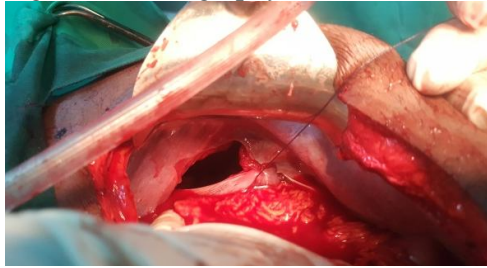
References

1. Baram A and kakamad FH. Bilateral thoracic trauma; presentation and management, a case series. *Annals of Medicine and Surgery* 2019, 43 : 25–28.
2. Thiam O, Konate I, Mohamadou LG, Toure AO, Seck M, Cisse M , Balla D, Dirie ES, Ousmane K, Thiam M, Madieng D, Abdarahmane D and Cheikh TT. Traumatic diaphragmatic injuries: epidemiological, diagnostic and therapeutic aspects. *SpringerPlus* 2016, 5:1614.
3. Guy AB, Georges BM, Ngo Yamben MA, Chappi CT, Chopkeng JC, Biwole Biwole D, Ngo Nonga B. Traumatic Rupture of the Diaphragm: Retrospective Study of 27 Cases Operated in Three Hospitals in Yaoundé (Cameroon). *Surgical Science*, 2022, 13, 207-215.
1. Choua O, Moussa KM, Aboulghassim O, Sadié IG, Mantou B, Kambel D et al. Les traumatismes diaphragmatiques à l'Hôpital General de reference Natioanle de N'djamena: A propos de 26 cas. *RECAC*, 2019 : 3, 30-33.
2. Favre, JP. Traitement chirurgical des ruptures traumatiques du diaphragme. *EMC Chirurgie*, 2005 : 2, 242-251.
3. Abdellatif W, Chow B, Hamid S, Khorshed D. Khosa F, Nicolaou S, et al. Unravelling the Mysteries of Traumatic Diaphragmatic Injury: An Up-to-Date Review. *Canadian Association of Radiologists Journal*, 2020 : 71, 313-321.
4. Hanna WC, Ferri LE, Fata P, Razek T and Mulder DS. The Current Status of Traumatic Diaphragmatic injury: Lessons Learned from 105 Patients over 13 Years. *The Annals of Thoracic Surgery*, 2008 : 85, 1044-1048.
5. Senturk M, Cakir M, Akbulut MA and Yesildag K. Approach to Traumatic Diaphragm Injuries: Single Center Experience. *Journal of Acute Medicine*, 2021 : 11, 18-21.
6. Al-Koudmani et al. Journal. Chest trauma experience over eleven-year period at al-mouassat university teaching hospital-Damascus: a retrospective review of 888 cases. *Journal of Cardiothoracic Surgery* 2012, 7:35.
7. Sardorbek MOY, Gulomidin MK. *Kardiochirurgia i Torakochirurgia Polska*. 2022, 19 (4): 226-231.
8. Ahmed S, Zarina S, Kondo C, Theresia MDM, Fabian M and Samwel C. Potential Spectrum of Accompanied Penetrating Abdominal Intra-peritoneal Injuries with Bowel Evisceration: Surprises Awaiting the Trauma Surgeon in Resource Limited Settings. *Hindawi Case Reports in Surgery* Volume 2022, Article ID 8015067, 7 pages.
9. Brittany R, Laura NP, Chifundo K, Jared G, Anthony C. Outcomes of stab wounds presenting to Kamuzu Central Hospital in Malawi. *Malawi Medical Journal* March 2021,33 (1); 1-6.
10. Tim Michael F, Chris D, Jaap D. Systematic review and meta-analysis of tube thoracostomy following traumatic chest injury; suction versus water seal. *European Journal of Trauma and Emergency Surgery* 2018, 44:819–827.
11. Jacob Z, Steven I, Scott Norwood, MD, Alan C. Hemothorax: A Review of the Literature. *Clin Pulm Med*. 2020 January, 27(1): 1–12.
12. Aram B, Fahmi HK. Bilateral thoracic trauma; presentation and management, a case series. *Annals of Medicine and Surgery* 2019, 43 :25–28.

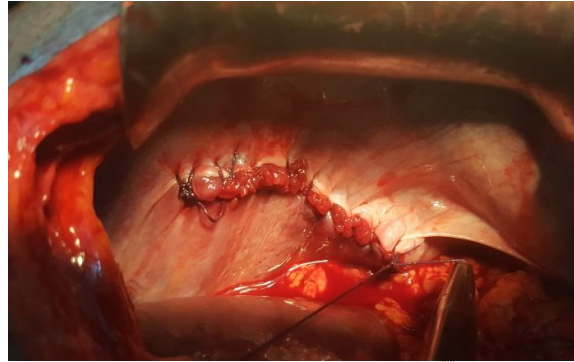13. Bayapa RN, Hanumantha, and Sainarasimha RC. An epidemiological study on pattern of thoraco-abdominal injuries sustained in fatal road traffic accidents of Bangalore: Autopsy-based study. *J Emerg Trauma Shock*. Apr-Jun 2014, 7(2): 116–120.
14. D'Souza N, Clarke D, Laing G. Prevalence, management and outcome of traumatic diaphragm injuries managed by the Pietermaritzburg Metropolitan Trauma Service. *Ann R Coll Surg Engl* 2017, 99: 394–401.

UNDER PEER REVIEW

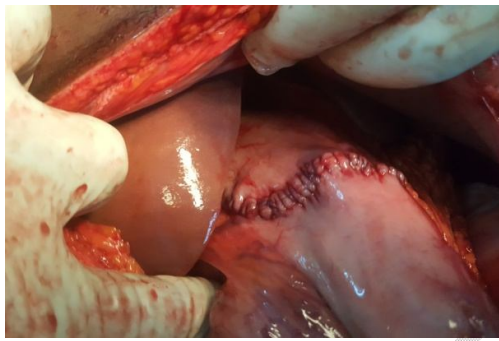
Figure 1 : Iconography



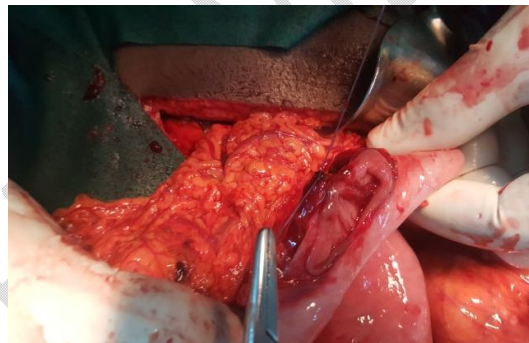A. Initial aspect of the left diaphragmatic tear



B. Left diaphragmatic tear suture



C. Left gastric tear suture



D. Resection-anastomosis of the ileal tear