

Chronic and stubborn leuco-melanoderma in a child

ABSTRACT

Aims: Pityriasis lichenoides chronic is a rare inflammatory dermatosis, unusually hypochromic in dark phototypes. The evolution of the disease is usually benign, but a malignant transformation in mycosis fungoides is reported. You have to know how to think about it when faced with a generalized hypochromic macular eruption in children.

Case report: We report a case of a 13-years-old child, phototype 4. He presented for 8 months hypochromic macular lesions, located initially at the face. The evolution was marked by the extension at the trunk and the limbs. He was treated for pityriasis versicolor but without improvement. A skin biopsy was then performed, in favor of Pityriasis Lichenoides Chronica (PLC) with a lymphoid infiltrate made up mainly of CD4 T lymphocytes. The child was put on cyclin associated with heliotherapy with regular monitoring.

Discussion: Pityriasis Lichenoides is less frequent in the pediatric population. Its etiopathogenesis is still incompletely elucidated. The basic lesion is an erythematous-squamous papule in the trunk. Hypochromic macules can also be observed, either at the cicatricial stage of the disease, or they occur immediately, especially in subjects with dark skin. The histology of PLC reveals perivascular lymphocytic infiltrate in the superficial dermis. The adopted therapeutic is based on heliotherapy or an antibiotic from the macrolide or cyclin family. Evolution towards Mycosis Fungoides has been rarely described.

Conclusion: PLC is exceptionally hypopigmented from the outset. We report a case of chronic leucomelanodermic pityriasis lichenoides in a child posing a problem of differential diagnosis.

Keywords: hypopigmented; pityriasis lichenoides; chronic ; child ;histology

1. INTRODUCTION

Pityriasis Lichenoides constitutes a spectrum of rare inflammatory dermatoses, its etiopathogenesis of which is not completely elucidated.

There are 2 clinical forms: acute varioliform lichenoid pityriasis characterized by a papular rash progressing to necrosis and chronic lichenoid pityriasis characterized by an erythematous papulosquamous rash, which is exceptionally hypopigmented from the outset. We report a case of chronic leucomelanodermic pityriasis lichenoides in a child posing a problem of differential diagnosis with other hypochromic dermatoses.

2. PRESENTATION OF THE CASE

We report a case of a 13-years-old child, phototype 4, with no notable pathological history and not vaccinated against SARS COV 2. He presented for 8 months hypochromic macular

lesions, very finely scaly, and non-pruritic, located initially at the face (figure 1) for which he was initially treated as atopic dermatitis by dermocorticoids. The evolution was marked by the extension at the trunk and the limbs (figure 2) with evolution by relapses interspersed with remission. The dermoscopy showed hypopigmented areas poorly limited without any particular pattern (figure 3). There is also no palmoplantar, phanerial or mucosal involvement. He was treated for pityriasis versicolor but without improvement. Faced with the persistence and worsening of the lesions, a skin biopsy was then performed. Skin biopsy was in favor of Pityriasis Lichenoides Chronica (PLC) with a lymphoid infiltrate (figure 4) made up mainly of CD4 T lymphocytes and CD30 were negative. A complete blood count, liver function studies, and LDH were unremarkable and there were no stigmata of infection. The child was put on cyclin associated with heliotherapy with regular monitoring given the risk of progression to mycosis fungoides. Mild repigmentation of some lesions was noted at after 6 weeks of therapy.

3. DISCUSSION

Pityriasis Lichenoides occurs mainly in the 2nd and 3rd decades of life. It is less frequent in the pediatric population, with a peak around the age of 5 to 10 years¹, and a male predominance. Its etiopathogenesis is still incompletely elucidated, but several theories have been put forward, and in particular the role of infectious agents such as Toxoplasma Gondii, HIV and EBV, as well as the involvement of certain drugs such as antibiotics or paracetamol; or even vaccines and finally the demonstration of T lymphoid proliferation, especially in the acute form.² Classically in PLC, the basic lesion is an erythematous-squamous papule. It usually appears on the trunk and the proximal part of the limbs. The face, scalp and mucous membranes are exceptionally affected.³ Hypochromic macules with little or no scaling can also be observed, either at the cicatricial stage of the disease, following the erythematous rash. And in this case, it is a post-inflammatory hypopigmentation that can be seen frequently. Or else, they occur immediately, especially in subjects with dark skin, as in the case of our patient.⁴ Dermoscopy of the leucomelanodermic form has not been described in the literature and in the case of our patient was not of diagnostic help. The average duration of depigmentation in the absence of primary lesions is 35 to 20 months for patients with PLC; this duration is longer in patients with a dark phototype. This suggests that long-lasting pigmentary change in the absence of apparent primary lesions may represent ongoing disease activity rather than a scarring reaction.⁵ In the leuco-melanodermic forms of PLC, the initial clinical diagnosis is very often directed towards more frequent dermatoses, such as : atopic dermatitis, achromic pityriasis versicolor with yellow-greenish fluorescence in Wood's light, generalized vitiligo but in this case the lesions are symmetrical, are never scaly, often with associated poliosis and Koebner and with confluent and progressive macular hypomelanosis. In the presence of an atypical evolution it is absolutely necessary to evoke Mycosis Fungoides, which manifests during childhood relatively frequently in its hypopigmented variant. Clinically there are hypochromic lesions on the trunk and extremities not photo-exposed , they are asymptomatic or slightly pruritic and may present with infiltration and/or slight erythema.⁶ We can also think of leprosy or, exceptionally, white lentiginosis and finally white spot disease especially when the lesions are small. The histology of PLC reveals: compact parakeratosis with focal spongiosis, slight mononuclear

intraepidermal exocytosis without lymphocytic atypia, and perivascular lymphocytic infiltrate in the superficial dermis. Lymphocyte immunophenotyping found a predominance of CD4+ and CD30 negative T lymphocytes, distinguishing it from lymphomatoid papulosis.⁷ There is no consensual treatment for PLC, but the most adopted therapeutic strategy in children is based on heliotherapy or an antibiotic from the macrolide or cyclin family, even in the absence of foci of infection. We can possibly treat locally with topical corticosteroids or Tacrolimus when the lesions are small. And in 2nd intention will be prescribed phototherapy based on UVB.⁸ PLC is a most often benign dermatitis, which can regress spontaneously. Evolution towards Mycosis Fungoides has been rarely described. It can also be paraneoplastic and accompany kidney or lung cancer, Hodgkin's disease or non-Hodgkin's lymphoma, hence the need for regular follow-up.⁵

4. CONCLUSION

In summary, PLC is a rare inflammatory dermatosis, of unknown etiopathogenesis; manifested by an erythematous and scaly maculopapular rash that may be unusually hypochromic in dark phototypes. The evolution of the disease is chronic, and usually benign, but a malignant transformation in particular in Mycosis Fungoides in the child is reported. You have to know how to think about it when faced with a generalized hypochromic macular eruption in children.

CONSENT (WHERE EVER APPLICABLE)

All authors declare that 'written informed consent was obtained from the patient (for publication of this case report and accompanying images. A copy of the written consent is available for review by the Editorial office/Chief Editor/Editorial Board members of this journal

ETHICAL APPROVAL

All authors hereby declare that all experiments have been examined and approved by the appropriate ethics committee and have therefore been performed in accordance with the ethical standards laid down in the 1964 Declaration of Helsinki

REFERENCES

1. Zegpi, M. S., Ruiz, F., & Porras, N. (2015). Pitiriasis liquenoide: presentación de un caso clínico y revisión de la literatura. *Revista Chilena de Pediatría*, 86(2), 121–125. <http://dx.doi.org/10.1016/j.rchipe.2015.04.024> 0370-4106
2. Bellinato, F., Maurelli, M., Gisoni, P., & Girolomoni, G. (2019). A systematic review of treatments for pityriasis lichenoides. *Journal of the European Academy of Dermatology and Venereology* <https://doi.org/10.1111/jdv.15813>
3. Moy, A., Sun, J., Ma, S., & Seminario-Vidal, L. (2019). Lymphomatoid Papulosis and Other Lymphoma-Like Diseases. *Dermatologic Clinics*. <https://doi.org/10.1016/j.det.2019.05.005>
4. Amira Elbendary 1, Mona R E Abdel-Halim 1, Randa Youssef 1, et al.

Hypopigmented lesions in pityriasis lichenoides chronica patients: Are they only post-inflammatory hypopigmentation? *Australas J Dermatol* 2022 Feb;63(1):68-73. <https://doi.org/10.1111/ajd.13746>.

5. Zang, J. B., Coates, S. J., Huang, J., Vonderheid, E. C., & Cohen, B. A. (2018). Pityriasis lichenoides: Long-term follow-up study. *Pediatric Dermatology*, 35(2), 213–219. <https://doi.org/10.1111/pde.13396>
6. Cynthia M. Magro, Joshua W. Hagen, Arthur N. Crowson, et al .Hypopigmented interface T-cell dyscrasia: A form of cutaneous T-cell dyscrasia distinct from hypopigmented mycosis fungoides.*The journal of dermatology* 08 May 2014 . <https://doi.org/10.1111/1346-8138.12458>
7. Geller, L., Antonov, N. K., Lauren, et al .M. C. (2015). Pityriasis Lichenoides in Childhood: Review of Clinical Presentation and Treatment Options. *Pediatric Dermatology*, 32(5), 579–592. <https://doi.org/10.1111/pde.12581>
8. Maranda, E. L., Smith, M., Nguyen, A. H., et al.(2016). Phototherapy for Pityriasis Lichenoides in the Pediatric Population: A Review of the Published Literature. *American Journal of Clinical Dermatology*, 17(6), 583–591. <https://doi.org/10.1007/s40257-016-0216-2>

FIGURES

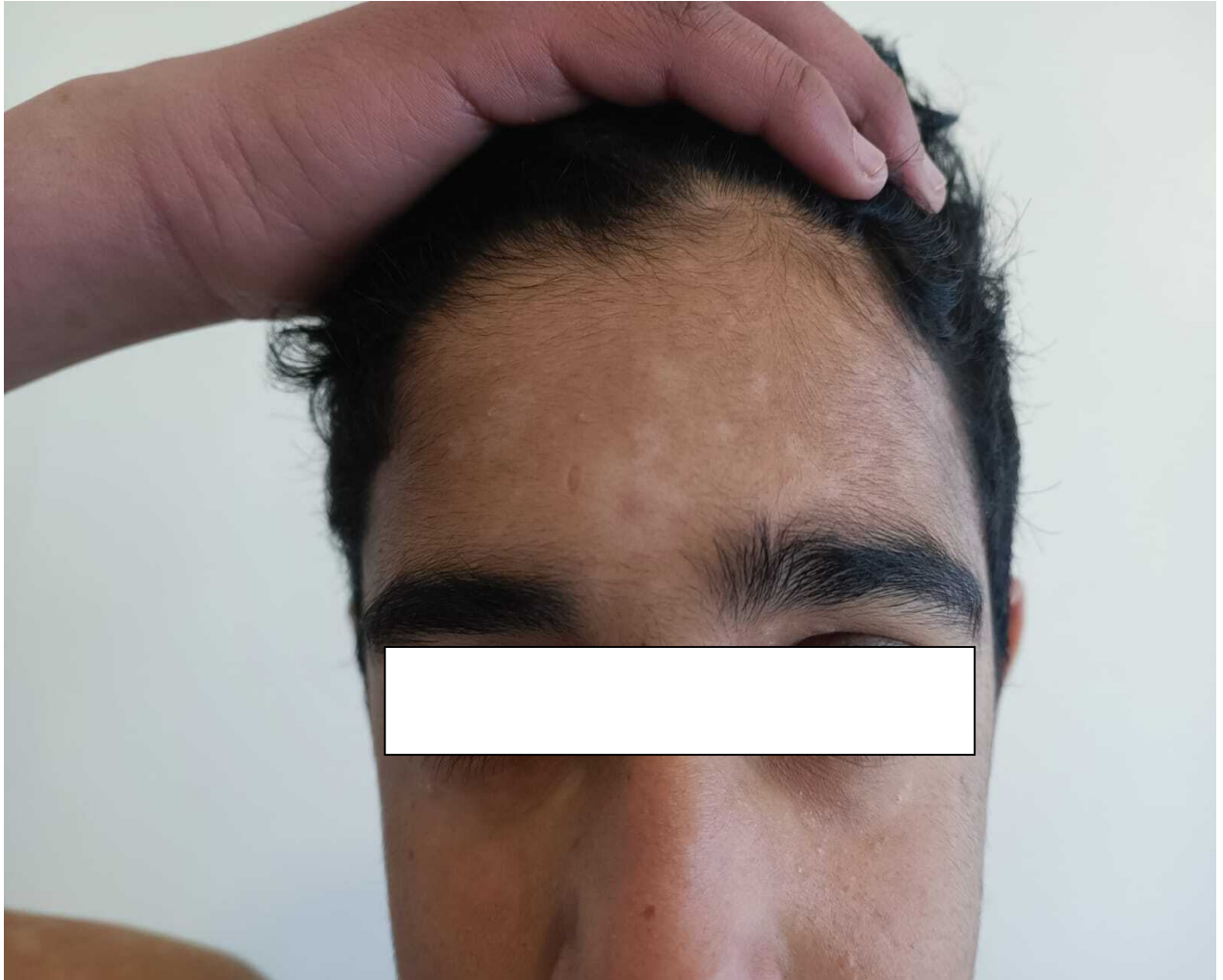

Figure 1: hypochromic macular lesions, very finely scaly, and non-pruritic, located essentially at the face

UNDER

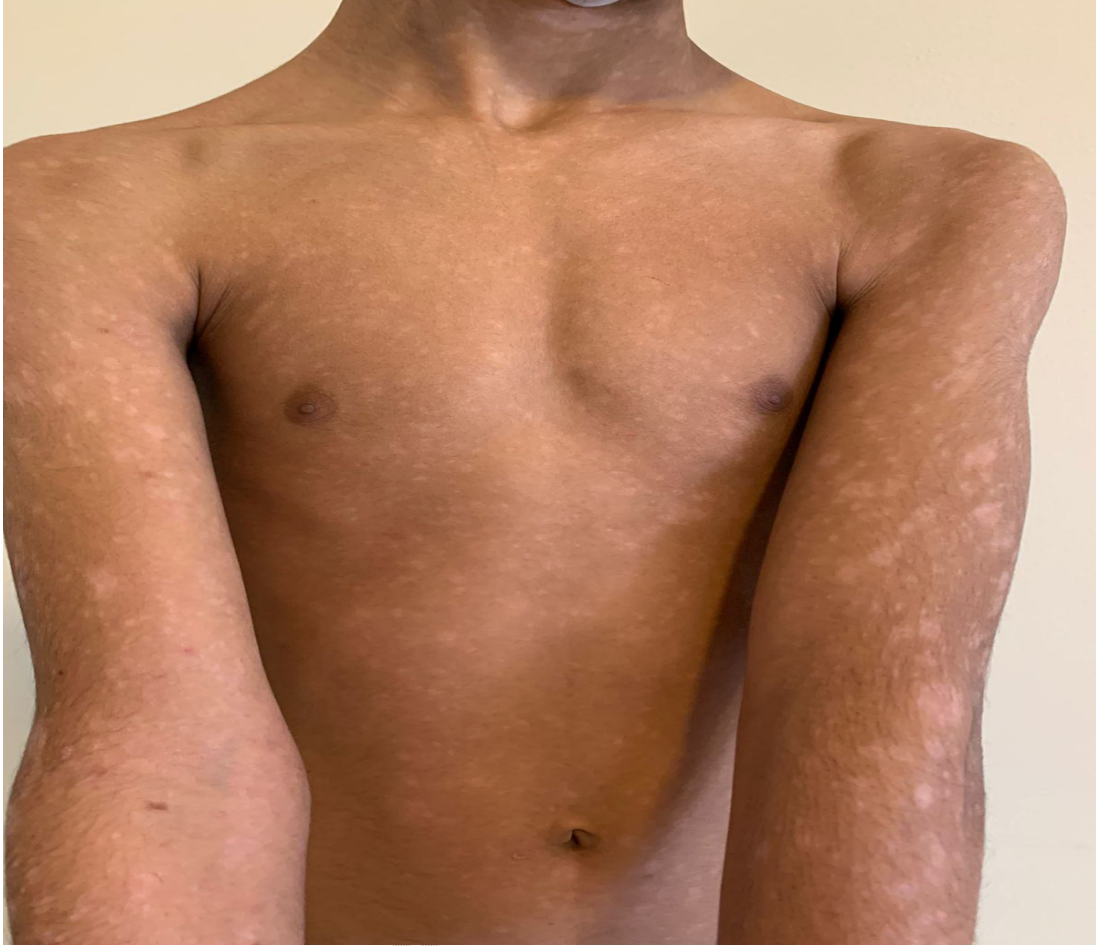

Figure 2: extension of the macular lesions at the trunk and the limbs

UNDER

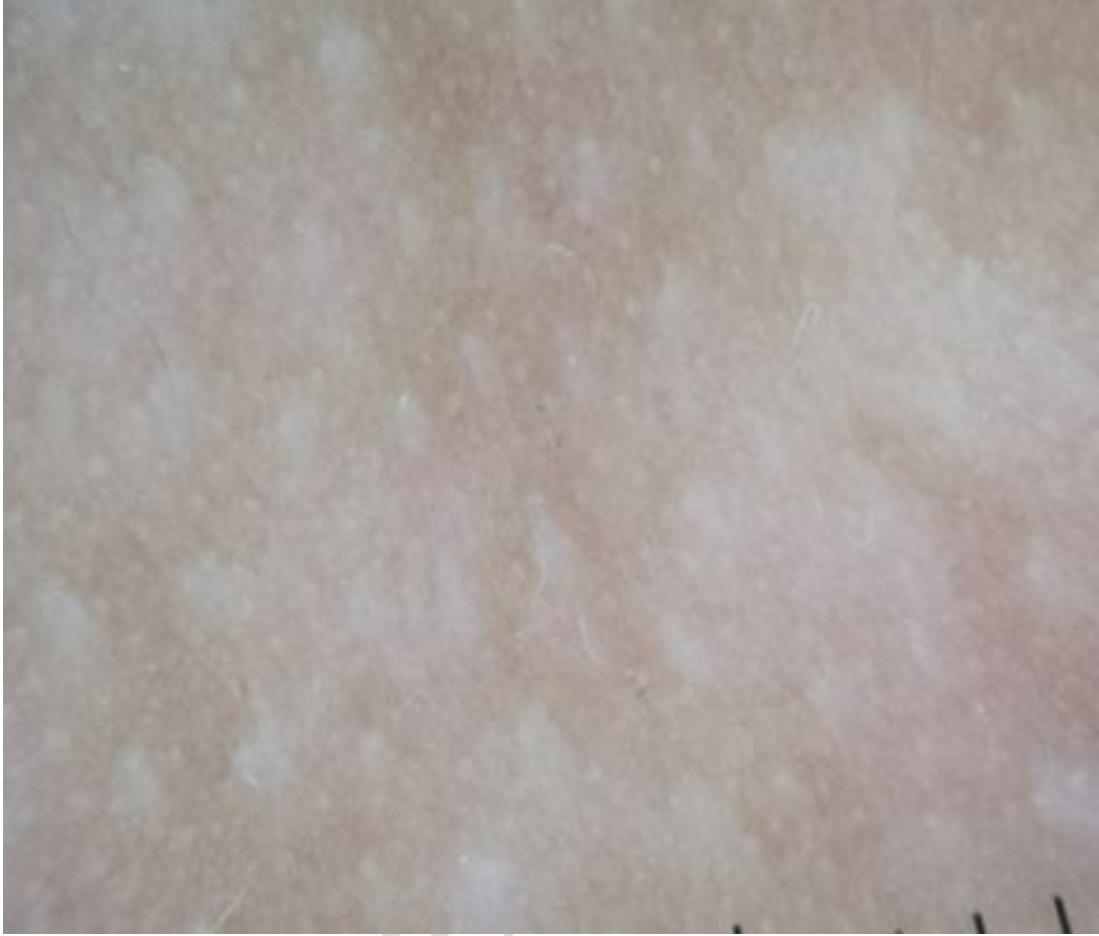

Figure 3: dermoscopy showed hypopigmented areas poorly limited without any particular pattern

UNDER

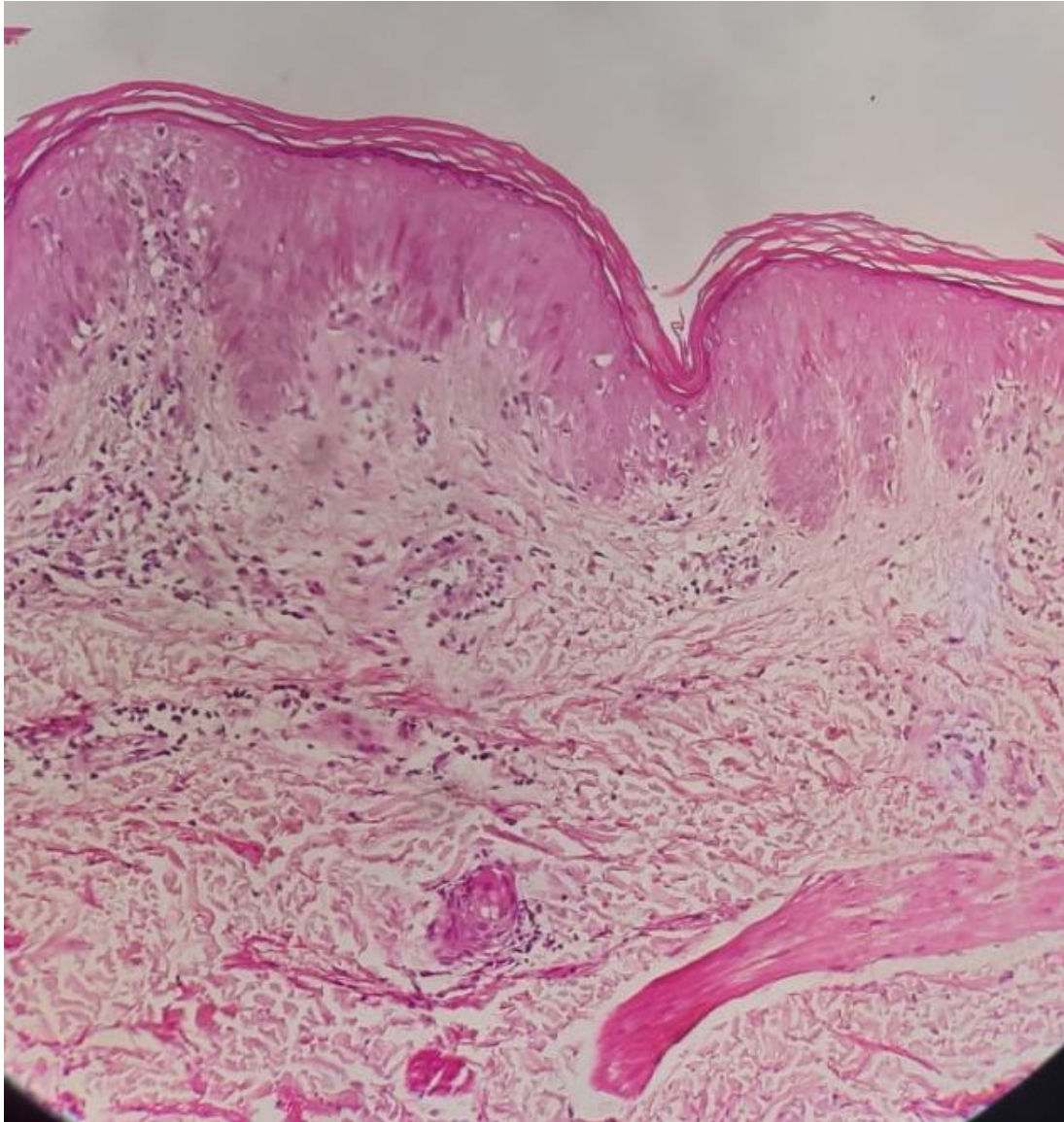


Figure 4: lymphoid infiltrate made up mainly of CD 4 and CD 30 were negative t lymphocytes