

# Facial Pyoderma Gangrenosum in Pediatrics: A Clinical Overview and Case Study

---

## ABSTRACT

A 12-year-old girl presented with three ulcerated lesions involving the face, which were erythematous, swollen, undermined, and had advancing borders. Culture of the ulcers showed no growth of organisms, and treatment with empiric intravenous and topical antibiotics showed no improvement. The biological workup was normal, and no systemic disease was found in the patient. A skin biopsy showed a neutrophilic dermatitis. The patient was started on oral prednisone, which allowed the lesions to heal. The skin biopsy and positive response to corticosteroids confirmed the diagnosis of Pyoderma Gangrenosum (PG). PG is a rare inflammatory skin condition that rarely presents as lesions on the face. Early initiation of immunosuppressive therapy facilitates complete healing and improves the significant psychological impact

*Keywords: Face, Pediatric, Pyoderma gangrenosum.*

## 1. INTRODUCTION

Pyoderma gangrenosum (PG) is a primarily sterile inflammatory neutrophilic dermatosis that was first described by Brunsting et al. in 1930 (1). This dermatosis primarily affects adults and is characterized by its locoregional aggressiveness and chronic, recurrent course. PG is a rare cause of cutaneous ulceration in children, accounting for 4% of cases worldwide (2). Clinically, it is classified into five subtypes: peristomal, pustular, bullous, vegetative, or classic (ulcerative) (3,4). The lower extremities are the most common predilection site for PG. However, it can also occur on other areas of the body, including the trunk, upper extremities, head, and neck (5,6). Here, we report an atypical presentation of a PG of the face in a child

## 2. PRESENTATION OF THE CASE

A 12-year-old child, with no previous medical history, consulted for the spontaneous appearance of three painful ulcerating lesions on the face that had been evolving for 1 month. Despite treatment with antibiotics, there was no response. The child had no systemic, gastrointestinal, or arthritic symptoms.

The clinical examination revealed two ulcerations on both cheeks, one measuring 7x4 cm and the other 5x3 cm. The ulcerations were well-defined with soft, erythematous raised edges. The bottom of the ulcerations was fibrinous and topped with hemorrhagic crusts that bled on contact and were very painful. There was also an ulceration measuring 3x2 cm in the right temporal region with the same appearance. The rest of the examination was unremarkable. (Figure 1a,1b)

Acid-fast and periodic acid-Schiff staining were negative. Bacterial, fungal, and tuberculous cultures from the secretions, biopsy tissue, and blood were all negative. The patient's biological workup was normal and no systemic disease was found.

Histopathological examination of the edge of the ulcers showed an ulcerated epidermal coating with an underlying dermis containing a polymorphic inflammatory infiltrate rich in neutrophils. (Figure 2) There was no evidence of infection or malignancy, suggesting Pyoderma Gangrenosum.

The patient received 1 mg/kg/day of prednisone, tapered off every 2 weeks. The ulcer size reduced with cribriform atrophic scars, indicating significant improvement. Almost complete healing was achieved after 6 months (figure 3a,3b) and no new skin lesions appeared after 2 years of observation. The patient's good response to the therapy confirmed the diagnosis of PG

## 3. DISCUSSION

Pyoderma gangrenosum (PG) is an uncommon, neutrophilic inflammatory skin condition that classically presents as a painful nodule, plaque, or pustule that enlarges and breaks down to form a progressively enlarging ulcer with raised, undermined, violaceous borders and a surrounding zone of erythema. Healing PG lesions develop a cribriform appearance (7). PG is estimated to affect up to 10 cases per million people per year, and represents up to 3% of chronic leg ulcer cases, but may occur anywhere on the body. PG has been reported in people of all ages; most cases, however, present in the second to sixth decades of life, with a possible female predominance (8). Pediatric PG is easily overlooked and misdiagnosed due to its infrequent incidence and atypical involvement areas such as the head or face. The face is not the preferred location for Pyoderma Gangrenosum. In one of the largest case series of PG, only 7.8% occurred on the head or neck. The leg was the most frequent site of PG (77.7%), followed by the trunk (11.7%), and the upper extremities (8.7%) (9). Pereira and colleagues found that the most common patients had a single lesion (62.5%), while multiple (more than three) lesions occurred only in 16.7% of the cases (10). In a literature review of facial PG, few pediatric cases have been reported. Hilary Haimes and colleagues reported two pediatric cases of facial PG preceding the diagnosis of inflammatory bowel disease (11). A similar location was recently described by Chen J et al in a 3-year-old girl. This girl presented with recurrent multiple painful ulcerative lesions for 10 months. The ulcer on the forehead rapidly progressed and involved both cheeks and nose (12). Another article reported the case of a 3-year-old girl who developed PG on the left upper eyelid without prior trauma or associated pathologies (13). In our case, the diagnosis of PG was evoked after eliminating all differential diagnoses by the negative mycological and bacteriological examinations, the evocative histological aspect, and especially the good healing of the lesions under general corticotherapy. Prompt diagnosis and treatment are essential to avoid severe scarring that can affect aesthetic and mental health. Notably, systemic comorbidities, such as inflammatory bowel disease, occurred in approximately 50% of PG cases in children (12). Regardless of the absence of symptoms of systemic comorbidities in our patient, further long-term multidisciplinary follow-up is necessary.

#### 4. CONCLUSION

In summary, pediatric pyoderma gangrenosum can occur on any part of the body, including the face. A comprehensive evaluation is crucial in order to diagnose other potential causes and to assess any comorbidities related to the condition. Once the diagnosis is established, aggressive immunosuppression should be started to promote complete healing.

#### CONSENT (WHERE EVER APPLICABLE)

All authors declare that written informed consent was obtained from the patient (for publication of this case report and accompanying images). A copy of the written consent is available for review by the Editorial office/Chief Editor/Editorial Board members of this journal

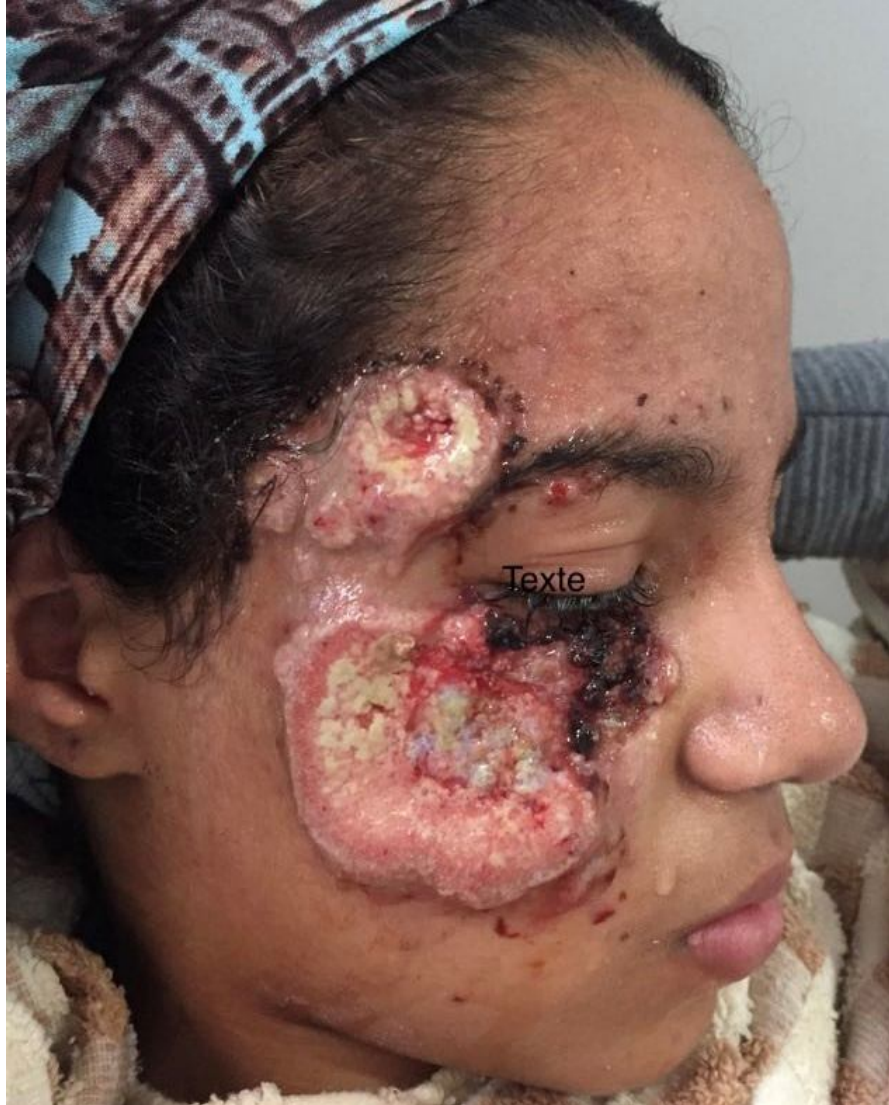#### ETHICAL APPROVAL

All authors hereby declare that all experiments have been examined and approved by the appropriate ethics committee and have therefore been performed in accordance with the ethical standards laid down in the 1964 Declaration of Helsinki

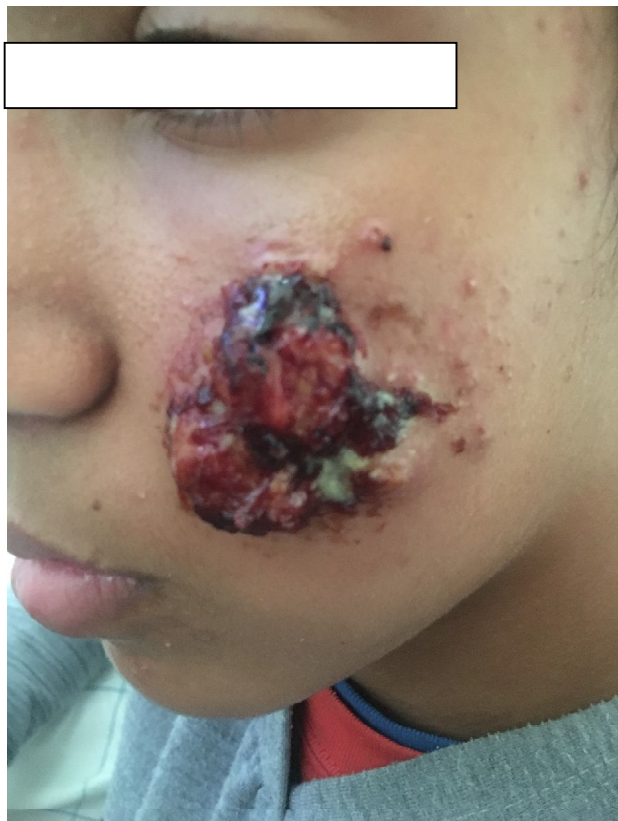#### REFERENCES

1. Brunsting LA, Goeckerman WH, O'Leary PA. Pyoderma (echthyma) gangrenosum: clinical and experimental observations in five cases occurring in adults. *Arch Derm Syphilol* 1930; 22: 655–680.
2. Kechichian E, Haber R, Mourad N, El Khoury R, Jabbour S, Tomb R. Pediatric pyoderma gangrenosum: a systematic review and update. *Int J Dermatol.* 2017;56(5):486-495.
3. Skopis M, Bag-Ozbek A. Pyoderma gangrenosum: a review of updates in diagnosis, pathophysiology, and management. *J Multidiscip Res.* 2021;4:367–375.
4. Alonso-Leon T, Hernández-Ramírez HH, Fonte-Avalos V, Toussaint- Caire S, Vega-Memije ME, Lozano-Platonoff A. The great imitator with no diagnostic test: pyoderma gangrenosum. *Int Wound J.* 2020;17:1774–1782.
5. Aziret M, Kara Ş, Yaldiz M, Köse N, Aşikuzunoğlu F, Cevrioğlu AS. An extensive pyoderma gangrenosum mimicking necrotizing fasciitis: an unusual case report. *Int J Surg Case Rep.* 2021;81:105697.
6. Saigal R, Singh Y, Mittal M, Kansal A, Maharia HR. Pyoderma gangrenosum. *J Assoc Physicians India.* 2010;58:378–383.
7. Korber A, Klode J, Al-Benna S, et al. Etiology of chronic leg ulcers in 31,619 patients in Germany analyzed by an expert survey. *J Dtsch Dermatol Ges.* 2011;9:116-121.
8. Natanel Jourabchi, Gerald S. Lazarus. Chapter 37 Pyoderma Gangrenosum - Fitzpatrick's Dermatology (2019).
9. Saigal R, Singh Y, Mittal M, Kansal A, Maharia HR. Pyoderma gangrenosum. *J Assoc Physicians India.* 2010;58:378–383.
10. Pereira N, Brites MM, Gonçalo M, Tellechea Ó, Figueiredo A. Pyoderma gangrenosum – a review of 24 cases observed over 10 years. *Int J Dermatol.* 2013;52(8):938–945.
11. Hilary haimes, Kristen Corey and al. Pediatric facial pyoderma gangrenosum preceding the diagnosis of inflammatory bowel disease. *pediatric dermatology.* DOI: 10.1111/pde.14186
12. Chen J, Wang H, Ren F. Arch Di . Dramatic case of paediatric pyoderma gangrenosum]. doi:10.1136/archdischild-2020-320598
13. Bromeo aJ, suller a. *BMJ Case Rep* 2019;12:e230645. doi:10.1136/bcr-2019-230645

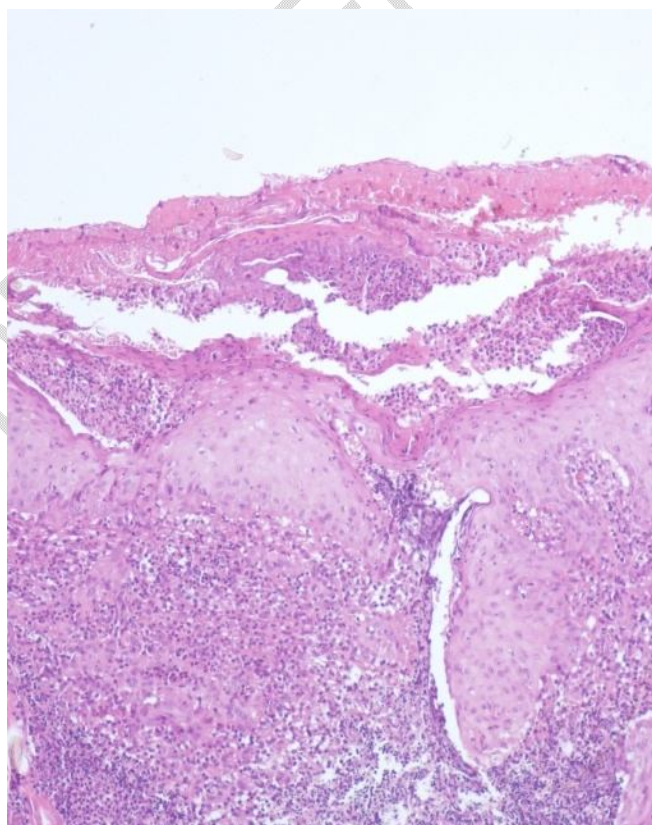
**FIGURE**



- Figure 1a: Two ulcerating-bourgeoning lesions of the right hemiface.



- Figure 1b: One ulcerating lesion on the left hemiface.



- Figure 2: Skin biopsy of the erythematous margins of the ulcer showing neutrophilic infiltration of the dermis (hematoxylin and eosin,  $\times 200$ ) .

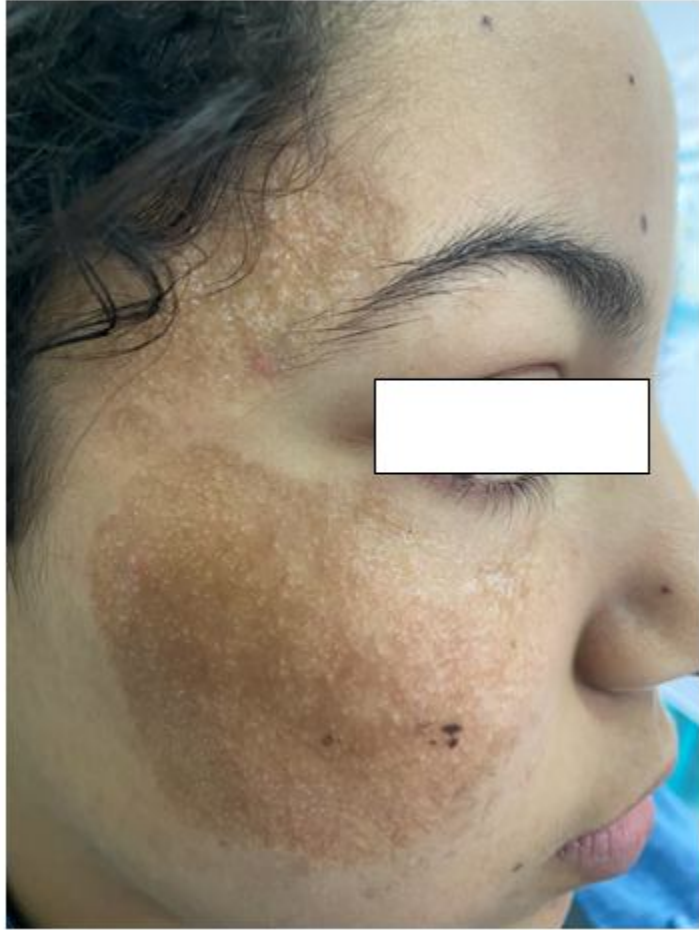
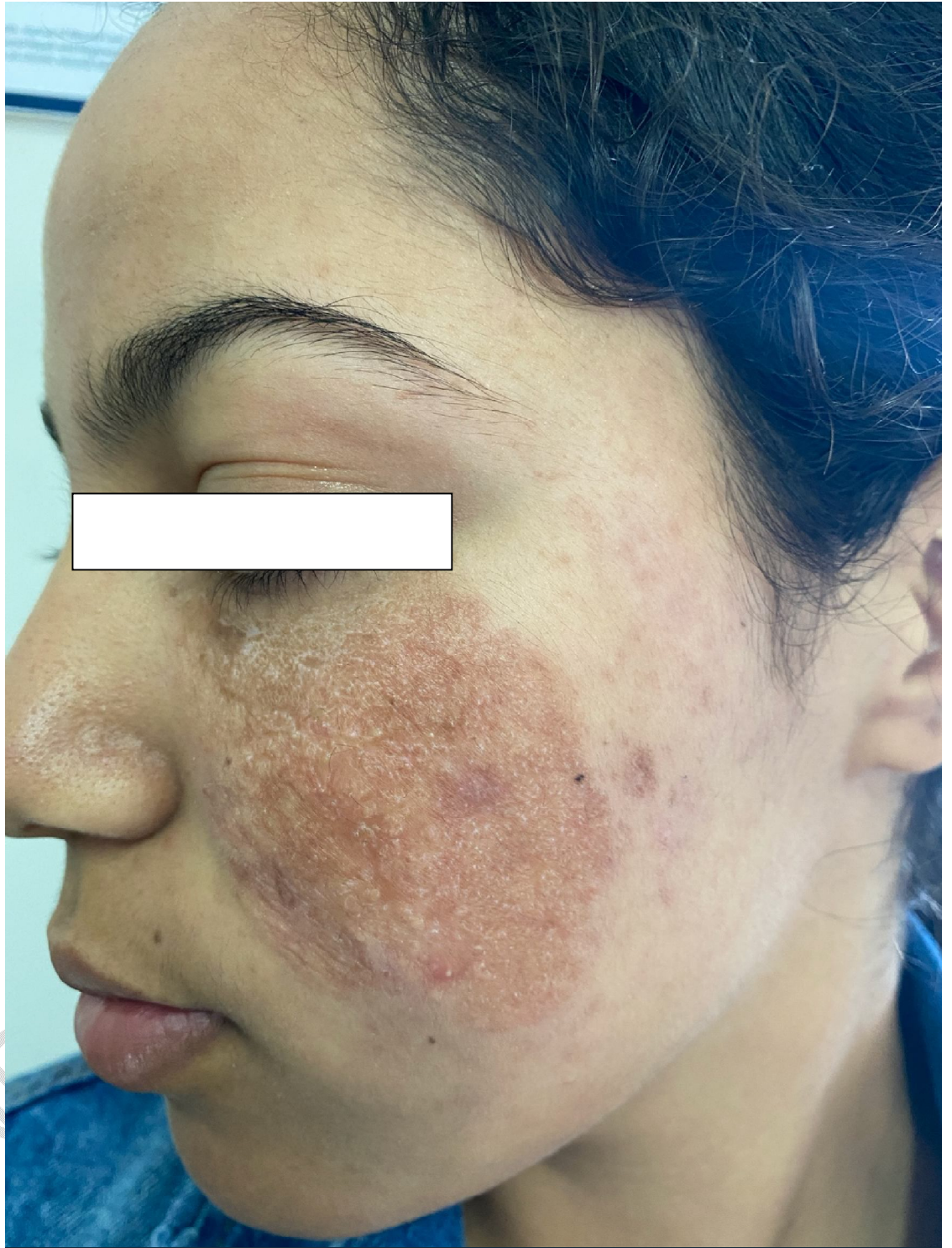
Figure 3a: Evolution of the lesions 6 months after the beginning of the treatment



- Figure 3b : Evolution of the lesions 6 months after the beginning of the treatment